

# Helsinki Microneurosurgery Basics and Tricks

Martin Lehecka, Aki Laakso  
and Juha Hernesniemi



Foreword by Robert F. Spetzler





# Helsinki Microneurosurgery Basics and Tricks

By Martin Lehecka, Aki Laakso and Juha Hernesniemi

**Collaborators:**

Özgür Çelik  
Reza Dashti  
Mansoor Foroughi  
Keisuke Ishii  
Ayse Karatas  
Johan Marjamaa  
Ondrej Navratil  
Mika Niemelä  
Tomi Niemi  
Jouke S. van Popta  
Tarja Randell  
Rossana Romani  
Ritva Salmenperä  
Rod Samuelson  
Felix Scholtes  
Päivi Tanskanen

**Photographs:**

Jan Bodnár  
Mansoor Foroughi  
Antti Huotarinen  
Aki Laakso

**Video editing:**

Jouke S. van Popta

**Drawings:**

Hu Shen

## **Helsinki Microneurosurgery Basics and Tricks**

By Martin Lehecka, Aki Laakso  
and Juha Hernesniemi

1. Edition 2011

© M. Lehecka, A. Laakso, J. Hernesniemi 2011

Layout: Aesculap AG | D-NE11002

Print: Druckerei Hohl GmbH & Co. KG / Germany

ISBN 978-952-92-9084-0 (hardback)

ISBN 978-952-92-9085-7 (PDF)

### **Author contact information:**

Martin Lehecka, MD, PhD

email: martin.lehecka@hus.fi

tel: +358-50-427 2500

Aki Laakso, MD, PhD

email: aki.laakso@hus.fi

tel: +358-50-427 2895

Juha Hernesniemi, MD, PhD

Professor and Chairman

email: juha.hernesniemi@hus.fi

tel: +358-50-427 0220

Department of Neurosurgery

Helsinki University Central Hospital

Topeliuksenkatu 5

00260 Helsinki, Finland

### **Disclosure statement:**

Helsinki Neurosurgery organizes annually

"The Helsinki Live Demonstration Course" in

Operative Microneurosurgery in collaboration

with Aesculap Academy. The authors have no

personal financial interests to disclose.

*Every man owes it as a debt to his profession to put on record whatever he has done that might be of use for others.*

Francis Bacon (1561-1626)

*Simple, clean, while preserving normal anatomy. Clean is fast and effective. Surgery is art - you should be one of the artists.*

Juha Hernesniemi

## **Acknowledgements**

*The authors would like to thank Aesculap, a B. Braun company, for kindly supporting printing of this book, with special thanks to Ingo vom Berg, Bianca Bauhammer and Outi Voipio-Airaksinen. In addition, the authors want to express their gratitude to the administration of Helsinki University Central Hospital for their support over the past years.*

## FOREWORD

by Robert F. Spetzler

Fortunate are the neurosurgeons who have the opportunity to visit the Department of Neurosurgery at the Helsinki University Central Hospital and receive this delightful volume as a souvenir for it is likely to be one of the most charming books they will ever read about neurosurgery. As the title indicates, Drs. Lehecka, Laakso, and Hernesniemi have written about neurosurgery as performed in Helsinki. However, they have done so much more than that — they have captured the deeply rooted spirit of camaraderie and commitment that has helped build Helsinki into an international center of neurosurgical excellence under the leadership of Juha Hernesniemi and his colleagues. Nor is the term international an overstatement when applied to a department in this far northern clime. Indeed, their list of distinguished visitors reads like an international Who's Who of Neurosurgery.

One can almost hear the Finnish cadences as the authors share amusing vignettes (although some were likely to have been alarming at the time of their occurrence) from the history of Finnish neurosurgery. More importantly, readers cannot miss the natural warmth, honesty, and integrity of these authors in their discussions of Helsinki philosophies, routines, and practices. These qualities are underscored by several essays contributed by a variety of trainees who each provide entertaining accounts of their time spent in Helsinki. That their lives were altered profoundly by the experience is unmistakable. Juha's taciturn but gentle humor, his intense devotion to perfecting his surgical expertise to better serve his patients, and his dedication to mentoring inspire a lifelong admiration and loyalty among his trainees and colleagues. Of course, readers will find considerable practical advice on the fundamental practice of neurosurgery in chapters devoted to principles of microneurosurgery, approaches,

specific strategies for treating various pathologies, and neuroanesthesiology.

Especially important points are summarized under the heading, T&T, that is, Tricks and Tips from Juha-Helsinki pearls. Seasoned surgeons will benefit from analyzing how their own surgical style differs from that of Juha's.

Every detail of the Helsinki approach to neurosurgery is covered, including how Juha expects his operating room to run to lists of his personal habits and instruments intended to ensure that his coworkers understand how his operations will proceed. The advantages to patients of such a finely tuned team, sensitive to the surgeon's needs and expectation, should never be underestimated. This refined teamwork ensures that neurosurgical procedures are completed in as efficient and safe manner as is possible, thereby optimizing the chances of a good outcome for the patient. Juha's ability to promote such precision teamwork is but one of his amazing talents.

Juha is truly a master neurosurgeon and to be able to experience his passion for, insight into, and dedication to neurosurgery is a rare privilege. His philosophy of simple, clean, and fast surgery that preserves normal anatomy is one that we all should emulate. By sharing both his expertise and his humanity in this volume, Juha lights a Socratic path worth following, a path based on respect and tolerance for different approaches that encourages growth while still respecting proven expertise. Those fortunate enough to visit Helsinki experience these rare qualities firsthand; those unable to make that pilgrimage can still count themselves lucky to read this volume.

*Robert F. Spetzler, MD*

*Phoenix, Arizona; November 2010*

# TABLE OF CONTENTS

<b>1. INTRODUCTION</b>	<b>13</b>	<b>3.8. POSTOPERATIVE CARE IN THE ICU</b>	<b>63</b>
<b>2. DEPARTMENT OF NEUROSURGERY, HELSINKI UNIVERSITY CENTRAL HOSPITAL</b>	<b>17</b>	<b>3.9. SPECIAL SITUATIONS</b>	<b>65</b>
2.1. HISTORY OF NEUROSURGERY IN HELSINKI AND FINLAND	17	3.9.1. Temporary clipping in aneurysm surgery	65
2.1.1. Aarno Snellman, founder of Finnish neurosurgery	17	3.9.2. Adenosine and short cardiac arrest	66
2.1.2. Angiography in Finland	18	3.9.3. Intraoperative neurophysiologic monitoring	66
2.1.3. World War II and late 1940's	19	3.9.4. Antithrombotic drugs and thromboembolism	67
2.1.4. Microneurosurgery and endovascular surgery	20	<b>4. PRINCIPLES OF HELSINKI MICRONEUROSURGERY</b>	<b>69</b>
2.1.5. Changes towards the present time	21	4.1. GENERAL PHILOSOPHY	69
2.2. PRESENT DEPARTMENT SETUP	24	4.2. PRINCIPLES OF MICRONEUROSURGERY	70
2.3. STAFF MEMBERS	24	4.3. OPERATING ROOM SETUP	71
2.3.1. Neurosurgeons	25	4.3.1. Technical setup	71
2.3.2. Neurosurgical residents	30	4.3.2. Displays	72
2.3.3. Neuroanesthesiologists	30	4.4. POSITIONING AND HEAD FIXATION	73
2.3.4. Neuroradiologists	31	4.4.1. Operating table	73
2.3.5. Bed wards	32	4.4.2. Patient positioning	73
2.3.6. Intensive care unit (ICU)	34	4.4.3. Neurosurgeon's position and movement	74
2.3.7. Operating rooms	36	4.4.4. Head fixation	76
2.3.8. Administrative personnel	37	4.5. NECESSARY OR USEFUL TOOLS	77
2.4. OPERATING ROOM COMPLEX	40	4.5.1. Operating microscope	77
2.4.1. Operating room complex design	40	4.5.2. Armrest	79
2.4.2. Operating room ambience	41	4.5.3. Bipolar and diathermia	79
<b>3. ANESTHESIA</b>	<b>45</b>	4.5.4. High speed drill	80
3.1. GENERAL PHYSIOLOGICAL PRINCIPLES AND THEIR IMPACT ON ANESTHESIA	46	4.5.5. Ultrasonic aspirator	82
3.1.1. Intracranial pressure	46	4.5.6. Fibrin glue	83
3.1.2. Autoregulation of cerebral blood flow	47	4.5.7. Indocyanine green angiography	84
3.1.3. CO <sub>2</sub> reactivity	48	4.5.8. Microsurgical doppler and flowmeter	85
3.1.4. Cerebral metabolic coupling	49	4.5.9. Neuronavigator	86
3.2. MONITORING OF ANESTHESIA	50	4.5.10. Intraoperative DSA	87
3.3. PREOPERATIVE ASSESSMENT AND INDUCTION OF ANESTHESIA	51	4.6. MICROINSTRUMENTS	88
3.4. MAINTENANCE OF ANESTHESIA	53	4.7. SOME HABITS IN PREPARATION AND DRAPING	90
3.5. TERMINATION OF ANESTHESIA	55	4.8. GENERAL PRINCIPLES OF CRANIOTOMY	92
3.6. FLUID MANAGEMENT AND BLOOD TRANSFUSIONS	56	4.9. BASIC MICROSURGICAL PRINCIPLES OF HELSINKI STYLE MICRONEUROSURGERY	94
3.7. ANESTHESIOLOGICAL CONSIDERATIONS FOR PATIENT POSITIONING	57	4.9.1. Simple, clean, fast and preserving normal anatomy	94
3.7.1. Supine position	57	4.9.2. Movements under the microscope	95
3.7.2. Prone, lateral park bench and kneeling positions	58	4.9.3. Moving the microscope	98
3.7.3. Sitting position	62	4.9.4. Left hand – suction	99
		4.9.5. Right hand	100
		4.9.6. Bipolar forceps	101
		4.9.7. Microscissors	102
		4.9.8. Cottonoids	102
		4.9.9. Sharp and blunt dissection	103
		4.9.10. Irrigation and water dissection	103
		4.9.11. Minimal retraction	104



4.10. CLOSING	104	<b>6. SPECIFIC TECHNIQUES AND STRATEGIES FOR DIFFERENT PATHOLOGIES</b>	<b>195</b>
4.11. KEY FACTORS IN HELSINKI STYLE MICRONEUROSURGERY	105	6.1. ANEURYSMS	195
4.12. LIST OF PROF. HERNESNIEMI'S GENERAL HABITS AND INSTRUMENTS	106	6.1.1. Approaches for different aneurysms	195
<b>5. COMMON APPROACHES</b>	<b>111</b>	6.1.2. General strategy for ruptured aneurysms	196
5.1. LATERAL SUPRAORBITAL APPROACH	111	6.1.3. General strategy for unruptured aneurysms	197
5.1.1. Indications	111	6.1.4. Release of CSF and removal of ICH	197
5.1.2. Positioning	112	6.1.5. Dissection towards the aneurysm	199
5.1.3. Incision and craniotomy	113	6.1.6. Opening of the Sylvian fissure	200
5.2. PTERIONAL APPROACH	118	6.1.7. Temporary clipping	201
5.2.1. Indications	118	6.1.8. Final clipping and clip selection	203
5.2.2. Positioning	119	6.1.9. Intraoperative rupture	203
5.2.3. Incision and craniotomy	119	6.1.10. Adenosine	206
5.3. INTERHEMISPHERIC APPROACH	124	6.2. ARTERIOVENOUS MALFORMATIONS	207
5.3.1. Indications	124	6.2.1. General strategy in AVM surgery	207
5.3.2. Positioning	125	6.2.2. Preoperative embolization	207
5.3.3. Incision and craniotomy	125	6.2.3. Approaches	208
5.4. SUBTEMPORAL APPROACH	132	6.2.4. Dural opening and initial dissection	208
5.4.1. Indications	132	6.2.5. Further dissection and use of temporary clips	210
5.4.2. Positioning	133	6.2.6. Coagulation and dissection of small feeders	211
5.4.3. Skin incision and craniotomy	135	6.2.7. Final stage of AVM removal	212
5.5. RETROSIGMOID APPROACH	144	6.2.8. Final hemostasis	212
5.5.1. Indications	145	6.2.9. Postoperative care and imaging	212
5.5.2. Positioning	146	6.3. CAVERNOMAS	214
5.5.3. Skin incision and craniotomy	149	6.3.1. General strategy in cavernoma surgery	214
5.6. LATERAL APPROACH TO FORAMEN MAGNUM	156	6.3.2. Intraoperative localization	214
5.6.1. Indications	156	6.3.3. Approaches	215
5.6.2. Positioning	156	6.3.4. Dissection and removal	216
5.6.3. Skin incision and craniotomy	157	6.3.5. Postoperative imaging	217
5.7. PRESIGMOID APPROACH	160	6.4. MENINGIOMAS	218
5.7.1. Indications	160	6.4.1. General strategy with convexity meningiomas	218
5.7.2. Positioning	162	6.4.2. General strategy with parasagittal meningiomas	219
5.7.3. Skin incision and craniotomy	162	6.4.3. General strategy with falx and tentorium meningiomas	221
5.8. SITTING POSITION – SUPRACEREBELLAR INFRATENTORIAL APPROACH	170	6.4.4. General strategy with skull base meningiomas	222
5.8.1. Indications	171	6.4.5. Tumor consistency	224
5.8.2. Positioning	173	6.4.6. Approaches	224
5.8.3. Skin incision and craniotomy	177	6.4.7. Devascularization	225
5.9. SITTING POSITION – APPROACH TO THE FOURTH VENTRICLE AND FORAMEN MAGNUM REGION	183	6.4.8. Tumor removal	225
5.9.1. Indications	183	6.4.9. Dural repair	226
5.9.2. Positioning	183	6.5. GLIOMAS	227
5.9.3. Skin incision and craniotomy	183	6.5.1. General strategy with low-grade gliomas	227
		6.5.2. General strategy with high-grade gliomas	228
		6.5.3. Approaches	229

# TABLE OF CONTENTS

6.5.4. Intracranial orientation and delineation of the tumor	229	7.7. PUBLICATION ACTIVITY	260
6.5.5. Tumor removal	230	7.8. RESEARCH GROUPS AT HELSINKI NEUROSURGERY	261
6.6. COLLOID CYSTS OF THE THIRD VENTRICLE	231	7.8.1. Biomedicum group for research on cerebral aneurysm wall	261
6.6.1. General strategy with colloid cyst surgery	231	7.8.2. Translational functional neurosurgery group	262
6.6.2. Positioning and craniotomy	231	7.8.3. Helsinki Cerebral Aneurysm Research (HeCARE) group	262
6.6.3. Interhemispheric approach and callosal incision	232	<b>8. VISITING HELSINKI NEUROSURGERY</b>	<b>265</b>
6.6.4. Colloid cyst removal	233	8.1. TWO YEAR FELLOWSHIP –	
6.7. PINEAL REGION LESIONS	234	JOUKE S. VAN POPTA (ZARAGOZA, SPAIN)	265
6.7.1. General strategy with pineal region surgery	234	8.1.1. Why to do a fellowship?	265
6.7.2. Approach and craniotomy	235	8.1.2. In search of a fellowship	266
6.7.3. Intradural approach	235	8.1.3. Checking it out	266
6.7.4. Lesion removal	235	8.1.4. Arrival in Helsinki	266
6.8. TUMORS OF THE FOURTH VENTRICLE	236	8.1.5. The very first day	266
6.8.1. General strategy with fourth ventricle tumors	236	8.1.6. A day in the life (of a fellow)	267
6.8.2. Positioning and craniotomy	237	8.1.7. Assisting in surgery	267
6.8.3. Intradural dissection towards the fourth ventricle	237	8.1.8. Nurses	268
6.8.4. Tumor removal	238	8.1.9. Anesthesiologists	268
6.9. SPINAL INTRADURAL TUMORS	240	8.1.10. Music in the OR	269
6.9.1. General strategy with intradural spinal lesions	240	8.1.11. Rounds	269
6.9.2. Positioning	241	8.1.12. Visitors	271
6.9.3. Approach	242	8.1.13. Pins and their stories	271
6.9.4. Intradural dissection	243	8.1.14. LINNC and Live Course	271
6.9.5. Closure	243	8.1.15. Weather and the four seasons	272
<b>7. NEUROSURGICAL TRAINING, EDUCATION AND RESEARCH IN HELSINKI</b>	<b>245</b>	8.1.16. Apartments	273
7.1. NEUROSURGICAL RESIDENCY IN HELSINKI	245	8.1.17. Helsinki	273
7.1.1. Residency program	245	8.1.18. Finnish food	273
7.1.2. How to become a neurosurgeon in Helsinki – the resident years – Aki Laakso	246	8.1.19. Languages	273
7.2. ACADEMIC AND RESEARCH TRAINING	250	8.1.20. Famous words	274
7.2.1. PhD program	250	8.1.21. Practice, practice, practice	274
7.2.2. Making of a PhD thesis in Helsinki, my experience – Johan Marjamaa	250	8.1.22. Video editing	274
7.3. MICRONEUROSURGICAL FELLOWSHIP WITH PROFESSOR HERNESNIEMI	253	8.1.23. The surgery of Juha Hernesniemi	274
7.4. MEDICAL STUDENTS	254	8.1.24. The choice of a fellowship	275
7.5. INTERNATIONAL VISITORS	254	8.2. ADAPTING TO FINNISH CULTURE AND SOCIETY – ROSSANA ROMANI (ROME, ITALY)	276
7.6. INTERNATIONAL LIVE SURGERY COURSES	256	8.2.1. The difference between "to talk the talk" and "to walk the walk"	276
7.6.1. Helsinki Live Course	256	8.2.2. Difficult to learn but good for life: The Finnish language	274
7.6.2. LINNC-ACINR course (Organized by J. Moret and C. Islak)	258	8.2.3. When in Finland do as the Finns	280
		8.2.4. Never good weather	281
		8.2.5. Finnish attitude: "Sisu"	283
		8.2.6. He and she = hän	283
		8.2.7. Conclusions	283
		8.3. IMPRESSIONS OF HELSINKI: ACCOUNT OF A VISIT – FELIX SCHOLTES (LIÈGE, BELGIUM)	284
		8.4. TWO YEARS OF FELLOWSHIP AT THE DEPARTMENT OF NEUROSURGERY IN HELSINKI – REZA DASHTI (ISTANBUL, TURKEY)	290

8.5. MY MEMORIAL OF "GO GO SURGERY" IN HELSINKI - KEISUKE ISHII (OITA, JAPAN)	294	11. FUTURE OF NEUROSURGERY	333
8.5.1. The first impression of Finns	294	APPENDIX 1. PUBLISHED ARTICLES ON MICRO-NEUROSURGICAL AND NEUROANESTHESIOLOGICAL TECHNIQUES FROM HELSINKI	337
8.5.2. The Helsinki University Central Hospital	294	APPENDIX 2. LIST OF ACCOMPANYING VIDEOS	342
8.5.3. Professor Hernesniemi and his surgical techniques	294		
8.5.4. My current days in Japan	295		
8.5.5. To conclude	295		
8.6. AFTER A ONE-YEAR FELLOWSHIP – ONDREJ NAVRATIL (BRNO, CZECH REPUBLIC)	296		
8.7. ONE-YEAR FELLOWSHIP AT THE DEPARTMENT OF NEUROSURGERY IN HELSINKI – ÖZGÜR ÇELİK (ANKARA, TURKEY)	300		
8.8. SIX MONTH FELLOWSHIP – MANSOOR FOROUGHİ (CARDIFF, UNITED KINGDOM)	302		
8.8.1 How it began	302		
8.8.2. The place and the people	303		
8.8.3. The Rainbow team and its Chairman	304		
8.9. TWO MONTH FELLOWSHIP – ROD SAMUELSON (RICHMOND, VIRGINIA)	308		
8.10. MEMORIES OF HELSINKI – AYSE KARATAS (ANKARA, TURKEY)	312		
<b>9. SOME CAREER ADVICE TO YOUNG NEUROSURGEONS</b>	<b>315</b>		
9.1. READ AND LEARN ANATOMY	316		
9.2. TRAIN YOUR SKILLS	316		
9.3. SELECT YOUR OWN HEROES	316		
9.4. KEEP FIT	317		
9.5. BE A MEDICAL DOCTOR, TAKE RESPONSIBILITY!	318		
9.6. LEARN YOUR BEST WAY OF DOING YOUR SURGERY	318		
9.7. OPEN DOOR MICROSURGERY	319		
9.8. RESEARCH AND KEEP RECORDS	319		
9.9. FOLLOW UP YOUR PATIENTS	320		
9.10. WRITE AND PUBLISH	320		
9.11. KNOW YOUR PEOPLE	321		
9.12. ATMOSPHERE	321		
<b>10. LIFE IN NEUROSURGERY: HOW I BECAME ME – JUHA HERNESNIEMI</b>	<b>333</b>		



## 1. INTRODUCTION

*Such a complex labyrinthine approach through the cranium and brain, however, requires accurate preoperative planning and the preparation of a prospective surgical concept (including anticipated variations), which is based on a firm knowledge of anatomy, microtechniques, and surgical experience. These elements constitute the art of microneurosurgery.*

*M.G. Yaşargil 1996 (Microneurosurgery vol IVB)*

*Much of the merit of an approach is a matter of surgical experience. We always attempted to make these operations simpler, faster and to preserve normal anatomy by avoiding resection of cranial base, brain or sacrifice of veins.*

*C.G. Drake, S.J. Peerless, and J. Hernesniemi 1996*

Sometimes I look into the small craniotomy approach without the help of a microscope, and think of the neurosurgical pioneers, Olivecrona from Stockholm and his pupils here in Helsinki, Snellman and af Björkesten. I was never trained by them, they came before my time, but I received my neurosurgical training already at the hands of their pupils. I also think of Professor C.G. Drake, what might have been his feelings when approaching the basilar tip for the first time. Personally, I am terrified of this tiny deep gap, the lack of light, the fear of all the things that might lie in there, of all the things that cannot be seen with the bare eye. But at the same time, I also feel happiness because of all the different tools and techniques we nowadays have. Tools that have changed our whole perception of neurosurgery from something scary into something extremely delicate. Microneurosurgical techniques, mainly introduced by Professor Yaşargil, have revolutionized our possibilities to operate in a small and often very deep gap in total control of the situation and without the fear of the unknown. I still feel fear before every surgery, but it is no longer the fear of the unknown; rather, it is a fear of whether I will be successful in executing the

pre-planned strategy with all its tiny details and possible surprises along the way. But all this anxiety subsides immediately once the fascinating and beautiful microanatomical world opens up under the magnification of the operating microscope. This loss of fear means better surgery, as hesitance and tremor associated with fear are replaced with a strong feeling of success, determination and steady hands. The fear is also in an equal way lost to a minimum when looking around and seeing the experienced and supporting Helsinki team around, and exchanging few words with them before and during surgery. As Bertol Brecht said, Finnish people are quiet in two languages.

Big resistance against microsurgery was still seen at the end of 70's when I was trained in Helsinki. The reluctance towards new thinking, although often irrational, is very common both in surgical as well as other human areas. Arguments such as "the really good neurosurgeons can operate on aneurysms without a microscope..." were common at that time. Fortunately, this kind of thinking has already disappeared among Finnish neurosurgeons, but the same thoughts still prevail in many parts of the world. In many countries unskilled neurosurgeons with old-fashioned thinking still continue cruel surgery, and bring misery to the patients, families and the surrounding society. The motto "do not harm" is forgotten. It is clear that an epidural hematoma can be removed without a microscope, but already removing a big convexity meningioma using microneurosurgical techniques helps in getting far better results.

Microneurosurgery does not solely refer to the use of the operating microscope; rather, it is a conceptual way of planning and executing all stages of the operation utilizing the delicate techniques of handling the different tissues. A true microsurgical operation starts already out-

side of the operating room with careful preoperative planning and continues throughout all the steps of the procedure. Mental preparation, repetition of earlier experience, good knowledge of microanatomy, high quality neuroanesthesia, seamless cooperation between the neurosurgeon and the scrub nurse, appropriate strategy and its execution are all essential elements of modern microneurosurgery.

In this book we want to share our experience from Helsinki on some of the conceptual thinking behind what we consider modern microneurosurgery. We want to present an up-to-date manual of basic microneurosurgical principles and techniques in a cookbook fashion. It is my experience, that usually the small details determine whether the procedure is going to be successful or not. To operate in a simple, clean, and fast way while preserving normal anatomy; that has become my principle during and after more than 12,000 microsurgical operations.

*Juha Hernesniemi*

*Helsinki, August 15th 2010*



HYKS  
HUCS

Töölön sairaala Töölö sjukhus



## 2. DEPARTMENT OF NEUROSURGERY, HELSINKI UNIVERSITY CENTRAL HOSPITAL

### 2.1. HISTORY OF NEUROSURGERY IN HELSINKI AND FINLAND

#### 2.1.1. Aarno Snellman, founder of Finnish neurosurgery

The first neurosurgical operations in Finland were performed in the beginning of the 20th century by surgeons such as Schultén, Krogius, Faltin, Palmén, Kalima and Seiro, but it is Aarno Snellman who is considered the founder of neurosurgery in Finland. The Finnish Red Cross Hospital, which was the only center for Finnish neurosurgery until 1967, was founded in 1932 by Marshall Mannerheim and his sister Sophie Mannerheim as a trauma hospital. It is in this same hospital where the Helsinki Neurosurgery is still nowadays located. Already during the first years the number of patients with different head injuries was so significant that an evident need for a trained neurosurgeon and special nursing staff arose. In 1935, professor of surgery Simo A. Brofeldt sent his younger colleague, 42-year old Aarno Snellman, to visit professor Olivecrona in Stockholm. Snellman spent there half a year, closely observing Olivecrona's work. Upon his return, he performed the first neurosurgical operation on 18th September 1935. This is generally considered as the true beginning of neurosurgery in Finland.



*Figure 2-1. The Finnish Red Cross Hospital (later Töölö Hospital) in 1932.*

### 2.1.2. Angiography in Finland

The initially relatively poor surgical results were mainly due to insufficient preoperative diagnostics. Realizing the importance of preoperative imaging, Snellman convinced his colleague from radiology, Yrjö Lassila, to visit professor Erik Lysholm in Stockholm. The first cerebral angiographies were performed after Lassila's return to Helsinki in 1936. At that time the angiography was often performed only on one side as it required surgical exposure of the carotid artery at the neck and four to six staff members to perform the procedure that took a relatively long time: one to hold the needle, one to inject the contrast agent, one to use the X-ray tube, one to change the films, one to hold the patient's head, and one who was responsible for the lighting. The procedure was quite risky for the patients; there was one death in the first 44 cases, i.e. 2% mortality. There were

also some less expected complications such as one situation, when the surgeon injecting the contrast agent got an electric shock from the X-ray tube and fell unconscious to the floor! While falling he accidentally pulled on the loop of silk thread, passed under the patient's carotid artery, causing total transection of this artery. Fortunately, the assistant was able to save the situation and as Snellman stated in his report, "no one was left with any permanent consequences from this dramatic situation". Before 1948 the number of cerebral angiographies was only 15-20 per year, but with the introduction of the percutaneous technique at the end of 1948, the number of angiographies started gradually to rise, with more than 170 cerebral angiographies performed in 1949.



Figure 2-2. (a) Professor Aarno Snellman (painting by Tuomas von Boehm in 1953).




Figure 2-2. (b) Professor Sune Gunnar af Björkesten (painting by Pentti Melanen in 1972).

### 2.1.3. World War II and late 1940's

The World War II had a significant effect on the development of neurosurgery in Finland. On one hand the war effort diminished the possibilities to treat civilian population, on the other hand the high number of head injuries boosted the development of the neurosurgical treatment of head trauma. During this period several neurosurgeons from other Scandinavian countries worked as volunteers in Finland helping with the high casualty load. Among others there were Lars Leksell, Nils Lundberg and Olof Sjöqvist from Sweden, and Eduard Busch from Denmark. After the war, it became evident that neurosurgery was needed as a separate specialty. Aarno Snellman was appointed as a professor of neurosurgery at the Helsinki University in 1947 and the same year medical students had their first, planned course in neurosurgery. The next year, Teuvo Mäkelä, who worked in

neurosurgery since 1940 and took care of the head injury patients, was appointed as the first assistant professor in neurosurgery. An important administrative change took place in 1946 when the Finnish government decided that the state would pay for the expenses for the neurosurgical treatment. With this decision neurosurgical treatment became, at least in theory, available for the whole Finnish population. The limiting factors were hospital resources (there was initially only one ward available) and the relatively long distances in Finland. This is one of the reasons why especially in the early years, e.g. aneurysm patients came for operative treatment several months after the initial rupture, and only those in good condition were selected. Neurosurgery remained centralized in Helsinki until 1967, when the department of neurosurgery in Turku was founded, later followed by neurosurgical departments in Kuopio (1977), Oulu (1977) and Tampere (1983).

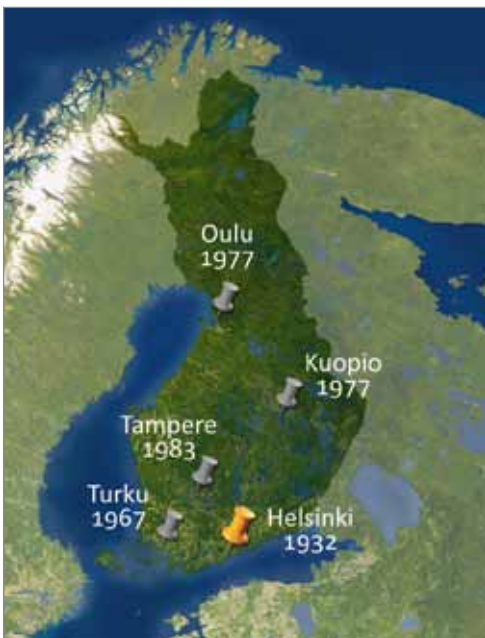

Figure 2-3. Neurosurgical units in Finland and the years they were established.

#### 2.1.4. Microneurosurgery and endovascular surgery

The first one to use the operating microscope in Finland was Tapio Törmä in Turku in the beginning of 1970's. The first operating microscope came to the neurosurgical department in Helsinki in 1974. The economic department of that time managed to postpone purchase of this microscope by one year as they considered it a very expensive and unnecessary piece of equipment. Initially, the microscope was used by neurosurgeons operating on aneurysms, small meningiomas, and acoustic schwannomas. Laboratory training in microsurgical techniques was not considered necessary and surgeons usually started to use them immediately in the operating room (OR). A Turkish born neurosurgeon Davut Tovi from Umeå held a laboratory course in Helsinki in January 1975, during which he also demonstrated the use of the microscope in the OR while the intraoperative scene could be observed from a TV monitor. Interestingly, during the first years of microneurosurgery on aneurysms, intraoperative rupture made the neurosurgeon often to abandon the microscope and move back to macrosurgery so that he could "see better" the rupture site. But the younger generation already started with microsurgical laboratory training, among them Juha Hernesniemi, who operated his first aneurysm in 1976. He has operated all of his nearly 4000 aneurysms under the microscope. In 1982 Hernesniemi visited Yaşargil in Zürich, and after this visit started, as the first in Finland in 1983, to use a counterbalanced microscope with a mouthswitch. Surgery on unruptured aneurysms in patients with previous SAH started in 1979, and the first paper on surgery of aneurysms in patients with only incidental, unruptured aneurysms was published in 1987. Endovascular treatment of intracranial aneurysms started in Finland in 1991.

### 2.1.5. Changes towards the present time

During the last decades of the 20th century, advances in the society, technology, neuroimaging, and medicine in general also meant an inevitable gradual progression in neurosurgery, which had its impact on Helsinki Neurosurgery as well. The annual number of operations increased from 600 in the 70's to about 1000 in the 80's and 1500 in the early 90's. In the intensive care unit (ICU), although the clinical neurological condition and the level of consciousness of the patients were closely monitored, no invasive monitoring was used in the early 1980's. Transferring a critically ill patient to a routine CT scan might have had catastrophic consequences. However, little by little, significant advances in neuroanesthesiology began to lead to safer and less tumultuous neurosurgical operations. Development in this field also had its impact on neurointensive care, and invasive monitoring of vital functions – both at the ICU and during transfer of critically ill or anesthetized patients – as well as e.g. intracranial pressure monitoring became routine. Treatment attitude in the ICU changed from 'maintaining' the patients while waiting for the illness and the physiological repair mechanisms to take their natural course, to an active one with strong emphasis on secondary injury prevention. Much of this development in Helsinki was due to the work of neuroanesthesiologists Tarja Randell, Juha Kyttä and Päivi Tanskanen, as well as Juha Öhman, the head of neurosurgical ICU (now the Professor and Chairman of the Department of Neurosurgery in Tampere University Hospital).

Still, many aspects of life and daily work at the Department in 1990's looked very different from the present state of affairs. The staff included only six senior neurosurgeons, three residents and 65 nurses. Three to four patients a day were operated in three OR's. Operations were long; in a routine craniotomy, in addition

to intracranial dissection and treatment of the pathology itself, just the approach usually took an hour, and the closure of the wound from one to two hours. With no technical staff to help, scrub nurses had to clean and maintain the instruments themselves at the end of the day, meaning that no elective operation could start in the afternoon. All surgeons operated sitting; unbalanced microscopes had no mouthpieces. Convexity meningiomas and glioblastomas were even operated on without a microscope. The attitude towards elderly and severely ill patients was very conservative compared with present day standards – for example, high-grade SAH patients were not admitted for neurosurgical treatment unless they started to show signs of recovery. International contacts and visitors from abroad were rare. The staff did participate in international meetings, but longer visits abroad and clinical fellowships took only seldom place. Scientific work was encouraged and many classical pearls of scientific literature were produced, such as Prof. Henry Troupp's studies of natural history of AVMs, Juha Jääskeläinen's (now Professor of Neurosurgery in Kuopio University Hospital) studies of outcome and recurrence rate of meningiomas, and Seppo Juvela's studies on the risk factors of SAH and hemorrhage risk of unruptured aneurysms. However, it was very difficult especially for younger colleagues to get proper financial support for their research at the time. Doing research was a lonely job – research groups, as we know them now, did not really exist at the Department, and the accumulation of papers and scientific merit was slow.

Probably no one anticipated the pace and extent of changes that were about to take place when the new chairman was elected in 1997. Juha Hernesniemi, a pupil of the Department from the 70's, having spent almost two decades elsewhere – mainly in Kuopio University Hospi-

tal – returned with intense will and dedication to shape the Department according to his vision and dream. In only three years, the annual number of operations increased from 1600 to 3200, the budget doubled from 10 to 20 million euros. It is a common fact in any trade, that the election of a new leader or a manager is followed by a "honeymoon" period, during which the new chief fiercely tries to implement changes according to his or her will, and to some extent the administration of the organization is supposed to support the aims of this newly elected person – he or she was given the leadership position by the same administration, after all. In this particular case, however, people in the administration got cold feet because of the volume and the speed of the development. Since the Department had the same population to treat as before, where did this increase in patient numbers come from? Were the treatment indications appropriate? Could the treatment results be appropriate? Soon, an internal audit was initialized, questioning the actions of the new chairman. The scrutiny continued for over a year. The treatment indications and results were compared to those of other neurosurgical units in Finland and elsewhere in Europe, and it became evident that the treatment and care given in the Department were of high quality. The new chairman and his active treatment policy also received invaluable support in form of Professor Markku Kaste, the highly distinguished chairman of Department of Neurology. After the rough ride through the early years, the hospital administration and the whole society started to appreciate the reformation and the high quality of work that still continues.

But what was the anatomy of this unprecedented change? Surely, one person alone, no matter how good and fast, cannot operate additional 1600 patients a year. The size of the staff has almost tripled since 1997 – today, the staff includes 16 senior neurosurgeons, six (nine trainees) residents, 154 nurses and three OR technicians, in addition to adminis-

trative personnel. The number of ICU beds has increased from six to 16. The number of OR's has increased only by one, but the operations start nowadays earlier, the patient changes are swift, and there is sufficient staff for longer workdays. The most significant change, however, was probably the general increase in the pace of the operations, mostly because of the example set by the new chairman, "the fastest neurosurgeon in the world". The previous rather conservative treatment policy was replaced by a very active attitude, and attempts to salvage also critically ill patients are being made, and often successfully. Chronological high age per se is no longer a "red flag" preventing admission to the Department, if the patient otherwise has potential for recovery and might benefit from neurosurgical intervention.

Despite the increased size of staff, the new efficient approach to doing things meant more intense and longer workdays. However, perhaps somewhat surprisingly, the general attitude among the staff towards these kind of changes was not only of resistance. The realization of the outstanding quality and efficiency of the work the whole team in the Department is doing, has also been the source of deep professional satisfaction and pride, both among the neurosurgeons and the nursing staff. An important role in the acceptance of all these changes played also the fact that Prof. Hernesniemi has always been intensely involved in the daily clinical work instead of hiding in the corridors of administrative offices. The price for all this has not been cheap, of course. The workload, effort and the hours spent to make all this happen have been, and continue to be, massive, and require immense dedication and ambition. What else has changed? For sure, much more attention is being paid to the microneurosurgical technique in all operations. Operations are faster and cleaner, the blood loss in a typical operation is minimal, and very little time is spent on wondering what to do next. Almost all operations are performed standing, and all the microscopes are equipped with mouthpiec-

es and video cameras to deliver the operative field view to everybody in the OR. Operative techniques are taught systematically, starting from the very basic principles, scrutinized and analyzed, and published for the global neurosurgical community to read and see. Postoperative imaging is performed routinely in all the patients, serving as quality control for our surgical work. The Department has become very international. There is a continuous flow of long- and short-term visitors and fellows, and the Department is involved in two international live neurosurgery courses every year. The staff travels themselves, both to meetings and to other neurosurgical units, to teach and to learn from others. The opponents of doctoral dissertations are among the most famous neurosurgeons in the world. The flow of visitors may sometimes feel a bit intense, but at the end of the day makes us proud of the work we do. The scientific activity has increased significantly, and is nowadays well-funded and even the youngest colleagues can be financially supported. The visibility of the Department and its chairman in the Finnish society and the international neurosurgical community has definitely brought support along with it.

Overall, the changes during the past two decades have been so immense that they seem almost difficult to believe. If there is a lesson to be learned, it could be this: with sufficient dedication and endurance in the face of resistance, almost everything is possible. If you truly believe the change you are trying to make is for the better, you should stick to it no matter what, and it will happen.

*Table 2-1.*

*Professors of Neurosurgery in University of Helsinki:*

*Aarno Snellman 1947-60*

*Sune Gunnar Lorenz af Björkesten 1963-73*

*Henry Troupp 1976-94*

*Juha Hernesniemi 1998-*

## 2.2. PRESENT DEPARTMENT SETUP

By 2009, the Department of Neurosurgery which has an area of only 1562 m<sup>2</sup>, utilizing up to 16 ICU beds, 50 beds on two regular wards and four operating rooms, was carrying out a total of 3200 cases per year. Only 60% of patients are coming for planned surgery and 40% are coming through the emergency unit. This means that the care given in all our units is very acute in nature and the patients often have their vital and neurological functions threatened. The needed care has to be given fast and accurately in all units. The department's team has become successful in setting standards in quality, efficiency and microneurosurgery, not just in Nordic countries but worldwide. Often, patients are sent here from around Europe, and even from outside Europe, for microneurosurgical treatment of their aneurysm, AVM or tumor. The department, managed by Professor and Chairman Juha Hernesniemi and Nurse Manager Ritva Salmenperä (Figure 2-4), belongs administratively to Head and Neck Surgery, which is a part of the operative administrative section of Helsinki University Central Hospital. As a university hospital department, it is the only neurosurgical unit providing neurosurgical treatment and care for over 2 million people in the Helsinki metropolitan area and surrounding Southern and Southeastern Finland. Because of population responsibility, there is practically no selection bias for treated neurosurgical cases and patients remain in follow-up for decades. These two facts have helped to create some of the most cited epidemiological follow-up studies e.g. in aneurysms, AVMs and tumors over the past decades. In addition to operations and in-patient care, the department has an outpatient clinic with two or three neurosurgeons seeing daily patients coming for follow-up check-ups or consultations, with approximately 7000 visits per year.

## 2.3. STAFF MEMBERS

In neurosurgery success is based on team effort. The team at Helsinki Neurosurgery currently consists of 16 specialist neurosurgeons, seven neurosurgical residents, six neuroanesthesiologists, five neuroradiologists, and one neurologist. There are 150 nurses working on the different wards, four physiotherapists, three OR technicians, three secretaries and several research assistants. In addition, we have a very close collaboration with teams from neuropathology, neuro-oncology, clinical neurophysiology, endocrinology and both adult and pediatric neurology.



Figure 2-4. Nurse Manager Ritva Salmenperä



### 2.3.1. Neurosurgeons

At the beginning of the year 2010 there were 16 board certified neurosurgeons and one neurologist working at Helsinki Neurosurgery:



Juha Hernesniemi, MD, PhD  
Professor of Neurosurgery and Chairman

MD: 1973, University of Zürich, Switzerland; PhD: 1979, University of Helsinki, Finland, "An Analysis of Outcome for Head-injured Patients with Poor Prognosis"; Board certified neurosurgeon: 1979, University of Helsinki, Finland; Clinical interests: Cerebrovascular surgery, skull base and brain tumors; Areas of publications: Neurovascular disorders, brain tumors, neurosurgical techniques.



Jussi Antinheimo, MD, PhD  
Staff neurosurgeon

MD: 1994, University of Helsinki, Finland; PhD: 2000, University of Helsinki, Finland, "Meningiomas and Schwannomas in Neurofibromatosis 2"; Board certified neurosurgeon: 2001, University of Helsinki, Finland; Clinical interests: Complex spine surgery; Areas of publications: Neurofibromatosis type 2.



Göran Blomstedt, MD, PhD  
Associate Professor, Vice Chairman,  
Head of section (Outpatient clinic)

MD: 1975, University of Helsinki, Finland; PhD: 1986, University of Helsinki, Finland, "Postoperative infections in neurosurgery"; Board certified neurosurgeon: 1981, University of Helsinki, Finland; Clinical interests: Brain tumors, vestibular schwannomas, epilepsy surgery, peripheral nerve surgery; Areas of publication: Neurosurgical infections, brain tumors, epilepsy surgery.



Atte Karpinen, MD  
Staff neurosurgeon

MD: 1995, University of Helsinki, Finland; Board certified neurosurgeon: 2003, University of Helsinki, Finland; Clinical interests: Pediatric neurosurgery, epilepsy surgery, pituitary surgery, neuroendoscopy.



Riku Kivisaari, MD, PhD  
Assistant Professor

MD: 1995, University of Helsinki, Finland; PhD: 2008, University of Helsinki, Finland, "Radiological imaging after microsurgery for intracranial aneurysms"; Board certified radiologist: 2003, University of Helsinki, Finland; Board certified neurosurgeon: 2009, University of Helsinki, Finland; Clinical interests: Endovascular surgery, cerebrovascular diseases ; Areas of publications: Subarachnoid hemorrhage, cerebral aneurysms.



Leena Kivipelto, MD, PhD  
Staff neurosurgeon

MD: 1987, University of Helsinki, Finland; PhD: 1991, University of Helsinki, Finland, "Neuropeptide FF, a morphine-modulating peptide in the central nervous system of rats"; Board certified neurosurgeon: 1996, University of Helsinki, Finland; Clinical interests: Cerebrovascular surgery, bypass surgery, pituitary surgery, spine surgery; Areas of publications: Neuropeptides of central nervous system, neuro-oncology.



Aki Laakso, MD, PhD  
Staff neurosurgeon, Associate Professor  
in Neurobiology

MD: 1997, University of Turku, Finland; PhD: 1999, University of Turku, Finland, "Dopamine Transporter in Schizophrenia. A Positron Emission Tomographic Study"; Board certified neurosurgeon: 2009, University of Helsinki, Finland; Clinical interests: Cerebrovascular diseases, neuro-oncology, neurotrauma, neurointensive care; Areas of publications: Brain AVMs and aneurysms, basic neuroscience.



Miikka Korja, MD, PhD  
Staff neurosurgeon

MD: 1998, University of Turku, Finland; PhD: 2009, University of Turku, Finland, "Molecular characteristics of neuroblastoma with special reference to novel prognostic factors and diagnostic applications"; Board certified neurosurgeon: 2010, University of Helsinki, Finland; Clinical interests: Cerebrovascular surgery, functional neurosurgery, skull base surgery, neuroendoscopy; Areas of publications: Tumor biology, subarachnoid hemorrhage, neuroimaging, bypass surgery.



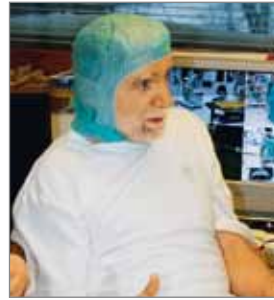Martin Lehecka, MD, PhD  
Staff neurosurgeon

MD: 2002, University of Helsinki, Finland; PhD: 2009, University of Helsinki, Finland, "Distal Anterior Cerebral Artery Aneurysms"; Board certified neurosurgeon: 2008, University of Helsinki, Finland; Clinical interests: Cerebrovascular surgery, bypass surgery, skull base and brain tumors, neuroendoscopy; Areas of publications: Cerebrovascular diseases, microneurosurgical techniques.



Mika Niemelä, MD, PhD  
Associate Professor, Head of section  
(Neurosurgical OR)

MD: 1989, University of Helsinki, Finland; PhD: 2000, University of Helsinki, Finland, "Hemangioblastomas of the CNS and retina: impact of von Hippel-Lindau disease"; Board certified neurosurgeon: 1997, University of Helsinki, Finland; Clinical interests: Cerebrovascular diseases, skull base and brain tumors; Areas of publications: Cerebrovascular disorders, brain tumors, basic research on aneurysm wall and genetics of intracranial aneurysms.



Juha Pohjola, MD  
Staff neurosurgeon

MD: 1975, University of Zürich, Switzerland; Board certified neurosurgeon: 1980, University of Helsinki, Finland; Clinical interests: Complex spine surgery, functional neurosurgery.



Minna Oinas, MD, PhD  
Staff neurosurgeon

MD: 2001, University of Helsinki, Finland; PhD: 2009, University of Helsinki, Finland, " $\alpha$ -Synuclein pathology in very elderly Finns"; Board certified neurosurgeon: 2008, University of Helsinki, Finland; Clinical interests: Pediatric neurosurgery, skull base and brain tumors; Areas of publications: Neurodegenerative diseases, tumors.



Esa-Pekka Pälvimäki, MD, PhD  
Staff neurosurgeon

MD: 1998, University of Turku, Finland; PhD: 1999, University of Turku, Finland, "Interactions of Antidepressant Drugs with Serotonin 5-HT<sub>2C</sub> Receptors."; Board certified neurosurgeon: 2006, University of Helsinki, Finland; Clinical interests: Spine surgery, functional neurosurgery; Areas of publications: Neuroparmacology, functional neurosurgery.



Jari Siironen, MD, PhD  
Associate Professor, Head of section (ICU)

MD: 1992, University of Turku, Finland; PhD: 1995, University of Turku, Finland, "Axonal regulation of connective tissue during peripheral nerve injury"; Board certified neurosurgeon: 2002, University of Helsinki, Finland; Clinical interests: Neurotrauma, neurointensive care, spine surgery; Areas of publications: Subarachnoid hemorrhage, neurotrauma, neurointensive care.



Matti Wäänänen, MD  
Staff neurosurgeon

MD: 1980, University of Kuopio, Finland; Board certified general surgeon: 1986, University of Kuopio, Finland; Board certified orthopedic surgeon: 2003, University of Helsinki, Finland; Board certified neurosurgeon: 2004, University of Helsinki, Finland; Clinical interests: Complex spine surgery, peripheral nerve surgery.



Matti Seppälä, MD, PhD  
Staff neurosurgeon

MD: 1983, University of Helsinki, Finland; PhD: 1998, University of Helsinki, Finland, "Long-term outcome of surgery for spinal nerve sheath neoplasms"; Board certified neurosurgeon: 1990, University of Helsinki, Finland; Clinical interests: Neuro-oncology, radiosurgery, spine surgery; Areas of publications: Neuro-oncology, neurotrauma, spine surgery.



Maija Haanpää, MD, PhD  
Associate Professor in Neurology

MD: 1985, University of Kuopio, Finland; PhD: 2000, University of Tampere, Finland, "Herpes zoster – clinical, neurophysiological, neuro-radiological and neurovirological study"; Board certified neurologist: 1994, University of Tampere, Finland; Clinical interests: Chronic pain management, neurorehabilitation, headache; Areas of publications: Pain management, neuropathic pain, neurorehabilitation.



Figure 2-22. Neuroanesthesiologists at Töölö Hospital. Back: Marja Silvasti-Lundell, Juha Kyttä, Markku Määttänen, Päivi Tanskanen, Tarja Randell, Juhani Haasio, Teemu Luostarinen. Front: Hanna Tuominen, Ann-Christine Lindroos, Tomi Niemi

### 2.3.2. Neurosurgical residents

There are currently nine neurosurgical residents in different phases of their 6-year neurosurgical training program:

Juhana Frösén, MD, PhD  
 Emilia Gaal, MD  
 Antti Huotarinen, MD  
 Juri Kivelev, MD  
 Päivi Koroknay-Pál, MD, PhD  
 Hanna Lehto, MD  
 Johan Marjamaa, MD, PhD  
 Anna Piippo, MD  
 Julio Resendiz-Nieves, MD, PhD

### 2.3.3. Neuroanesthesiologists

The team of anesthesiologists at Helsinki Neurosurgery, six of them specialists in neuroanesthesia, is led by Associate Professor Tomi Niemi. In addition there are usually a couple of residents or younger colleagues in training. During daytime four of the anesthesiologists are assigned to the OR's and two work at the neurosurgical ICU. Collaboration between anesthesiologists and neurosurgeons is very close both in and out of the OR. There are joined rounds at the ICU twice a day.

Tomi Niemi, MD, PhD  
 Hanna Tuominen, MD, PhD  
 Juha Kyttä, MD, PhD (1946-2010)  
 Juhani Haasio, MD, PhD  
 Marja Silvasti-Lundell, MD, PhD  
 Markku Määttänen, MD  
 Päivi Tanskanen, MD  
 Tarja Randell, MD, PhD



Figure 2-23. Neuroradiologists at Töölö Hospital. From left: Kristiina Poussa, Jussi Laalo, Marko Kangasniemi, Jussi Numminen, Goran Mahmood.

#### 2.3.4. Neuroradiologists

A dedicated team of five neuroradiologists and one or two residents or younger colleagues is lead by Associate Professor Marko Kangasniemi. The neuroradiological team is taking care of all the neuroimaging. That includes CT, MRI, and DSA imaging. Endovascular procedures are carried out in a dedicated angio suite by neuro-radiologists in close collaboration with neurosurgeons. Every morning at 08:30 AM there is a joined neuroradiological meeting that is attended by all the neurosurgeons and the neuroradiologists.

Marko Kangasniemi, MD, PhD  
 Jussi Laalo, MD  
 Jussi Numminen, MD, PhD  
 Johanna Pekkola, MD, PhD  
 Kristiina Poussa, MD



Figure 2-24. Staff of bed ward No. 6, with head nurse Marjaana Peittola (sitting, second from right)

### 2.3.5. Bed wards

The department of neurosurgery has a total of 50 beds in two wards. Of the 50 beds, seven are intermediate care beds and 43 unmonitored general beds. In addition, there are two isolation rooms. The isolation rooms are equipped with full monitoring possibilities and can be used for intensive care purposes as well, if needed.

Patients coming for minor operations, for example spinal surgery, usually spend relatively short time on the ward, 1-2 days after operation before being discharged. Patients coming for major surgery, for example brain tumor or unruptured aneurysm, stay for 5 to 8 days, and emergency patients recovering from severe disease or brain injury can stay in the department for up to 2 months. Average stay for all patients is 4.6 days.

The staff at bed wards consists of one head nurse at each ward, nursing staff of 45 nurses and 3 secretaries. There are two physiotherapists present at both wards and ICU. The staff is professional and motivated in their work. One of the main duties for ward nurses is to perform neurological assessment and register findings so that the continuity of care is ensured. They also take care of medication, nutrition and electrolyte balance, interview patients for health history, perform wound care and stitch removal, give information and home instructions and educate the patients.

The intermediate care room is meant for patients who still require ventilator support but do no longer fulfill the criteria for intensive care treatment. Typical patients are recovering from severe head trauma or acute hemorrhagic





*Figure 2-25. Staff of bed ward No. 7, with head nurse Päivi Takala (left)*

stroke. Patients can have problems with breathing, still need respiratory care, have problems with nutrition, anxiety and pain; all this care is given by our staff nurses. There are one or two nurses present at all times. When needed, the nurses alert also neurosurgeons and anesthesiologists based on their observations. The nurses in the two wards rotate in intermediate care room so that everyone is able to take care of all critically ill patients.



Figure 2-26. Staff of ICU, with head nurse Petra Ylikukkonen (front row, third from left).

### 2.3.6. Intensive care unit (ICU)

The neurosurgical ICU has 14 beds and two recovery beds for patients with minor operations who only need a couple of hours of monitoring and observation. Additionally, there are two isolation rooms for severe infections, or patients coming for treatment from outside of Scandinavia (to prevent spread of multiresistant micro-organisms). The staff consists of the head nurse, 59 nurses and a ward secretary. In the ICU one nurse is usually taking care of two patients with some exceptions. Small children and parents have special needs and have their own nurse. Critically ill and unstable patients, e.g. high intracranial pressure or organ donor patients also have their own nurse.

All patients undergoing surgery are treated in the ICU that also functions as a recovery room. In 2009, 3050 patients were treated in the ICU. Half of the patients stay at the ICU for less than 6 hours recovering from surgery. Intensive care nurses take care of patient monitoring and do the hourly neurological assessment. Monitor-

ing includes for example vital signs,  $pCO_2$ , GCS,  $SvO_2$ , EEG, intracranial pressure and cerebral perfusion pressure, depending on the patient's needs. Nurses also take care of pain and anxiety relief. Neurosurgeons make the majority of the decisions concerning patient care, discuss with the patient and family members, make notes to the charts and perform required bedside surgical interventions, such as percutaneous tracheostomies, ventriculostomies and implanting ICP monitoring devices. Neuroanesthesiologists are in charge of medication, respiratory management, nutrition and monitoring of laboratory parameters. Joint rounds between neurosurgeons, neuroanesthesiologists and nurses take place twice a day, in the morning and in the afternoon. The multidisciplinary team also includes physiotherapists and, when needed, consultants of different disciplines, like infectious diseases and orthopedic, maxillofacial and plastic surgery.

The ICU is a very technical environment with electronic patient files and computerized data collection. ICU nurses have to provide safe and continuous care to the patient who is facing an acute, life-threatening illness or injury. Depending on the nurse's previous background and experience, the critical care orientation program takes 3-5 weeks of individual training with preceptors, and after that the amount of more independent work increases gradually. Critically ill patients, organ donors and small children are allocated to nurses only after he or she has sufficient experience in common procedures and protocols. The last step after two or three years of experience is to work as a team leader during the shift, i.e. the nurse in charge. Nurses in the ICU perform strenuous shift work and many prefer working long shifts of 12.5 hours, which gives them the opportunity to have more days off than working the normal 8 hour shift. ICU nurses have autonomy in planning the shifts, making it easier to accommo-

date work and personal life. This principle of planning the working hours is the same in all units, but it works especially well in the ICU where the staff is quite large.



Figure 2-27. Operating room staff, with head of section Dr. Mika Niemelä (standing in the back), head nurse Saara Vierula (front row, first from right) and head nurse Marjatta Vasama (front row, fourth from right).

### 2.3.7. Operating rooms

The four OR's are located in a recently renovated and redecorated area. It gives a nice surrounding for a work that in many aspects is very technical and demanding. The focus of nursing care in the OR is to treat patients safely and individually, even though emergency situations may require such rapid thinking and decision-making that things may almost appear to happen by themselves.

There are two head nurses (surgical and anesthesiological), 28 nurses and three OR technicians working in four OR's. Nurses are divided into two groups: scrub nurses and neuroanesthesiological nurses. Nurses are working in two shifts, and two scrub nurses and one anesthesiological nurse are on call starting from 8 PM to 8 AM. Because almost half of our patients are emergency patients, the active working hours for those on call usually continues until midnight or later, and the next day is free. During weekends the nurses are also on call, and two teams share one weekend.

The staff is relatively small, the work in neurosurgical OR is highly specialized, and the familiarization and orientation takes several months under the supervision of the preceptor. The tasks of scrub nurses include patient positioning (done together with technicians, the neurosurgeon and the anesthesiologist), the skin preparation, draping, instrumentation, and dressing. Anesthesiological nurses do the preparations for anesthesia and intraoperative monitoring and take care of reporting and documentation. Anesthesiological nurses also take patients to neuroradiological examinations and interventions and take care of and monitor patients during these procedures.

Work rotation is encouraged between all units. After a couple of years of concentrating either on anesthesia or instrumentation we try to encourage the nurses, who are interested in expanding their knowledge and skills, to be able to work both as an scrub nurse and an anesthesiological nurse. There is also work ro-



Fig 2-28. Administrative assistants Heli Holmström, Eveliina Salminen and Virpi Hakala.

### 2.3.8. Administrative personnel

tation between ICU and OR, ICU and bed wards, and we have nurses who have been working in all three units.

Nursing students are trained continuously in all units. Special attention is paid to inspire an interest in neurosurgery in them, since they might be our future employees. We hope that both students and our nurses approach neurosurgical nursing from a perspective of career rather than merely a job. This can result in a high level of satisfaction and more options for professional advancement. There is a well-established co-operation with Finnish Association of Neuroscience Nurses (FANN), European Association of Neuroscience Nurses (EANN) and World Federation of Neuroscience Nurses (WFNN). This gives an opportunity to do national and international co-operation and gives possibilities to attend meetings, meet colleagues in the same field and visit other interesting neurosurgical departments in world in the same way as many visitors are attending our department nowadays.

A small but absolutely invaluable part of the Department's personnel is found on the administrative floor, where three administrative assistants, Virpi Hakala, Eveliina Salminen and Heli Holmström, take care of myriads of things to ensure e.g. that patient referral letters are handled reliably and in timely fashion, the whole staff gets their paychecks, needs of foreign visitors are accommodated, Prof. Hernesniemi's flight tickets and hotel reservations are up-to-date despite last minute changes of an extremely busy schedule... In other words, this is work that you may not appreciate enough because these things are managed so smoothly and professionally "behind the scenes" that you do not even realize the immense workload required to keep the wheels of the Department lubricated – unless there would be a glitch and nothing would work anymore!

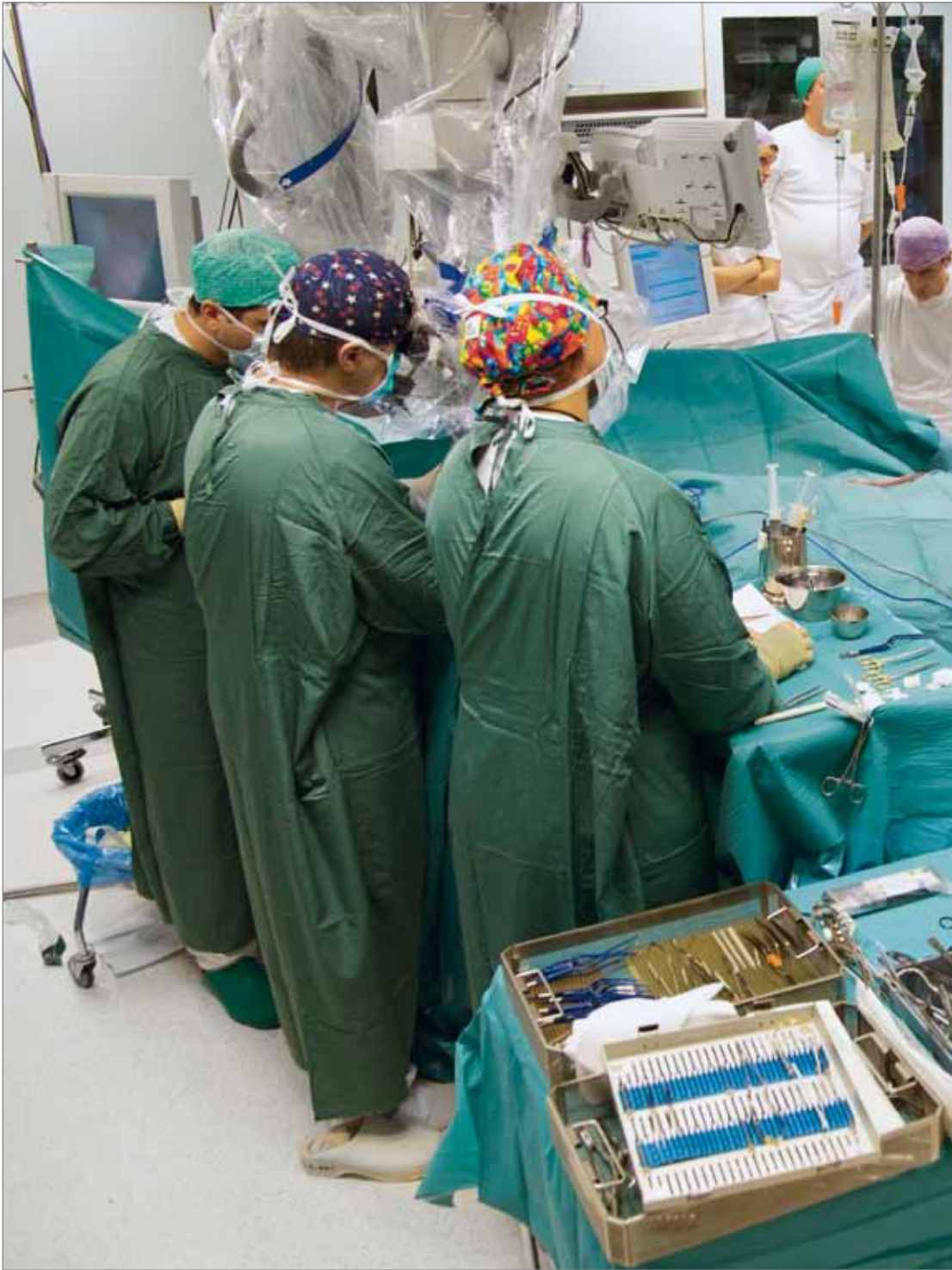
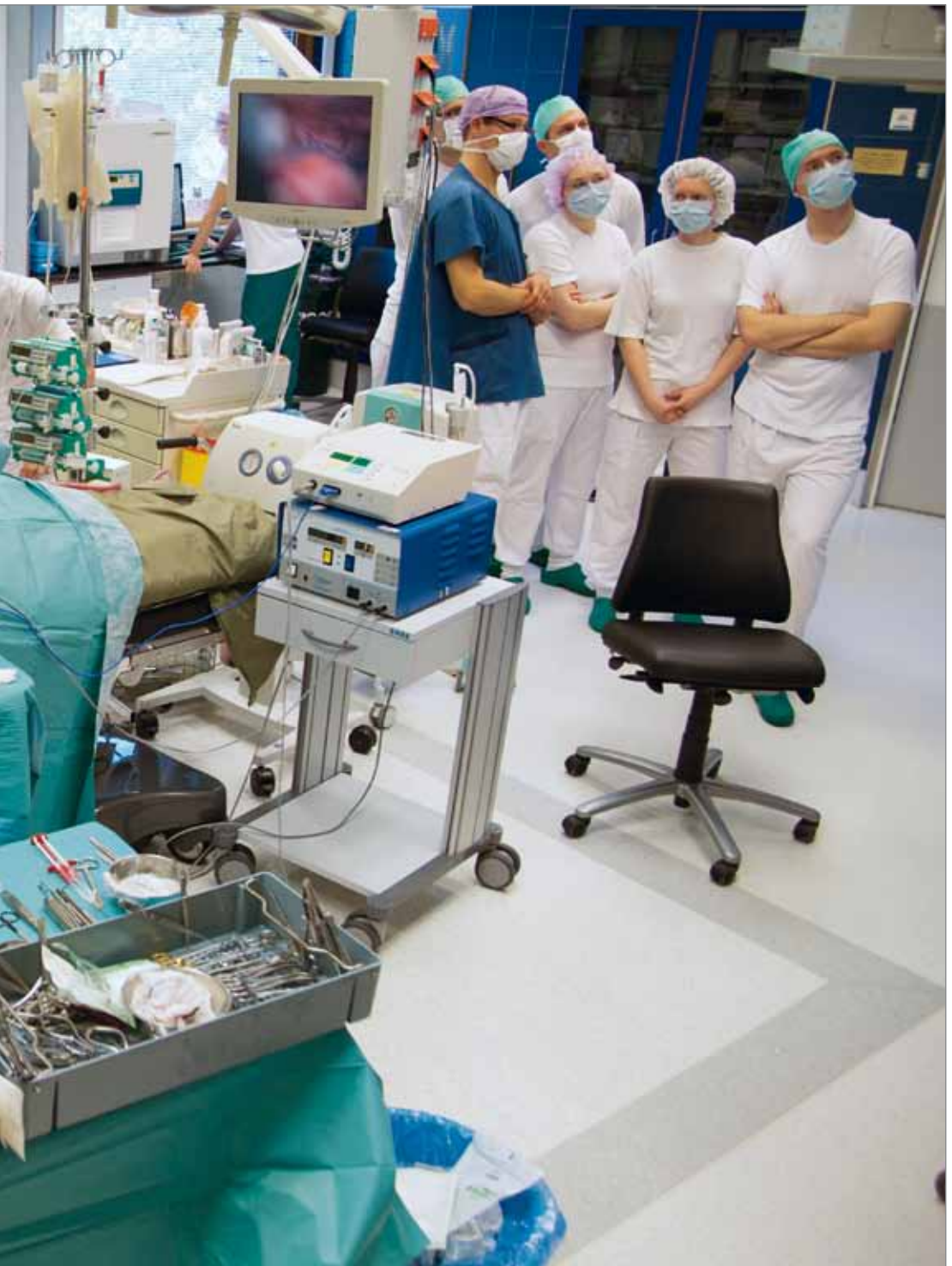
Fig 2-29. Overview of the OR1



## 2.4. OPERATING ROOM COMPLEX

### 2.4.1. Operating room complex design

The OR complex in Helsinki is dedicated solely to neurosurgery. It has four separate OR's arranged in semicircular fashion. The whole complex was refurbished in 2005 according to the needs of modern microneurosurgery, with emphasis on efficient workflow, open and inviting atmosphere, and teaching with high quality audiovisual equipment. Besides the actual OR's, the complex includes also storage rooms, offices for anesthesiologists and nursing staff, a meeting room with library and an auditorium in the lobby of the complex. The setup in each of the OR's is similar and equipment can be easily moved from one room to the other. From each OR live video image can be displayed on big screen in the lobby. All OR's are used every day from 8 AM to 3 PM, one OR is open until 6 PM and one OR is used around the clock for emergency cases.

The operating room in Helsinki is also the anesthetic room. Some other countries and institutions have them separate. The advantage of using the same room is the avoidance of patient transfer and the inherent risks associated with this. The disadvantage is that the room has to have the appropriate space, storage, equipment, and ambience for both functions. In our experience, the time that is saved by having a separate anesthetic room is very limited compared to the length of the actual procedure, transferring the patient and the time spent reconnecting all the necessary cables and lines. After trying both options, we have settled for handling the whole anesthesia and patient positioning inside the operating room.



## 2.4.2. Operating room ambience

The atmosphere in any OR, let alone one where modern microneurosurgery is performed, may well be crucial for the difference between success and failure in the operation. Mutual respect between all members in the team is a key factor in creating a successful ambience. We also feel that it is a great asset that the nurses are dedicated to and very experienced in neurosurgical operations – often the correct instrument is handed over to the surgeon immediately without a need to say a word. Since working atmosphere and ambience may be difficult to evaluate from within the team (especially if it is good!), a testimony from a visitor with a wider perspective may elucidate the situation better. In the following, Dr. Mansoor Foroughi has described his observations and feelings:

*"It is said that the ideal socialist health care system provides the best health care at the lowest cost! In the Helsinki experience and the school of Juha Hernesniemi there are other major staff factors, which are included in the ideal health care system besides financial cost! These are a sense of professionalism, being valued, worker dignity, morale, sense of belonging to a greater good, solidarity and general happiness and welfare. These factors are not easily compromised on or sacrificed for a lower cost! The professionals that work here are easily worth more than their weight in gold. They seem to be happy here despite the heavy workload and number of visitors. This is in comparison to other places visited. Without a doubt they deserve more money and greater financial incentives than that we have been informed they get. We hope all societies reward those that work hard, train long and acquire special skills!"*

*"Several members of the staff repeat the story of how they moved from place to place and then ended up staying here as they really liked it. The reasons seem to be the following:*

- *They feel valued and appreciated. The surgeon habitually and genuinely thanks the theatre staff, especially after a difficult or long case. They are always listened to and their wishes and concerns noted. Whether it would be about lack of a piece of equipment or the choice of music in theatre. The scrub nurses look forward to the gentle nudge or other gestures of appreciation from Juha after a difficult or complex case. They clearly feel they are making a difference. So they pass the instruments with accuracy and efficiency, listen attentively, set up equipment promptly on demand, observe closely (using the excellent audiovisual equipment provided in theatre), operate the bipolar pedal with unerring calm & accuracy, follow the suture during closure and apply dressings. In general they want be involved a lot probably because they feel they are valued and making a difference.*
- *Professionalism and code of conduct. None of the fellows have ever witnessed on any occasion any suggestion or sign of rude or lewd behavior, loss of temper, shouting, intimidation, crying, obvious mental distress or bad conduct. This is most unusual for some visitors who are culturally or traditionally used to and accept the disturbing chat in theatre and even shouting. Some visitors accept the expressions of the surgical "artistic temperament" as normal everyday life. On the other hand we have never seen a frustrated or distressed surgeon because equipment is not available, or an instrument is not passed, or the bipolar is*

*not on or off at the appropriate time, or the nursing staff question the validity of a request for a laborious tool or an expensive item. What is needed is asked for by the surgeon, and it is immediately and efficiently provided!"*

*"It is hard to quantify happiness at work in a business plan, or highlight the importance of welfare for staff using some kind of scoring system or study. But if you visit Helsinki and spend sometime talking to the staff, you will come to know that they are generally content, and their performance is excellent because they are happy at work and happy with their leader! This is an example to the world."*

*"This is a place of order, peace, focus and professionalism. The anesthetist, surgeon, nursing staff and assistants all need to communicate. There should however be great consideration, respect and courtesy towards a neurosurgeon who is carrying out microneurosurgery in someone's brain. His or her senses are heightened and consequently the surgeon is very sensitive to the surroundings. Sudden interruptions, loud noises, audible telephone conversations and the rising volume of background chat can be dangerous. All such noises are discouraged and handled politely but appropriately. However a feeling of fear, anxiety and tension is also not appreciated or conducive for morale and welfare of staff, especially if the aim is to do good long term. All are generally calm, respectful and avoid commotion. There is no disturbing chat in the theatre complex in Helsinki no matter who is operating. You really feel the difference and contrast between the Nordic calm and professionalism and for example the Latino expression of emotion and commotion. If you want to be able to focus and encourage good surgery as a team, then learn from the Helsinki theatre ambience. All must be calm and respectful, but*

*allowed basic freedoms. Basic freedoms mean to come and go very quietly, be seated or stand comfortably and be allowed a good view of the surgery. At all times there is great consideration and respect for the team and the patient whom all are there to serve!"*

*"Some theatres ban the use of music but in Juha's theatre there is one radio station chosen for its neutral soft background music. This relaxes the staff and lessens any possible tension felt in theatre. If the surgeon, anesthetist or scrub nurse wish to turn this off or down, they can. The staff clearly appreciate this music, and many have stated that it relaxes them. The choice of the station is limited to one Finnish language station. The radio is switched off when there is extreme concentration, as well as immediate action and reaction needed from the team. This may be during temporary clipping or when there is haemorrhage from a ruptured aneurysm. Some visitors and especially fellows have had the same tunes, songs and even adverts imprinted in their memory while they were closely observing masterful surgery. Until they have learned how to listen and how not to listen! The surgeon they come to see is calmed by the music, but mostly seems to switch off to the music. He isolates himself from the world, and lives in the moment of surgery. There is a lesson on how to train yourself and compromise with your senses and those around you."*





### 3. ANESTHESIA

by Tomi Niemi, Päivi Tanskanen and Tarja Randell

In Helsinki University Central Hospital, the Department of Neuroanesthesia in Töölö Hospital has six neuroanesthesiologists. Daily four anesthesiologists of whom at least two are specialized in neuroanesthesia, work in the neurosurgical OR's and in the radiology suite, and two (at least one of them specialized in neuroanesthesia) at the neurosurgical ICU, and in the emergency room (ER) when needed. The perioperative anesthesia care includes preoperative assessment, management of the patients in the OR, and postoperative care in the ICU and also at the wards as required. In addition, one of three anesthesiologists who are on call in the hospital overnight is assigned to neuroanesthesia and neurointensive care.

In the Finnish system, the neuroanesthesia nurses are trained to take care of the patients in the OR, and also in the radiology suite, according to the clinical protocol and individual anesthesiologist's instructions. The anesthesiological nurses assist anesthesiologists in the induction of anesthesia, and during emergence; also, the anesthesiologist is always present during positioning. The maintenance of anesthesia is usually managed by the nurse, but the anesthesiologist is always available, and present if clinically required.

The principles of neuroanesthesia are based on general knowledge of cerebral blood flow (CBF), cerebral perfusion pressure (CPP), cerebral carbon dioxide ( $\text{CO}_2$ ) reactivity, and metabolic coupling, none of which can be continuously monitored during routine anesthesia. We base our clinical practice on the assumption that in most patients scheduled for craniotomy irrespective of the indication, the intracranial pressure (ICP) is on the steep part of the ICP-compliance-curve, with minimal reserve to compensate for any increases in the pressure

(Figure 3-1). However, once the dura is opened, ICP is considered to be zero and mean arterial pressure (MAP) equals CPP. The anesthesiologists must estimate these physiological principles according to the pathology of the central nervous system (CNS) before and during each anesthesia and he or she must understand the effects of all the perioperatively used drugs on them.

The objective of neuroanesthesia is to maintain optimal perfusion and oxygen delivery to the CNS during the treatment. Intraoperatively, we aim to provide good surgical conditions, i.e. slack brain, by means of various methods at our disposal (Table 3-1). Neurophysiologic monitoring during certain operations presents a challenge, knowing that most anesthesia agents interfere with monitoring of electroneuromyography (ENMG), evoked potentials and electroencephalography (EEG). Finally, we want to believe that our anesthesiological practice provides neuroprotection although there is no strong scientific evidence to support this idea in humans.

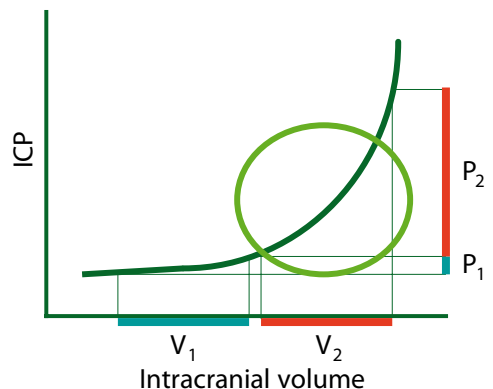


Figure 3-1. Intracranial pressure (ICP)-compliance curve indicating the relation of intracranial volume and ICP. On the steep part of the ICP-compliance-curve, the patient has minimal reserve to compensate for any increases in the ICP

Table 3-1. Helsinki concept of slack brain during craniotomy

**Positioning***Head 15–20 cm above heart level in all positions**Excessive head flexion or rotation is avoided → ensures good venous return***Osmotherapy***One of the three options below, given early enough before dura is opened**Mannitol 1g/kg i.v.**Furosemide 10–20 mg i.v. + mannitol 0.25–0.5 g/kg i.v.**NaCl 7.6% 100 ml i.v.***Choice of anesthetics***High ICP anticipated → Propofol infusion without N<sub>2</sub>O**Normal ICP → Propofol infusion or volatile anesthetics (sevoflurane/isoflurane ± N<sub>2</sub>O)***Ventilation and blood pressure***No hypertension**Mild hyperventilation**Note! With volatile anesthetics, hyperventilate up to PaCO<sub>2</sub> = 4.0–4.5kPa***CSF drainage***Lumbar drain in lateral park bench position**Release of CSF from cisterns or third ventricle through lamina terminalis intraoperatively**EVD if difficult access to cisterns*

### 3.1. GENERAL PHYSIOLOGICAL PRINCIPLES AND THEIR IMPACT ON ANESTHESIA

#### 3.1.1. Intracranial pressure

The rigid cranium presents a challenge to our clinical practice in neuroanesthesia, especially when the compensatory mechanisms seem to be limited in acute changes of the intracranial volume. Translocation of cerebrospinal fluid (CSF) to the spinal subarachnoid space, or reduction of the intracranial arterial blood volume by optimizing arterial CO<sub>2</sub> tension, or ensuring cerebral venous return by optimal head position and elevation above chest level, or osmotherapy may create more space prior to surgical removal of an intracranial space occupying lesion.

All inhalation anesthetics are potent cerebral vasodilators, and without concomitant mild hyperventilation they may cause significant increases in the ICP, when the compensatory mechanisms are exhausted. Therefore, induction of anesthesia with inhalation anesthetics is contraindicated in our department, especially because normoventilation or mild hyperventilation cannot be ensured during this critical phase

of anesthesia. Also, induction would require a concentration of anesthetic that exceeds the 1 MAC (minimum alveolar concentration) upper limit (see below). In patients with space occupying intracranial lesions with verified high ICP, or brain swelling during surgery, propofol is used for the maintenance of anesthesia, after the induction with thiopental. Inhalation anesthetics are contraindicated in such a situation. Propofol is known to decrease ICP, so whenever propofol infusion is used, hyperventilation is contraindicated. Nitrous oxide (N<sub>2</sub>O) is known to diffuse into air-containing spaces, resulting in their expansion, or in case of non-compliant space, in increased pressure. Therefore, N<sub>2</sub>O is contraindicated in patients who have undergone previous craniotomy within two weeks, or who show intracranial air on the preoperative CT-scan. In these patients the use of N<sub>2</sub>O could result in increase of the ICP due to enlargement of intracranial air bubbles.

### 3.1.2. Autoregulation of cerebral blood flow

Adequacy of the CPP must be assessed individually. CBF autoregulation is absent, or disturbed, at least locally in most neurosurgical patients, so that CBF becomes linearly associated with systemic arterial blood pressure (Figure 3-2). In addition, the CBF-CPP-autoregulation curve may also be shifted either to the right (especially in subarachnoid hemorrhage patients), or to the left (in children or in arteriovenous malformation patients), implying respective higher or lower CPP requirements to ensure adequate CBF (Figure 3-3). Furthermore, increased sympathetic activity, chronic hypertension, liver dysfunction, infection or diabetes may disturb CBF autoregulation.

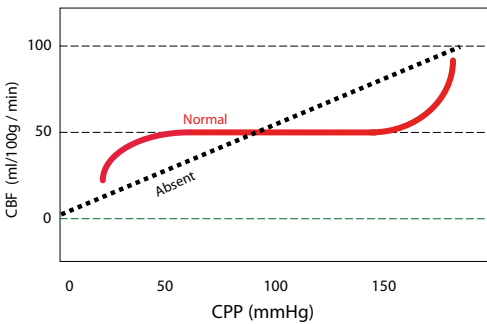


Figure 3-2. Normal or absent autoregulation of cerebral blood flow (CBF). CPP, cerebral perfusion pressure

The limits of autoregulation are estimated by assessing the effect of increase, or decrease, in MAP on CBF by means of ICP (or CBF) measurement. The static autoregulation is expressed as the percentage change of ICP (or CBF) related to the change of MAP over the predetermined interval. The dynamic autoregulation indicates the rate (in seconds) of response of the change in ICP (or CBF) to the rapid change in MAP. As the presence of intact autoregulation or the limits of autoregulation cannot be estimated in routine anesthesia practice, we must rely on the assumption of its state. In patients with SAH, or acute brain injury, autoregulation may

be disturbed or absent altogether, whereas, in some other neurosurgical patients it may be normal. As a result, normotension or estimated CPP of 60 mmHg or higher is the goal of our treatment. In SAH patients the lower limit of autoregulation may be much higher.

The volatile anesthetics are known to impair autoregulation in a dose-dependent fashion, whereas intravenous agents generally do not have this effect. Isoflurane and sevoflurane can be administered up to 1.0 and 1.5 MAC respectively, whereas desflurane impairs autoregulation already in 0.5 MAC. Therefore, isoflurane and sevoflurane are suitable for neuroanesthesia, and can be delivered either in oxygen-N<sub>2</sub>O mixture or in oxygen-air mixture. When N<sub>2</sub>O is used, the targeted anesthetic depth is achieved with smaller gas concentrations than without N<sub>2</sub>O. Bearing in mind that high concentrations of all inhaled anesthetics may evoke generalized epileptic activity, adding N<sub>2</sub>O to the gas admixture seems advantageous. The pros and cons of N<sub>2</sub>O are also discussed in section 3.4. For sevoflurane, it is not recommended to exceed 3% inhaled concentration in neuroanesthesia.

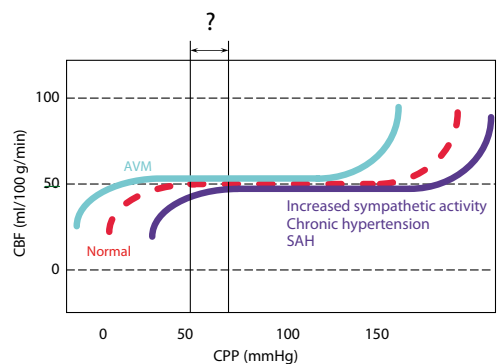


Figure 3-3. The assumed shift of the cerebral blood flow (CBF)- cerebral perfusion pressure (CPP)-autoregulation curve in subarachnoid hemorrhage (SAH) or in arteriovenous malformation (AVM) patients. The safe limits of the CPP must be assessed individually

### 3.1.3. CO<sub>2</sub> reactivity

The second clinically important factor regulating CBF is arterial CO<sub>2</sub> tension (PaCO<sub>2</sub>) (cerebral CO<sub>2</sub> reactivity). We generally normoventilate the patients during anesthesia. In patients with high intracranial pressure (ICP) or severe brain swelling, we may use slight hyperventilation, but in order to avoid brain ischemia PaCO<sub>2</sub> should not be allowed to decrease below 4.0 kPa. When even lower PaCO<sub>2</sub> is needed in the ICU, global cerebral oxygenation should be monitored by brain tissue oxygen tension to detect possible excessive vasoconstriction induced ischemia. In clinical practice it is of utmost importance to highlight the impairment of cerebral CO<sub>2</sub> reactivity during hypotension (Figure 3-4). The reactions of hypercapnia-induced cerebral vasodilatation (CBF↑, ICP↑) or hypocapnia-induced cerebral vasoconstriction (CBF↓, ICP↓) are impaired if the patient has hypotension. Thus, CBF and ICP may remain unchanged although PaCO<sub>2</sub> tension is modified in hypotensive patients. In contrast to the effect of PaCO<sub>2</sub> on CBF, the PaO<sub>2</sub> does not affect on CBF if PaO<sub>2</sub> is above 8 kPa, which is the critical level for hypoxemia. A powerful increase in CBF is seen when PaO<sub>2</sub> is extremely low, e.g. < 6.0 kPa.

While CO<sub>2</sub> reactivity is disturbed by various pathological states, it is rather resistant to anesthetic agents. In patients with an increased ICP or those with limited reserve for compensation, even modest increases of PaCO<sub>2</sub> may cause marked further increase in the ICP. Therefore, periods without ventilation must be kept as short as possible, for instance during intubation or awakening. As a categorical rule for craniotomy patients, hypoventilation must be avoided during awakening, because possible postoperative intracranial bleeding together with increased PaCO<sub>2</sub> may result in a detrimental increase in ICP.

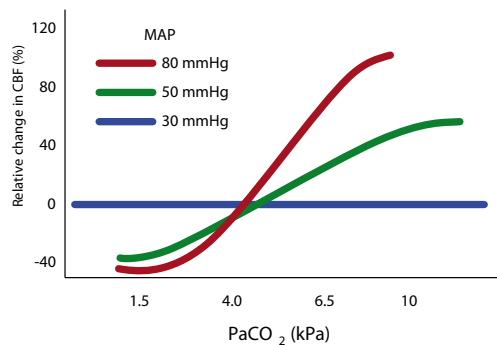


Figure 3-4. The effect of arterial carbon dioxide tension (PaCO<sub>2</sub>) on cerebral blood flow (CBF) at various mean arterial pressure (MAP) levels



### 3.1.4. Cerebral metabolic coupling

The third clinically important neuroanesthesiological aspect is cerebral metabolic coupling (Table 3-2). CBF is regulated by the metabolic requirements of brain tissue (brain activation CBF↑, rest or sleep CBF↓). Of brain cell metabolism, 40-50% is derived from basal cell metabolism and 50-60% from electrical activity. The electrical activity can be abolished by anesthetic agents (thiopental, propofol, sevoflurane, isoflurane), but only hypothermia can decrease both the electrical activity and the basal cell metabolism. Propofol seems to preserve coupling, but volatile agents do not. N<sub>2</sub>O seems to attenuate the disturbance. Impaired coupling results in CBF exceeding the metabolic demand (luxury perfusion).

*Table 3-2. The effects of anesthetic agents on cerebral metabolic rate for oxygen (CMRO<sub>2</sub>), cerebral blood flow (CBF), intracranial pressure (ICP) and cerebral arterial vasodilatation.*

	CMRO <sub>2</sub>	CBF	ICP	vasodilatation
Isoflurane	↓↓	↑ (↔*)	↑ (↔*)	+
Sevoflurane	↓↓	↑ (↔*)	↑ (↔*)	+
N <sub>2</sub> O	↑	↑	↑	+
Thiopental	↓↓↓	↓↓↓	↓↓	-
Propofol	↓↓	↓↓	↓↓	-
Midazolam	↓↓	↓↓	↓	-
Etomidate	↓	↓	↓	-
Droperidol	↓	↓	↓	-
Ketamine	↑	↑↑	↑↑	+

\*with mild hyperventilation

### 3.2. MONITORING OF ANESTHESIA

Routine monitoring in neuroanesthesia includes heart rate, ECG (lead II with or without lead V5), peripheral oxygen saturation, and non-invasive arterial blood pressure before invasive monitoring is commenced (Table 3-3). A radial or femoral arterial cannula is inserted for direct blood pressure measurements in all craniotomy patients or whenever the patient's medical condition requires accurate monitoring of hemodynamics or determination of repeated blood gas analyses.

The invasive arterial transducer set is zeroed at the level of the foramen of Monro. Central venous line for central venous pressure (CVP) measurements or right atrial catheter for possible air aspiration is not routinely inserted before surgery, not even for patients in sitting position. CVP, cardiac index and systemic vascular resistance may be monitored by means of arterial and central venous catheters (arterial pressure-based cardiac output, Vigileo™ or Picco™) in patients on vasoactive agents or needing extensive fluid administration at the OR or ICU. Hourly urine output is measured in all craniotomy patients.

Side-stream spirometry and airway gas parameters (inspired  $O_2$ , end-tidal  $CO_2$  and  $O_2$ , end-tidal sevoflurane/isoflurane, and MAC) are monitored after intubation. Ventilatory and airway gas measurements are performed from the breathing circuit at the connection piece with a filter and flexible tube at 20 cm distance to the tip of the intubation tube. The light disposable breathing circuit minimizes the risk of movement of the endotracheal tube during the actual positioning of the patient for the surgery. The cuff pressure of intubation tube is measured continuously.

Core temperature is measured with a nasopharyngeal temperature probe in all patients, and peripheral temperature with a finger probe in patients undergoing cerebrovascular bypass or microvascular reconstructions. During anesthesia blood gas analysis uncorrected for temperature is performed routinely to ensure optimal  $PaCO_2$  and  $PaO_2$ . In some cases, ICP is measured via ventriculostomy or intraparenchymal transducer before the dura is opened. In the sitting or semi-sitting position the precordial doppler ultrasonography probe is placed over the fifth intercostal space, just to the right of the sternum, to detect possible venous air emboli in the right atrium.

The neuromuscular blockade is monitored by a neurostimulator (train of four or double burst stimulation). The twitch response is evaluated from the arm that is not affected by a possible hemiparesis.

*Table 3-3. Routine monitoring for craniotomy*

- ECG
- Invasive blood pressure (zeroed at the level of Foramen Monroe)
- $SpO_2$
- $EtCO_2$
- Side stream spirometry, airway gas monitoring
- Hourly urine output
- Core temperature
- Neuromuscular blockade
- CVP and cardiac output (with PICCO™ or Vigileo™)  
– not monitored routinely\*

\* only in major bypass surgery, in microvascular free flaps in skull base surgery or if medically indicated.

### 3.3. PREOPERATIVE ASSESSMENT AND INDUCTION OF ANESTHESIA

On most occasions, preoperative evaluation is performed the day before the scheduled surgery, but in complicated cases, the patient can be invited to the hospital for a separate preoperative visit. In addition to clinical examination, ECG and laboratory tests are obtained (Table 3-4). As a general rule, patient's health status is optimized if the delay is not considered to worsen the patient's neurosurgical outcome.

Elective patients with normal consciousness are premedicated with oral diazepam, except for certain special procedures (e.g. surgery for epilepsy under neurophysiologic monitoring). Small children are premedicated with midazolam. Preoperatively, spontaneously breathing patients are usually not given any opioids in fear of respiratory depression and accumulation of CO<sub>2</sub> leading to an increase in ICP. Anticonvulsants are not discontinued preoperatively. However, in patients scheduled for epilepsy surgery, the preoperative dosage or type of anticonvulsants may be modified to enable intraoperative localization of epileptic foci by cortical EEG. Other prescribed drugs are considered individually. The cessation of antithrombotic drugs are discussed in section 3.7.4.

Before the induction of anesthesia we recommend glycopyrrolate 0.2 mg intravenously. The anesthesia for craniotomy is induced with intravenous fentanyl (5-7 µg/kg) and thiopental (3-7 mg/kg). Thiopental is preferred to propofol because of its verified antiepileptic property. The dose of fentanyl (5-7 µg/kg) is sufficient to prevent the hemodynamic response to laryngoscopy and intubation without delaying emerging from anesthesia. Orotracheal intubation is used, unless the surgical approach requires nasotracheal intubation. Supraglottic airways, such as laryngeal mask, are not used. The intubation tube is fixed firmly with tape without compressing jugular veins.

Possible hypotension (estimated CPP < 60 mmHg) is corrected immediately by increments of intravenous phenylephrine (0.025-0.1 mg) or ephedrine (2.5-5 mg). After intubation, mechanical volume controlled ventilation without any positive end-expiratory pressure (PEEP) is adjusted according to the end-tidal CO<sub>2</sub> together with hemodynamical profile. Later on, gas exchange is confirmed by arterial blood gas analysis. Volatile anesthetics are not administered until mild hyperventilation is confirmed.

*Table 3-4. Preoperative assessment by the anesthesiologist*

#### Coagulation profile

Normal → proceed normally  
Abnormal → corrective steps

#### Consciousness

Normal → proceed normally  
Decreased → no sedative premedication, plan for delayed extubation at NICU

#### Neurological deficits

Lower cranial nerve dysfunction → warn patient of prolonged ventilator therapy and possible tracheostomy

#### Pre-op CT/MRI scans

Normal ICP → proceed normally  
Signs of raised ICP → plan anesthesia accordingly (mannitol, choice of anesthetics)

#### Planning of approach and positioning

I.v.-lines, arterial cannula in appropriate extremity  
Easy access to airways  
Possibility of major bleeding → have blood cross checked  
Special techniques will be employed (e.g. adenosine) → prepare accordingly

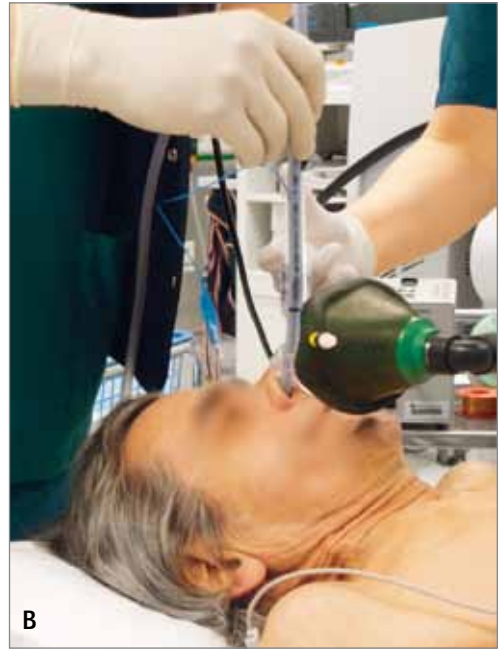
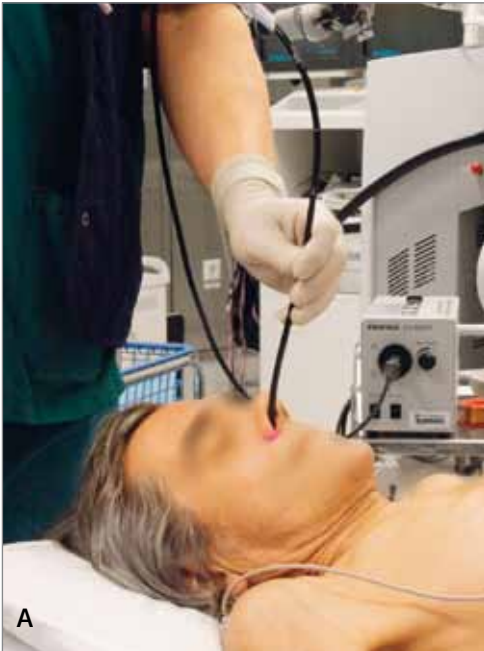
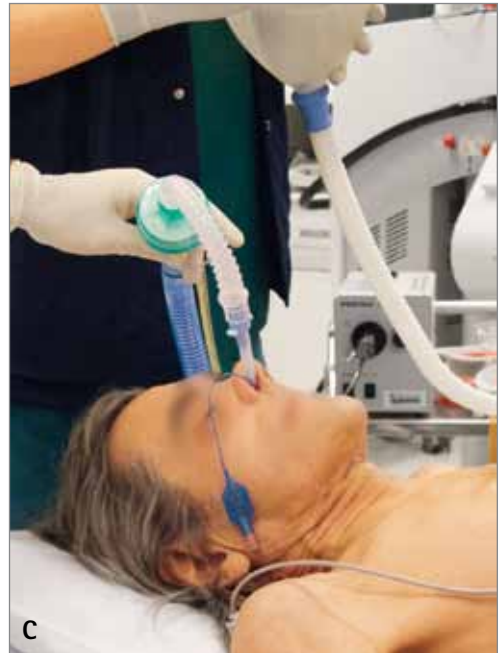
Figure 3-5. (a-c) Nasal endotracheal intubation under local anesthesia and light sedation in a patient with instability of cervical spine, performed by Dr. Juhani Haasio (published with patient's permission)

Neuromuscular blockade is achieved with rocuronium. Succinylcholine is administered, unless contraindicated, to facilitate intubation in patients requiring instant preparation for neurophysiological monitoring (motor evoked potential, MEP), or in selected cases of anticipated difficult airway. In patients with anticipated difficult intubation or instability in the cervical spine, nasal endotracheal intubation under local anesthesia and light sedation (fentanyl 0.05–0.1 mg i.v., diazepam 2.5–5 mg i.v.) is performed with fiberoptic (Figure 3–5). Topical anesthesia of the nasal passage is achieved with cotton sticks soaked in 4% lidocaine or cocaine, and topical anesthesia of the pharynx, larynx and trachea by injecting 4% lidocaine either transtracheally or sprayed through the working channel of the fiberoptic.



### 3.4. MAINTENANCE OF ANESTHESIA

The anesthesia method is selected according to the CNS pathology and the effects of various anesthetic agents on CBF and ICP (Table 3-2). Patients can be roughly divided into two categories: (1) those without any signs of raised ICP, scheduled for elective craniotomy, and (2) those with known high ICP, any acute trauma, or intracranial bleeding (Table 3-5). In selected cases, special approaches are needed.

If there are no signs of brain swelling or elevated ICP, anesthesia is maintained with sevoflurane or isoflurane in oxygen mixed with either N<sub>2</sub>O or air up to 1.0 MAC. In our practice, N<sub>2</sub>O is usually a component of inhalation anesthesia. It allows lower inspired concentrations of sevoflurane or isoflurane to achieve the adequate depth of anesthesia (1.0 MAC). One should remember, that the cerebral vasodilatory effect of N<sub>2</sub>O is blunted by the simultaneous administration of intravenous barbiturates, benzodiazepins or propofol. The poor solubility of N<sub>2</sub>O permits rapid recovery from anesthesia. We continue to give N<sub>2</sub>O until the end of surgery. N<sub>2</sub>O equilibrates with intracranial air before the dura is closed. Thus, once the dura is closed and N<sub>2</sub>O discontinued, the amount of intracranial air will decrease as N<sub>2</sub>O diffuses back into the bloodstream. The use of N<sub>2</sub>O during neurosurgery does not cause detrimental long-term neurologic or neuropsychological outcome. N<sub>2</sub>O is contraindicated in patients with increased risk of venous air embolism (VAE), re-craniotomy within a few weeks, severe cardiovascular disease or excessive air in body cavities (e.g. pneumothorax, intestinal occlusion or perforation).

In patients with signs of high ICP, acute brain injury, or tight brain during surgery, anesthesia is maintained with propofol infusion (6-12 mg/kg/hour) without any inhaled anesthetics. The discontinuation of all inhaled anesthetics often promptly decreases brain swelling without

any further interventions. However, if the brain continues to swell and threatens to herniate through the dural opening, additional doses of mannitol, hypertonic saline and thiopental may be given. Momentary deep hyperventilation (PaCO<sub>2</sub> 3.5 kPa) and head elevation can also attenuate brain congestion.

For intraoperative analgesia, either fentanyl boluses (0.1 mg) or remifentanyl infusion (0.125-0.25 µg/kg/min) is administered. Fentanyl is generally preferred in patients who are likely to need controlled ventilation postoperatively, and remifentanyl in those who will be extubated immediately after surgery. The dose of opioids is adjusted according to the pain stimuli during craniotomy. Remifentanyl effectively blocks the hemodynamic response induced by pain and can be given in 0.05 to 0.15 mg boluses prior to anticipated painful stimuli to prevent hypertension. Remifentanyl bolus is recommended before the application of the head holder pins. We do not routinely inject local anesthetics at the site of these pins except in awake patients. The site of skin incision is infiltrated with a mixture of ropivacaine and lidocaine combined with adrenalin. The most painful phases of cranial surgery are the approach through the soft tissues as well as wound closure. The repetitive small doses of fentanyl should be administered cautiously since the same total amount of fentanyl can cause markedly higher plasma concentrations given as small boluses compared to a greater single dose. In cases of sudden profound changes in blood pressure or heart rate, the neurosurgeon must be immediately notified, since surgical manipulation of certain brain areas may induce hemodynamical disturbances. Neuromuscular blockade is maintained with boluses of rocuronium as needed.

Table 3-5. Anesthesia in Helsinki Neurosurgical OR

**Preoperative medication**

- Diazepam 5–15 mg orally if normal consciousness
- In children (>1 year) diazepam or midazolam 0.3–0.5 mg/kg orally (max. 15 mg)
- Regular oral antiepileptic drugs
- Betamethasone (Betapred 4mg/ml) with proton pump inhibitor in CNS tumor patients
- Hydrocortison with proton pump inhibitor in pituitary tumors
- Regular antihypertensive (excluding ACE-inhibitors, diuretics), asthma and COPD drugs and statins
- Insulin i.v., as needed, in diabetic patients, B-gluc aim 5–8 mmol/l

**Induction**

- One peripheral i.v. cannula before induction, another 17-gauge i.v. cannula in antecubital vein after induction
- Glycopyrrolate 0.2 mg or 5 µg/kg (in children) i.v.
- Fentanyl 5–7 µg/kg i.v.
- Thiopental 3–7 mg/kg i.v.
- Rocuronium 0.6–1.0 mg/kg i.v. or succinylcholine 1.0–1.5 mg/kg i.v.
- Vancomycin 1 g (or 20 mg/kg) i.v. in 250 ml of normal saline in CNS surgery, otherwise cefuroxime 1.5 g i.v.
- 15% mannitol 500 ml (or 1g/kg) as indicated

**Pulmonary/airway management**

- Oral endotracheal intubation
- Nasal fiberoptic endotracheal intubation under local anesthesia if anticipated difficult airway or instability in cervical spine
- Firm fixation of intubation tube by tape without jugular vein compression
- Access to endotracheal tube in every patient position
- FiO<sub>2</sub> 0.4–1.0 (in sitting position and during temporary clipping 1.0). SaO<sub>2</sub> >95%, PaO<sub>2</sub> >13 kPa
- Normoventilation PaCO<sub>2</sub> 4.5–5.0 kPa with volume controlled ventilator, TV 7–10 ml/kg, respiration rate 10–15/min, no routine PEEP
- Mild hyperventilation (PaCO<sub>2</sub> 4.0–4.5 kPa) in primary surgery of TBI as needed and to counteract the vasodilatory effects of inhaled anesthetics

**Maintenance of anesthesia***Normal ICP, uncomplicated surgery*

- Sevoflurane (or isoflurane) in O<sub>2</sub>/N<sub>2</sub>O up to 1 MAC
- Fentanyl boluses (0.1 mg) or remifentanyl infusion (0.125–0.25 µg/kg/min)
- Rocuronium as needed

*High ICP, tight brain, emergency surgery*

- Propofol-infusion (6–12 mg/kg/hour)
- Remifentanyl infusion (0.125–0.25 µg/kg/min) or fentanyl boluses (0.1 mg)
- Rocuronium as needed
- No inhaled anesthetics

**Termination of anesthesia**

- Postoperative controlled ventilation and sedation is discussed in each case separately
- Normoventilation until removal of endotracheal tube, avoid hypertension
- Patient has to be awake, obey commands, breathe adequately and have core temperature above 35.0–35.5 °C before extubation.

ACE, angiotensin-converting enzyme; CNS, central nervous system; COPD, chronic obstructive pulmonary disease; FiO<sub>2</sub>, inspired oxygen concentration; TV, tidal volume; MAC, minimum alveolar concentration; TBI, traumatic brain injury; PEEP, positive end-expiratory pressure; i.v., intravenous.

### 3.5. TERMINATION OF ANESTHESIA

The need for postoperative controlled ventilation and sedation is evaluated on an individual basis. After infratentorial or central supratentorial (sellar-parasellar) surgery the patients are usually mechanically ventilated and kept sedated with propofol 2-4 hours postoperatively. After a control computer tomography (CT) scan they are allowed to awake slowly at the ICU. The function of cranial nerves is also assessed clinically before removal of the endotracheal tube if dysphagia is suspected. When a laryngo-pharyngeal dysfunction is verified (cranial nerves IX-X), the patient is promptly tracheostomized, as extubation would bear a risk for aspiration of gastric contents.

Before anticipated extubation, the end-tidal concentration of CO<sub>2</sub> should not be allowed to rise. In case of a postoperative intracranial hematoma, even mild hypercapnia can cause a marked increase in the ICP. The endotracheal tube is not removed until the patient is awake, obeys commands, breathes adequately and core temperature is above 35.0-35.5 °C. Before termination of anesthesia, recovery of neuromuscular function is also verified by neurostimulator (train of four or double burst stimulation). If the awakening time is prolonged beyond the expected elimination time of the effects of the anesthetic agents, a CT scan should be considered to rule out postoperative hematoma or other causes of unconsciousness. In neurosurgical patients, awakening can be slow after the excision of large tumors.

After discontinuation of the anesthetic agents, including the infusion of remifentanyl, the increase (or decrease) in arterial blood pressure must be controlled. Boluses of labetalol (10-20 mg i.v.) instantly decrease the blood pressure. Alternatively, intravenous clonidine (150 µg as infusion) may be administered 30 min before extubation in hypertensive patients. Any sudden increases in arterial blood pressure carry

a risk for intracranial bleeding or brain edema. This is especially true for AVM patients, who may be kept in mild hypotension for several days after surgery. In contrast, in SAH patients, normo- or mild hypertension is often desired once the aneurysm has been secured. The increase in blood pressure is achieved with phenylephrine infusion and/or intravenous fluid deficit correction by Ringer's acetate or rapidly degradable hydroxyethylstarch (tetrastarch).

If remifentanyl alone has been used to provide the intraoperative analgesia and a relatively long period of time has elapsed (> 2-4 hours) after the induction dose of fentanyl (5-7 µg/kg) without additional doses, an opioid (fentanyl 0.05-0.1 mg or oxycodone 2-4 mg intravenously) with or without intravenous paracetamol is given approximately 15 to 30 minutes before planned extubation. Without this additional pain medication, the risk of uncontrolled postoperative pain, hypertension and postoperative bleeding increases.

### 3.6. FLUID MANAGEMENT AND BLOOD TRANSFUSIONS

The objective of fluid therapy in neurosurgery is to keep the patient normovolemic. In general, neurosurgical patients should not be run dry as previously suggested. In Helsinki, Ringer's acetate (with or without additional sodium chloride) is the intravenous fluid covering the basal fluid requirements. The additional volume deficits are replaced by combination of Ringer's acetate (with or without additional sodium), hypo- or hypertonic saline, 6% tetrastarch in normal saline (hydroxyethylstarch, molecular weight 130 kDa, molar substitution ration 0.4), 4% albumin or blood products (fresh frozen plasma, red blood cell or platelet concentrates). Intravenous fluids containing glucose are administered only in hypoglycemic patients or with insulin in patients having type I diabetes.

Water movement across the blood brain barrier depends on the osmotic gradient between plasma and the brain. The plasma  $\text{Na}^+$  concentration correlates well with the osmotic pressure of the plasma and is a relatively accurate measure of the total body osmolality. It must be emphasized that a decrease in plasma osmolality by 1 mOsm/kg  $\text{H}_2\text{O}$  may increase intracranial water content by 5 ml resulting in an ICP increase of 10 mmHg, assuming that normal brain compliance is approximately 0.5 ml/mmHg.

Ringer's acetate (Na 130, Cl 112 mmol/l) is slightly hypotonic in relation to plasma and the infusion of large amounts (>2000-3000 ml) may increase brain water content. Therefore we add 20-40 mmol of NaCl in 1000 ml of Ringer's acetate to make it isotonic or slightly hypertonic. Correspondingly, the current colloid solutions, i.e. tetrastarch or 4% albumin, have both normal saline (NaCl 154 mmol/l) as a carrier solution, which is preferable in neurosurgical patients. The reason why we do not observe metabolic hyperchloremic acidosis related to NaCl administration in the OR or ICU may be the acetate in

Ringer's solution. Acetate is metabolized to bicarbonate in almost all tissues, which may keep the acid-base equilibrium normal.

The basal infusion rate of Ringer's acetate in adults is approximately 80-100 ml/hour. In children we administer fluid according to the Holliday-Segar formula. During neurosurgery the volume deficit by preoperative dehydration, increased body temperature, mannitol promoted urine output, or blood loss is replaced individually. In children during craniotomy, we start Ringer's acetate 10 ml/kg for the first hour and then continue with 5 ml/kg/hour. Postoperatively, 75% of normal fluid requirement is administered. Colloid solutions are given to replace plasma losses or whenever there is indication to improve circulation in hypovolemia. ICP reduction therapy includes 15% mannitol (500 ml or 0.25-1.0 g/kg) with or without furosemide or alternatively 100 ml of 7.6 % saline (if P-Na < 150 mmol/l). At the end of surgery special attention is paid to postoperative fluid balance. In the OR, the anesthesiologist also plan the primary treatment of patients having increased risk of cerebral salt wasting syndrome (increased risk for hypovolemia), syndrome of inappropriate secretion of antidiuretic hormone (SIADH) (fluid restriction) or diabetes insipidus (increased risk of hypovolemia and hyperosmolality).

Hematocrit below the level of 0.30-0.35 is the trigger for red blood cell transfusion to guarantee oxygen delivery. CBF and ICP are also increased during hemodilution. Coagulation capacity is impaired if hematocrit drops below 0.30. On the other hand, if it rises above 0.55 it reduces CBF due to increase in blood viscosity. In our practice, the target INR (International Normalized Ratio) is <1.5 or P-TT% > 60% (plasma partial thromboplastin time value, normal 70-130%) and platelet count >100x10<sup>9</sup>/l in patients undergoing CNS surgery.



### 3.7. ANESTHESIOLOGICAL CONSIDERATIONS FOR PATIENT POSITIONING

The neurosurgical principles of patient positioning in Helsinki are presented in section 4.4.2. and each positioning for different approaches are described in further detail in Chapter 5. The neurosurgeon and the anesthesiologist have to work closely together to optimize the surgical access without compromising the patient's medical condition due to improper positioning. The anesthesiologist is responsible for ensuring patient's oxygenation, ventilation and CPP during and after positioning, despite the possible short interruptions of monitoring. The anesthesiologist must personally supervise the correct placement of the endotracheal tube and the breathing circuit connected to the ventilator during patient positioning. The possibility of accidental compression of the airway during positioning or the actual surgery must be kept in mind. Therefore in our practice, the ventilator and anesthesia team are placed on the left side of the patient, or with the lateral position, on the side the patient is facing. This optimizes free access to the patient's airway as needed. The intravenous and arterial catheters should be securely attached. The intravenous lines for

anesthetic and vasoactive agents must be visible and easily available during anesthesia in all positions. Special care must also be taken to prevent excessive rotation or tilting of the neck and to avoid any peripheral nerve injury in these situations.

#### 3.7.1. Supine position

The head is elevated approximately 20 cm above the level of the heart in all positions (Figure 3-6). The anesthesia is induced in supine position, which is *per se* not related to serious cardiovascular adverse effects. The risk of movement of endotracheal tube is also minimal. In the supine position the functional residual capacity of lungs may be preserved by slight elevation of the upper body. The arms are placed beside the body.



Fig 3-6. Supine position

### 3.7.2. Prone, lateral park bench and kneeling positions

Adequate depth of anesthesia and neuromuscular blockade is provided before positioning starts. Otherwise, the patients with endotracheal tube may start coughing.

In contrast to supine position, cardiac output has been reported to decrease 17-24% in prone position, similarly as in sitting position (Figure 3-7). However, the decrease in cardiac output in prone position is not always associated with hypotension. Significant deterioration of cardiac output or hypotension has also been observed in the lateral position. Therefore,

it is mandatory to adjust arterial transducer set at the level of foramen Monro to observe any hypotension simultaneously as the patient's position is changed. If any hemodynamical difficulties arise, intravenous vasoactive agents are readily available to optimise CPP.

The lateral park bench (Figure 3-8) or prone position may decrease pulmonary function. However, in the lateral position the functional residual capacity may also increase in the non-dependent lung and compensate the effects of atelectasis formation in the dependent lung. In

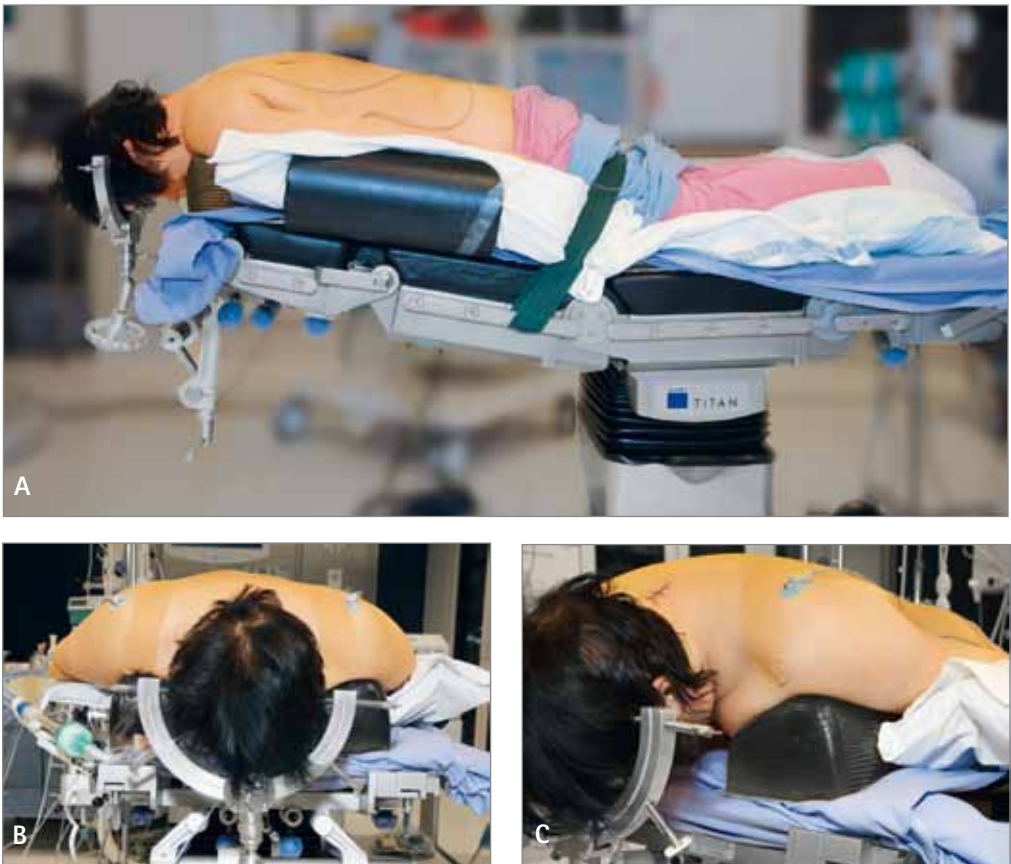
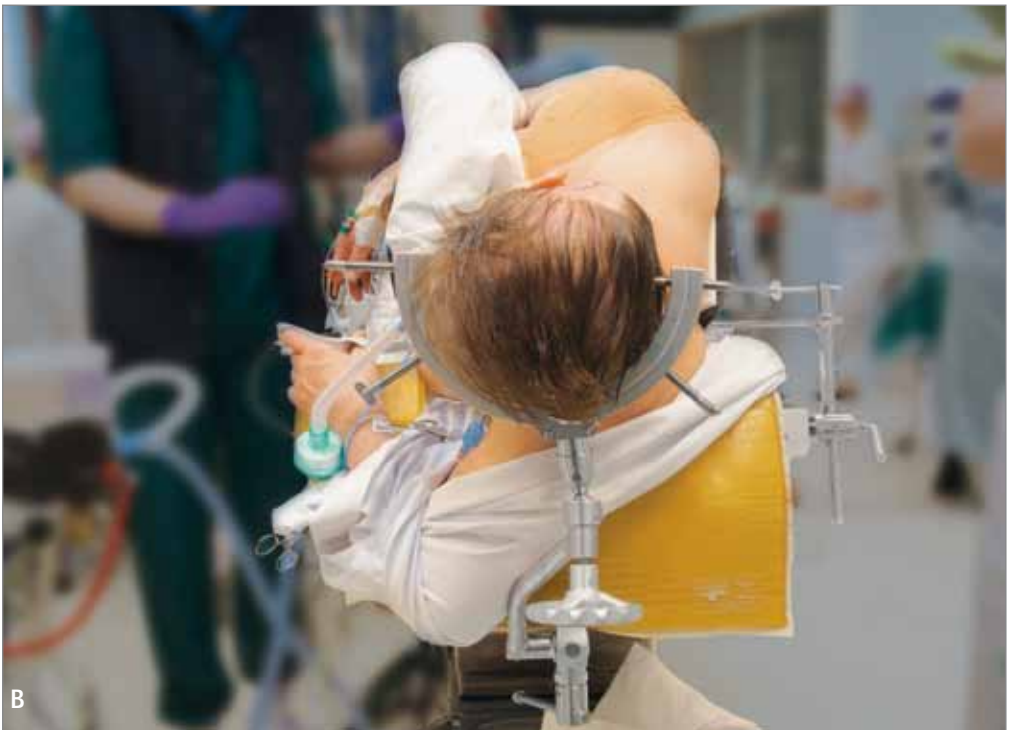
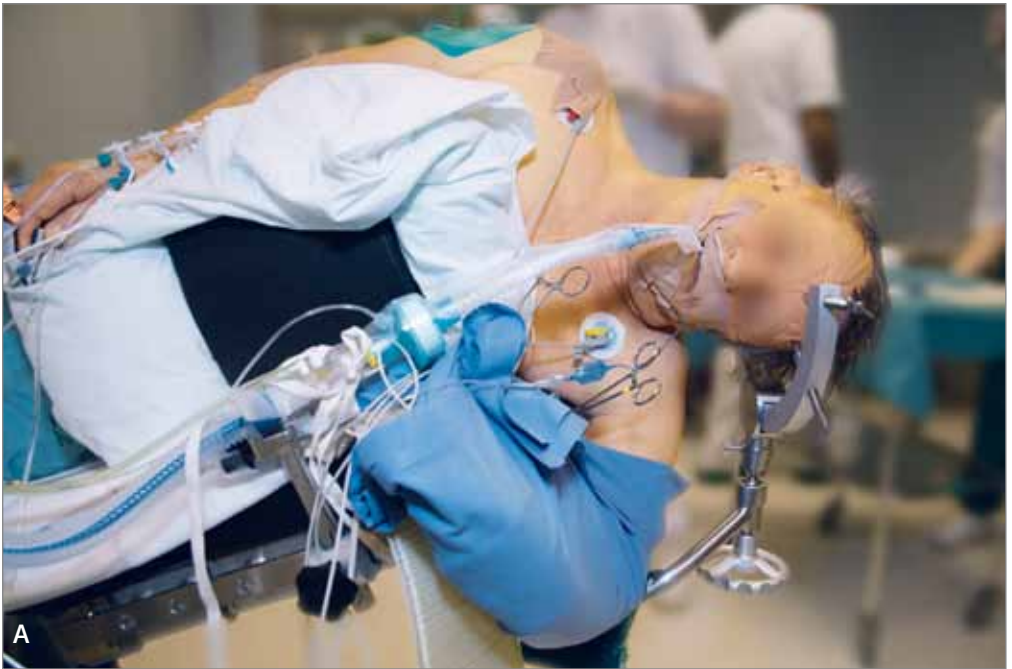Figure 3-7. Prone position from the side (a) and from the cranial end (b) of the table. (c) Gel cushions are used to support the patient



*Figure 3-8. Lateral park bench position from the side facing the anesthesiologist (a) providing unobstructed access to the patient's airways, and from the cranial end (b) of the table*

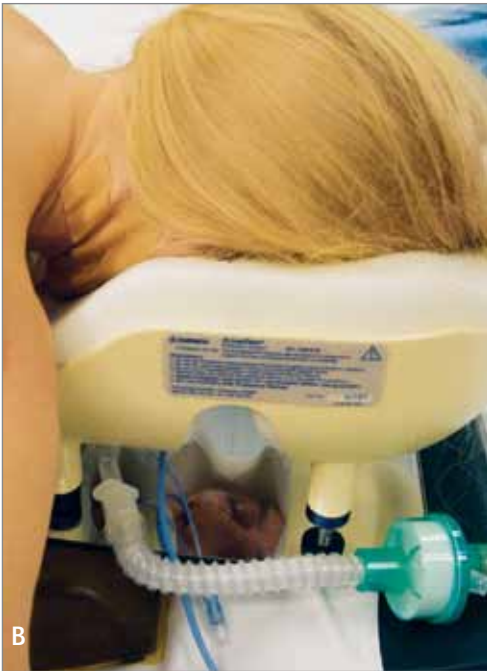
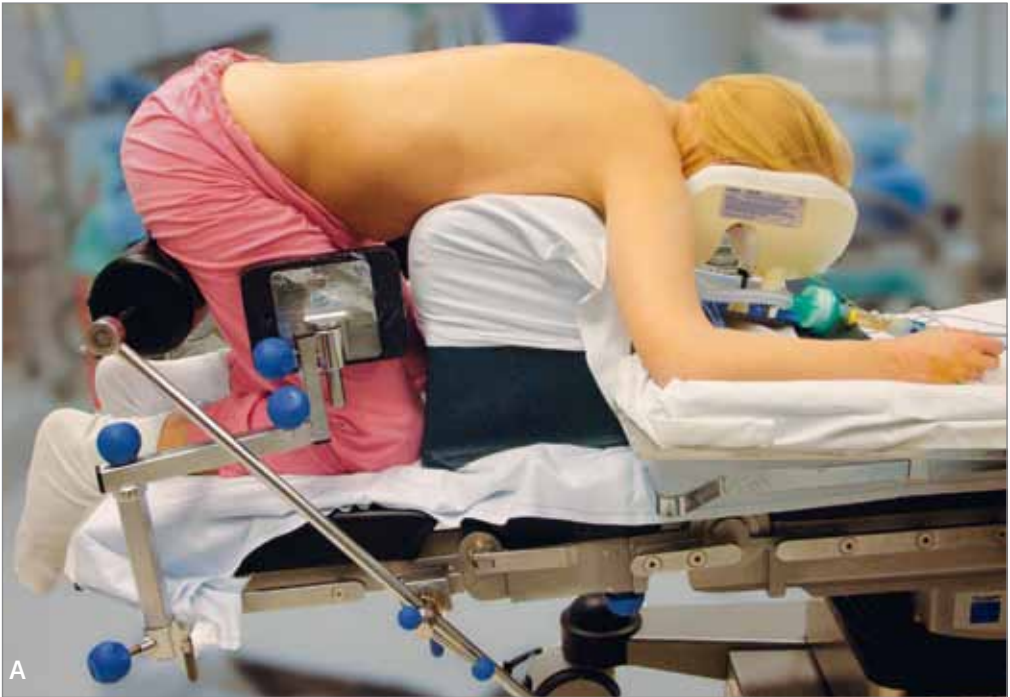
Figure 3-9. (a) Kneeling position (b) Head holder with mirror

Figure 3-10. (c) Legrest supports the patient if the bed needs to be tilted forward

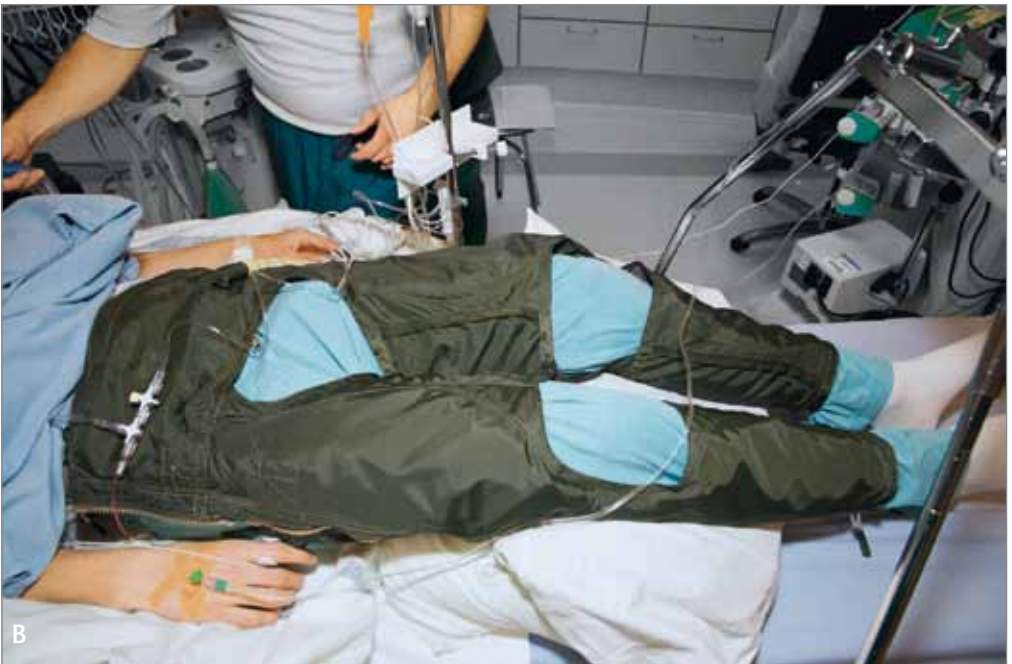
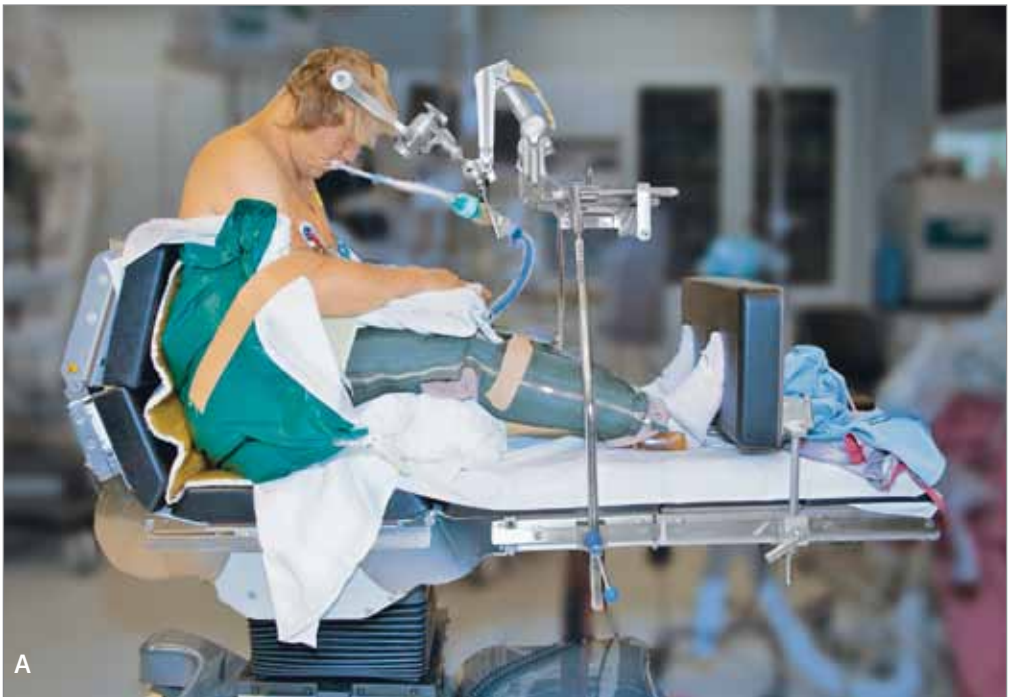
Figure 3-10. (a) Sitting position for infratentorial supracerebellar and fourth ventricle approaches. (b) G-suit trousers.

addition, prone position has also been shown to increase functional residual capacity of the lungs.

Thoracic or lumbar spinal surgery is usually performed in prone (Figure 3-7) or kneeling position (Figure 3-9a). The head is placed on a head holder with a mirror enabling visualisation of eyes and endotracheal tube during anesthesia (Figure 3-9b). The rolls are employed to allow the chest and abdomen to move freely. Furthermore, careful placement of patient in prone position aims to avoid forehead or orbital compression (may result in retinal ischemia and blindness), and compression of axillae, breasts, iliac crests, groin vessels, penis and knees.

### 3.7.3. Sitting position

In Helsinki Neurosurgical Department, sitting position has been used in selected cases of posterior fossa surgery since the 1930's, and all vestibular schwannomas were operated on in an upright position since the early 1960's to the end of 1980's. Nowadays, lateral park bench position is used for these lesions. The current sitting position for infratentorial supracerebellar and midline fourth ventricle approaches is shown in Figure 3-10.

The general contraindications for the sitting position are severe congestive cardiac failure, uncontrolled hypertension, cerebral ischemia when upright and awake, extremes of age < 6 months or > 80 years, ventriculoatrial shunt, known open foramen ovale or right atrial pressure in excess of left atrial pressure.

Before the positioning starts, all the adult patients are fitted with G-suit trousers inflated with compressed air to the pressure of about 40 mmHg to decrease venous pooling in the lower extremities. In children, the same is

achieved with elastic bandages wrapped around the calfs and thighs. A bolus of intravenous Ringer's acetate or tetrastarch (colloid solution) is administered at the discretion of the anesthesiologist in charge. Mayfield head frame is attached to patient's head while still in the supine position.

In adults, the target MAP - measured at the level of foramen Monro - is 60 mmHg or higher, and/or systolic arterial pressure 100 mmHg or higher. The precordial Doppler ultrasonography probe is placed over the fifth intercostal space, just to the right of the sternum, to detect possible venous air embolism. The patients are normoventilated (target  $\text{PaCO}_2 = 4.4 - 5.0$  kPa) with 100% inspired oxygen without positive end-expiratory pressure, by volume controlled ventilation.  $\text{N}_2\text{O}$  is not given. Arterial blood gases are analyzed after the induction of anesthesia and thereafter as clinically needed. Upon suspicion of venous air embolism (a specific sound in the precordial Doppler, sudden drop in the  $\text{ETCO}_2$  of  $>0.3$  kPa ( $\approx 0.3\%$ )) without prior change in the ventilation or concomitant decrease in the arterial pressure, the neurosurgeon is immediately informed. In some cases, the jugular veins are gently compressed manually, to help the neurosurgeon to identify the site of air entry. The neurosurgeon closes the leak by first covering the site with compresses soaked in normal saline and then either applies wax into the bone sinuses or coagulates open veins with bipolar. We do not attempt to aspirate air from the right atrium. The operating table is tilted only on the occasion of hemodynamic collapse.

### 3.8. POSTOPERATIVE CARE IN THE ICU

One of the most important issues in the postoperative care of the neurosurgical patients is that information about the course of surgery and anesthesia is available to the ICU personnel when the patient arrives there. The neurosurgeon fills in a form before leaving the OR, stating the preoperative neurological condition and the expected postoperative findings (e.g. dilated pupil because of oculomotor nerve manipulation, or possible hemiparesis). This may help to avoid unnecessary radiological investigations. Any special requirements (exceptionally low or high blood pressure, early CT controls etc.) should also be made clear.

After uneventful craniotomy (unruptured aneurysm, small supratentorial tumors) the minimum length of stay in ICU is six hours, but preferably, and always in more complex cases, overnight surveillance is the norm. Glasgow Coma Score, pupillary size and reaction to light, and muscle strength are checked and recorded hourly.

Postoperative control of hemodynamics is of utmost importance in the ICU. Perioperative systemic hypertension and coagulation disorders are associated with postoperative hemorrhage. Routinely, the systolic arterial pressure is kept under 160 mmHg postoperatively. Large meningiomas and AVMs are exceptionally prone to postoperative bleeding, and these patients are

often kept sedated and relatively hypotensive for 3–4 hours or until the next morning. They are woken up only after postoperative CT, CTA and/or DSA imaging is found acceptable. Even then utmost care is taken to avoid sudden increases in blood pressure during emergence from sedation and extubation (Tables 3–6 and 3–7). Some of the common practices used in different types of surgical procedures are summarized in Table 3–8.

Nausea and pain are common after neurosurgical procedures, but the medications used should not be overly sedative or interfere with blood coagulation. For pain relief oxycodone (an opioid closely resembling morphine in dosage and effects) is given in small (2–3 mg i.v.) increments to avoid respiratory depression and excess sedation. At the ordinary ward intramuscular or oral oxycodone is given as needed. Paracetamol (acetaminophen) is also administered (initially intravenously, later orally). Non-steroidal anti-inflammatory drugs (NSAID's) are not given on the first postoperative day because of their inhibitory effect on platelet aggregation. Rarely, in patients without cardiovascular disease or no history of vascular surgery, parecoxib (COX-2 inhibitor) 40 mg i.v. may be given as a single dose. Nausea and vomiting are treated with 5-HT<sub>3</sub>-receptor antagonists (granisetron 1 mg i.v.) or small doses of droperidol (0.5 mg i.v.).

*Table 3–6. Hemodynamic control during extubation in NICU*

- Clonidine 150 µg/NaCl 0.9% 100 ml 30 min infusion (or dexmedetomidine-infusion)
- Stop sedation (usually propofol-infusion)
- Labetalol 10–20 mg and/or hydralazine 6.25 mg i.v. increments as needed
- Extubation when patient obeys simple commands

*Table 3–7. Indications for postoperative sedation and controlled ventilation*

- Pre-op unconscious or decreased level of consciousness
- Long duration of temporary clipping
- Expected lower cranial nerve dysfunction or palsy
- Easily bleeding operative field
- Large AVM: blood pressure control
- Brain swelling

Table 3-8. Common practices at Helsinki NICU

**Supratentorial surgery (tumors, unruptured aneurysms)**

- Early awakening and extubation in OR
- Systolic arterial pressure <160 mmHg
- In selected cases (large tumors, complex aneurysms): post-op sedation and tight hemodynamic control (usually systolic arterial pressure 120–130 mmHg for 3–4 hours), control CT and delayed extubation

**Infratentorial surgery***Small tumors in "benign" locations or microvascular decompression of trigeminal nerve*

- Early awakening and extubation in OR
- Systolic arterial pressure <160 mmHg

*Large tumors or tumors in delicate location (pons, medulla, close to IX–XI nerves)*

- Post-op sedation and tight hemodynamic control (usually systolic arterial pressure 120–130 mmHg for 2–4 hours), control CT and delayed extubation
- Pharyngeal function always checked with extubation → tracheostomy in case of IX–XI cranial nerve dysfunction

**AVMs***Small AVMs*

- Early awakening and extubation in OR, normotension (systolic arterial pressure <160 mmHg)

*Medium sized AVMs or problems with hemostasis during surgery*

- Sedation until control CT + CTA/DSA
- Tight hemodynamic control (usually systolic arterial pressure <120–130 mmHg)

*Large AVMs*

- Sedation until control CT + CTA/DSA
- Extremely tight hemodynamic control (systolic arterial pressure 90–110 mmHg)
- Slow emergence and extubation (see Table 3-6)
- Systolic arterial pressure target allowed to rise by 10 mmHg daily (up to <150 mmHg), antihypertensive medication for 1–2 weeks post-op
- Fluid restriction to minimize cerebral edema

**Ruptured aneurysms**

- Early awakening and extubation in OR only in H&H 1–2 patients with uneventful surgery

*H&H 1–2; Fisher 1–2*

- Systolic arterial pressure >120 mmHg
- Normovolemia, Ringer 2500–3000 ml/day
- Nimodipine 60 mg x 6 p.o.

*H&H 1–3; Fisher 3–4*

- Systolic arterial pressure >140 mmHg
- Normovolemia, CVP 5–10 mmHg, Ringer 3000–4000 ml/day
- Nimodipine 60 mg x 6 p.o.

*H&H 4–5; Fisher 3–4*

- Systolic arterial pressure >150–160 mmHg
- Slight hypervolemia, CVP 6–12 mmHg, Ringer 3000–4000 ml/day + colloid 500–1000 ml/day
- Nimodipine 60 mg x 6 p.o.

**Bypass surgery**

- Early awakening and extubation in OR if the length of operation <3–4 h
- Normotension, systolic arterial pressure 120–160 mmHg
- Avoid vasoconstriction, liberal fluid therapy
- Antiplatelet therapy with acetylsalicylic acid (300 mg i.v. or 100 mg p.o.) in most cases

*CVP, central venous pressure; H&H, Hunt and Hess grading scale; i.v., intravenous; p.o., peroral.*



According to our follow-up during the years 2009–2010, pain scores (scale 0–10) after supratentorial craniotomy are low (median 2–3). However, the need for postoperative analgesia may differ depending on the type of surgery and pathology. Also depression and disease-related confusion may obscure the actual need for analgesia. Postoperative pain is treated by intravenous patient-controlled analgesia (PCA) with oxycodone in patients undergoing major spinal surgery. Postcraniotomy pain is seldom treated by PCA in our clinic.

### 3.9. SPECIAL SITUATIONS

#### 3.9.1. Temporary clipping in aneurysm surgery

Depending on the duration of the temporary occlusion of a cerebral artery, protective measures are needed. When the expected duration is less than 60 to 120 seconds, there is no need for interventions, but if the duration is likely to be longer, the following interventions are made before the placement of a temporary clip:

- (a) The inspiratory concentration of oxygen is increased to 100%.
- (b) Barbiturate (thiopental) is administered as an intravenous bolus (3–5 mg/kg) to reduce brain metabolism and oxygen consumption. A second, smaller dose of thiopental, may be administered prior to reocclusion of the same artery, if reperfusion is provided before that.
- (c) Phenylephrine in 0.025 to 0.1 mg increments is given in case of hypotension.
- (d) Additional doses of phenylephrine may be given to increase the arterial blood pressure at least 20% above baseline to ensure retrograde circulation to the areas distal to the temporary clip, if a temporary occlusion exceeding 5–10 min is planned. Sometimes this may induce cumbersome bleeding at the operative area, prolonging and making the temporary clip adjustment and removal even more difficult.

Postoperative controlled ventilation and sedation are often considered necessary when the duration of temporary clipping exceeds 5 to 10 minutes.

### 3.9.2. Adenosine and short cardiac arrest

In the literature, there are many descriptions of the use of adenosine to induce circulatory arrest during cardiac and brain surgery. Adenosine is an antiarrhythmic drug that effects the sinoatrial conduction, and is normally used for treatment of tachyarrhythmias. We have used a short cardiac arrest or significant drop in blood pressure induced by adenosine either to control bleeding from a ruptured aneurysm or in complex unruptured aneurysms to allow proper clip placement. To induce cardiac arrest, 0.4 mg/kg of adenosine, followed by 10 ml of normal saline, is injected as a rapid bolus in an antecubital vein. This induces an approximately 10-second arrest. During this short period, the operative field is cleared by suction, and a temporary clip(s) or a so-called pilot clip is applied in place. Normal cardiac rhythm returns usually without any need for medical intervention. If adenosine use is anticipated preoperatively, cardiac pads are placed on the chest of the patient in case of need for cardioversion or cardiac pacing. Cardioversion or temporary cardiac pacing has not been needed so far to treat a tachyarrhythmia or bradyarrhythmia. In more than 40 cases in which we have used adenosine intraoperatively, there have been no significant adverse reactions (arrhythmia, arrest or long-lasting hypotension) associated with its use. The cardiovascular effects of adenosine are usually completely worn off in less than one minute. If clinically indicated, the bolus dose of adenosine may be administered repeatedly.

### 3.9.3. Intraoperative neurophysiologic monitoring

The choice of anesthetic agents depends on the mode of neurophysiologic monitoring. Anesthetic agents may prolong the latencies of evoked potentials and also decrease the amplitudes in a drug-specific manner, inhaled anesthetics causing more interference than intravenous anesthetics. Importantly, whatever anesthetic combination is chosen, the depth of anesthesia should be kept stable. Hypothermia suppresses evoked potentials, thus core temperature is continuously monitored, and normothermia is maintained with external warming. Of the evoked potentials, brainstem auditory evoked potentials (BAEP) are rather resistant to anesthesia, but when cortical evoked potentials are measured, intravenous anesthesia with propofol and fentanyl (or remifentanyl) is preferred (Table 3-9). Dexmedetomidine, an alpha-2-adrenoceptor agonist, is a feasible choice in patients when neither propofol nor inhaled anesthetics are allowed. In cases with motor evoked potential (MEP) monitoring or direct cortical stimulation, muscle relaxants are not given.

Anesthetic agents have characteristic effects on the EEG. To ensure intraoperative corticography of satisfactory quality during epilepsy surgery, anesthesia is maintained either with isoflurane or propofol, which are discontinued well before monitoring periods. Propofol may be inferior to isoflurane, because of the reported induction of generalized electrical activity. During the monitoring periods, anesthesia is maintained with dexmedetomidine and remifentanyl or fentanyl. In individual cases, droperidol may be given to deepen the anesthesia.

### 3.9.4. Antithrombotic drugs and thromboembolism

The patients scheduled for neurosurgery in Helsinki have a 5-day cessation of all antithrombotic drugs to allow spontaneous recovery of the coagulation capacity with certain exceptions (see below). Modified low molecular weight heparin (LMWH) (enoxaparin) bridging therapy is started as compensatory thromboprophylaxis preoperatively, and continued postoperatively, in patients with high risk for thrombosis, such as mechanical mitral or tricuspidal valve, atrial fibrillation with thromboembolism, history of deep venous thrombosis, thrombophilia or coronary artery stent. In emergency cases, the effects of anticoagulants or platelet inhibitors are counteracted by specific antidotes or transfusion of fresh frozen plasma or platelet concentrates.

The normal (<1.5) INR is achieved usually in four days after cessation of warfarin. Prothrombin complex concentrate is administered when the effect of warfarin has to be reversed without delay. The dosage regimen is based on INR values before and after the administration of prothrombin complex concentrate. Vitamin K (2–5 mg orally or i.v.) is administered simultaneously. Importantly, it may be indicated to administer the dose of prothrombin complex concentrate repeatedly to guarantee postoperative hemostasis since the half-life of coagulation factor VII is 4–6 hours.

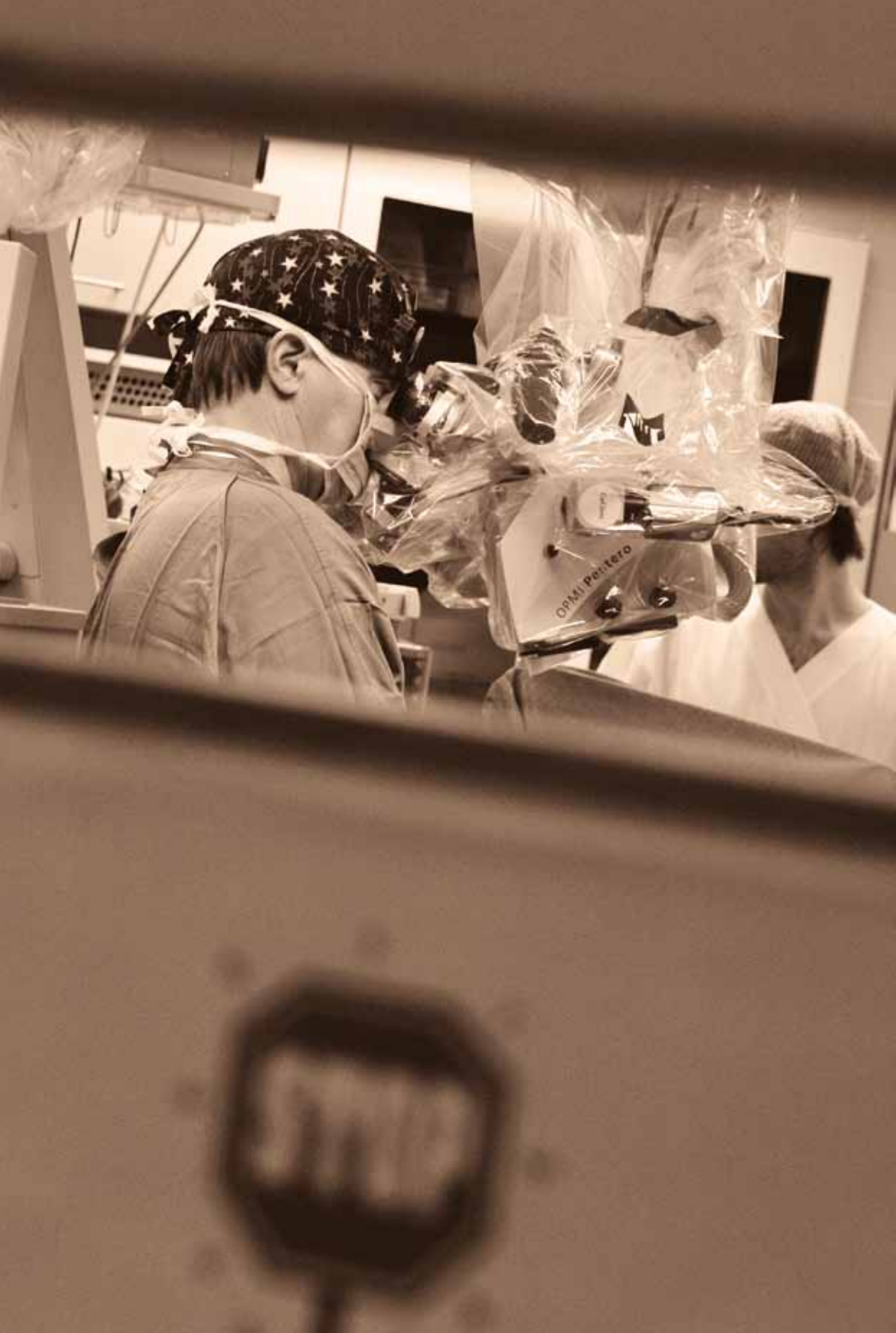The effect of low dose acetylsalicylic acid and clopidogrel on platelets lasts up to 7 days. However, adequate platelet function for neurosurgery may be achieved in 2–4 days after the interruption of low dose acetylsalicylic acid or clopidogrel. The elimination of low dose acetylsalicylic acid or clopidogrel from plasma takes 1–2 days, and new platelets are produced approximately  $50 \times 10^9/l/day$ , which might be sufficient for normal hemostasis during neurosurgery. In patients with recent coronary artery stenting, myocardial infarction, unstable angina pectoris or in cerebral bypass surgery, craniotomy is performed without interruption of acetylsalicylic acid. However, if clopidogrel is combined with acetylsalicylic acid, clopidogrel is interrupted 5 days before craniotomy.

All craniotomy patients have compression stockings for prophylaxis of venous thromboembolism. In selected high-risk patients and in patients on LMWH bridging therapy, a mechanical arteriovenous pulsation device for feet is applied and a low dose of enoxaparin (20 mg once or twice daily s.c.) is administered not earlier than 24 hours after craniotomy or CNS surgery if there are no signs of bleeding on control CT scan.

Table 3-9. Anesthesia during neurophysiologic monitoring

Measurement	Anesthetic agents
BAEP	propofol + opioid (fentanyl or remifentanyl)
SEP	propofol + opioid (fentanyl or remifentanyl) + dexmedetomidine + muscle relaxant
MEP	same as SEP but no muscle relaxant
Corticography	opioid (fentanyl or remifentanyl) + dexmedetomidine

BAEP, brainstem auditory evoked potentials; SEP, sensory evoked potentials; MEP, motor evoked potentials.



## 4. PRINCIPLES OF HELSINKI MICRONEUROSURGERY

### 4.1. GENERAL PHILOSOPHY

The style of a surgeon is the image of his or her mind. When you travel and see different surgeons at work, you notice that there are many different styles of microneurosurgery. These styles and habits have been formed by influences by mentors & trainers, their area of interest (e.g. bypass, skull base) as well as their individual character. Some sit, while others stand. Some are faster and some are slower, some take a break while others do not, some like music in the OR and some prefer silence. Some use bipolar dissection and others prefer using microdissectors. And all have their reasons for what they do: training, experience, and resources of both the department and the society. As long as the results are good and excellent, that is what matters. Sometimes there is no wrong or right way. Just your way and my way!

What matters is how the operation is developing, progressing, and the final outcome. Here are a few brief points about the techniques of Helsinki way of microneurosurgery. This style of surgery, the pace, the results and the team is the reason why so many come to see, and they see so much in a short space of time. Because of the fluency of technique the operations are interesting and at a pace that can be easily followed. The fellows that have the opportunity to edit the operative videos know that to edit the operations is difficult. Because there is very little to edit out as there is little time of non-action!

One of the key factors in Helsinki neurosurgery is planning and mental image of the task ahead. Each movement is pre-calculated, there is very little time spent wondering what to do next. A great part of the operation has been planned already prior to the incision, and there is no

lethargy in the approach. The actual physical surgery is often the second or third attempt, since through mental preparation the neurosurgeon had performed the operation in his or her mind already once or twice before stepping into the OR. The other important factor is that every movement and task is aimed to fulfill the actual goal of the surgery. This means avoidance of large and time consuming approaches and techniques when the same result can be obtained with less hazard using a smaller approach. Every step during surgery is simplified as much as possible. It is go-go surgery! There is much work to be done and there is no time for long and laborious approaches when there is an easier and faster way to achieve the same result. Each procedure is divided into several steps or phases, each of which should be completed before moving forward. In this way one is prepared even for unexpected situations and maintains control over the task ahead. The general philosophy of Helsinki microneurosurgery can be simplified into: "simple, clean, fast, and preserving normal anatomy."

## 4.2. PRINCIPLES OF MICRONEUROSURGERY

Since the advent of true microneurosurgical techniques introduced by Prof. Yaşargil, there have been many techniques, instruments and technological advances introduced into this field. The introduction and application of microsurgery in neurosurgery was a result of long and hard development of the basic techniques by Prof. Yaşargil in the laboratory of Prof. Donaghy in Vermont, USA between 1965-1966. These techniques were later developed further, refined and consolidated over the next 25-year period in Zürich.

Microneurosurgery is not macroneurosurgery using a microscope. Rather, it is a combination of a special armamentarium consisting of the microscope, the microsurgical tools, and the choice and command of microsurgical techniques. The choice and command of technique can only be mastered with continuous practice. This exercise should include both laboratory training as well as the work in the operating room. It will enhance the use of senses such as depth perception, sensory feedback and even sense of joint position, all of which are necessary for microneurosurgery.

The use of high magnification, powerful light source and stereoscopic vision allows the neurosurgeon to use suitable delicate tools to operate on central nervous system lesions in an almost bloodless field as atraumatically as possible. The microscope allows visualization and 3D appreciation of the relevant and detailed neuroanatomical structures. But to achieve the optimal visualization of each structure, detailed knowledge of the microanatomy, careful preparation and execution of a given approach is necessary. There are many small details, some of them trivial, which affect the outcome of a particular surgery. Here we try to summarize what we have learned over the past years about microneurosurgery and the instrumentation we find useful.

### 4.3. OPERATING ROOM SETUP

#### 4.3.1. Technical setup

There should be always a consistency where possible regarding the setup in the OR (Figure 4-1). All OR personnel should have optimal access to the patient and all the equipment they require. There are two main issues which have to be taken into consideration: (1) the surgeon's optimal position with respect to the operation field, so as to allow relaxed posture and optimal visualization of all the necessary structures; and (2) the anesthesiologist's good access to the patient's airways and all the necessary i.v. routes. In addition several other key factors need to be considered:

- Anticipation for the amount of room needed for the surgeon to move.
- Position and flexibility of the microscope.
- Unhampered access between the scrub nurse and surgeon to allow seamless exchange of instruments. In case of a right-handed surgeon the majority of instruments are passed to the right hand.
- Provision of room and access to the microscope for any required assistants.
- Sufficient room and access for anesthesia, and easy communication when necessary regarding e.g. change of table height and etc.

Generally an attitude of utmost respect and consideration for all the OR staff and team is the Helsinki way, the team spirit of Helsinki.

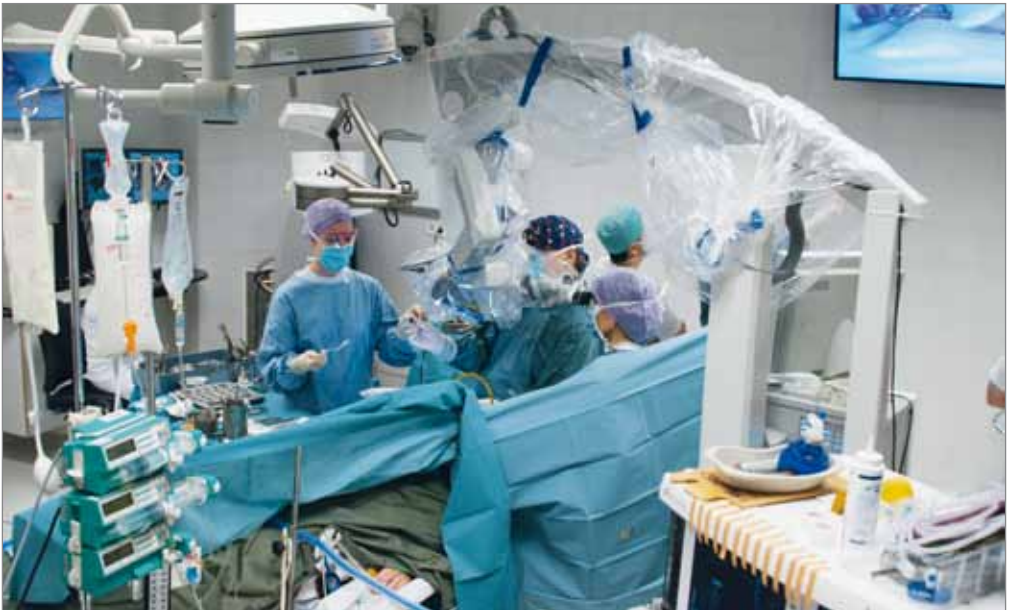
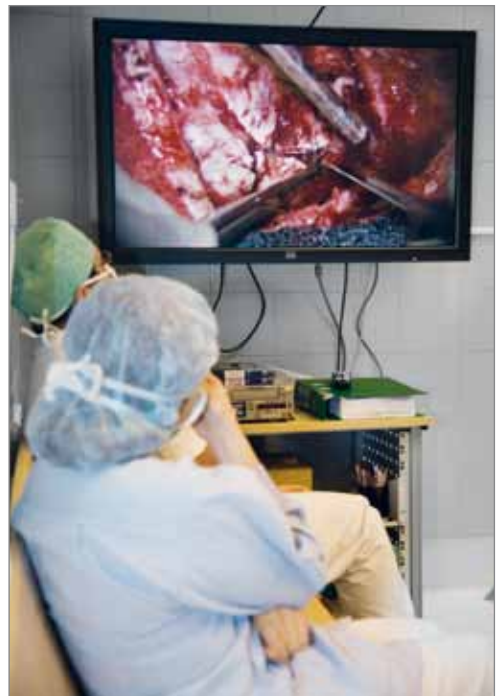
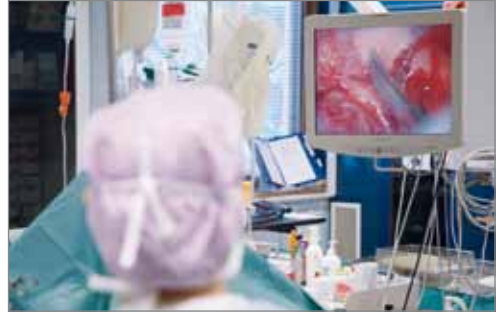Figure 4-1. The general setup of OR 1, Prof. Hernesniemi's OR, in Töölö Hospital

### 4.3.2. Displays

Microneurosurgery is a team effort. This means that all the personnel inside the OR need to be aware of what is happening in the operation field. With modern microscopes equipped with high quality video cameras this can be easily achieved. Monitors showing real time microsurgery to the anesthesiologist, the operating room nurses, and the technicians are essential and enhance teamwork and co-ordination. The progress of the operations, moments of crucial dissection or intervention, and timing for use of bipolar coagulation are essential reasons for such audiovisual equipment. The most important display is the one used by the scrub nurse. For her to be able to anticipate the surgeon's next step, she has to have an unobstructed and direct view on the monitor, which is placed preferably directly in front of her. A second monitor for anesthesia is very useful as well. Additional displays can be then placed for assistants and visitors. Live or real-time teaching of a large number of residents and visitors is made possible by video monitors. Recording facilities for still photos and videos can be used for teaching and lecturing purposes, as well as documentation. The emerging high definition (HD) and 3D microscope cameras can provide even better possibilities for "learning by watching".



*Figure 4-2. Several displays in the OR provide the whole team to observe the surgical field as seen through the microscope. (a) The scrub nurse's display. (b) The visitors' display*



## 4.4. POSITIONING AND HEAD FIXATION

### 4.4.1. Operating table

The operating table is selected according to personal preferences and financial resources. It should provide stable positioning, and it should also be equipped with a quick and reliable mechanism for the staff to make swift positional changes during surgery, according to the operating surgeon's wishes. Modern, mobile tables allow adjustment of each segment of the table separately using remote control that is handled during surgery by the anesthesiological nurse. Flat tables with very limited possibility to tilt or bend some parts of the table are not well suited for modern microneurosurgery.

- The head and body of the patient should be so secured as to allow safe tilting and rotation of the table to change the angle of view and surgical access.
- The protection of the eyes, nose, ears, skin, extremities, vulnerable nerves and compression points are paramount. The eyes are routinely covered with chloramphenicol eye ointment to protect the eyes and keep them shut. Some patients may be allergic to this antibiotic.
- The pressure areas are protected with pads and cushions.

### 4.4.2. Patient positioning

During positioning, comfortable and practical working positions should be agreed on by the neurosurgeon and the scrub nurse, with maximal mobility for the operating neurosurgeon. The following principles are of prime importance for comfortable conduct of surgery:

- For all craniotomies the head of the patient should be elevated approximately 20 cm above the level of the heart. This facilitates a clean and bloodless field with good venous outflow.
- The head is positioned so as to have some help from the gravity to facilitate the appropriate part of the brain to fall away, and increase view and access.
- Venous outflow should not be compromised by heavy tilting or turning of the head or by any constrictions at the neck.
- A comfortable working angle – usually downward and somewhat forward – should be ensured by careful positioning of the patient's head and body.

The positions of the patient include supine, prone, semi-sitting, sitting, and lateral ("park bench"). From the above principles, the ones on (a) the use of gravity and (b) the comfortable working angle, dictate the best position of the head. The body is then positioned accordingly. However, every case is unique, and we always tailor the position according to the lesion and the patient's body and condition. Specific positionings for the most important approaches are discussed in detail in Chapter 5.

#### 4.4.3 Neurosurgeon's position and movement

The working posture is standing or sitting. We prefer the standing position because it allows much better mobility around the craniotomy site, use of all available exposure, and immediate change of position, losing no time in moving the chair or the operation table. Many small things, when taken together, often save invaluable OR time by tens of minutes, even hours. The patient is perfectly still, but the neurosurgeon adjusts his or her position almost constantly, using the mouthpiece to focus and move the operation microscope laterally and vertically. Visual access to the entire operative field may also require lifting or lowering the table – this should be a swift routine during surgery. The neurosurgeon may also adjust height by 3 to 4 cm by high-heeled clogs (by wearing them or not) – platforms are seldom necessary. Sitting might be more comfortable but reduces mobility. Sitting is preferable in certain instances, for example, during bypass operations when the operative area is very small and the angle of vision does not have to be changed. Standing position does not affect the stability of the hands compared to the sitting position if a proper armrest is used (Figure 4-3).

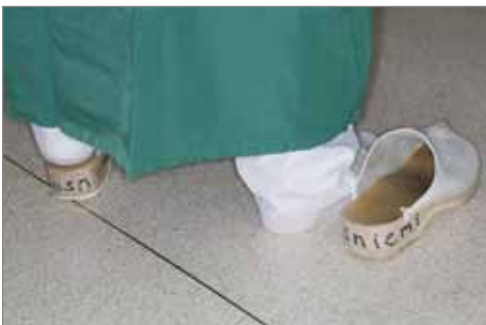

Figure 4-4. High-heeled clogs may be worn and removed as desired to fine-tune the surgeon's height

The advantages of standing to operate are:

- Allows greater range of movements for the surgeon to maneuver and facilitate surgical access, especially when using the mouthpiece on the microscope. This can be even slightly augmented by wearing or removing surgical clogs to alter the surgeon's height (Figure 4-4).
- Changing and switching positions is faster.
- It is easier and more accommodating for the assistant.
- Due to increased use of proprioception, the surgeon is consequently more aware of his position in relation to his surroundings.

The greatest disadvantage of standing to operate is that it can be more tiring if one is not in a good physical condition (Figure 4-5).

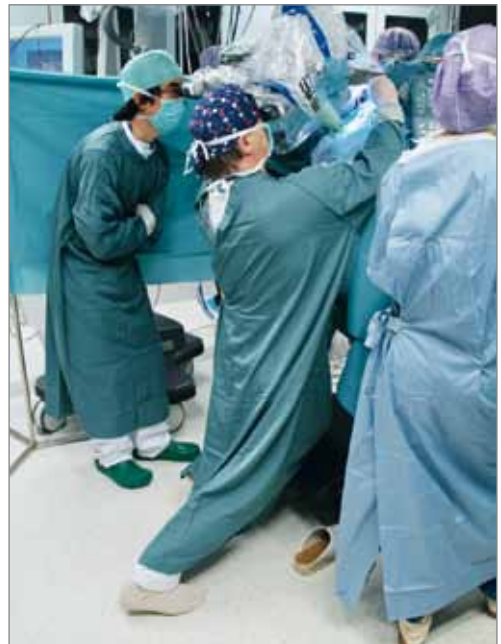

Figure 4-5. Standing position allows freedom of movement – even acrobatics!

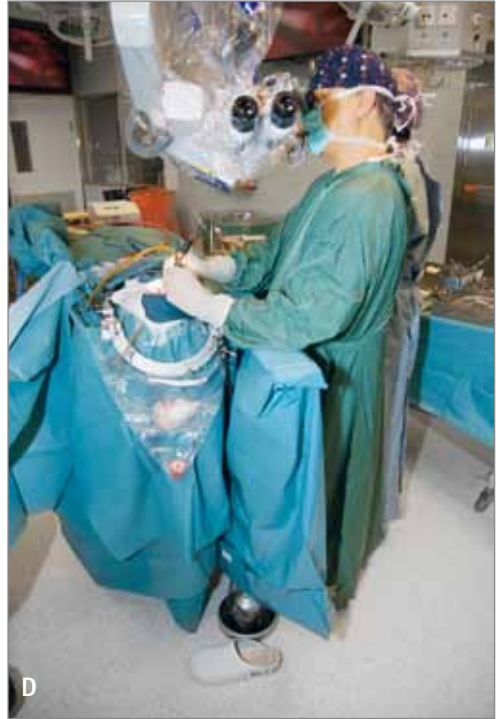
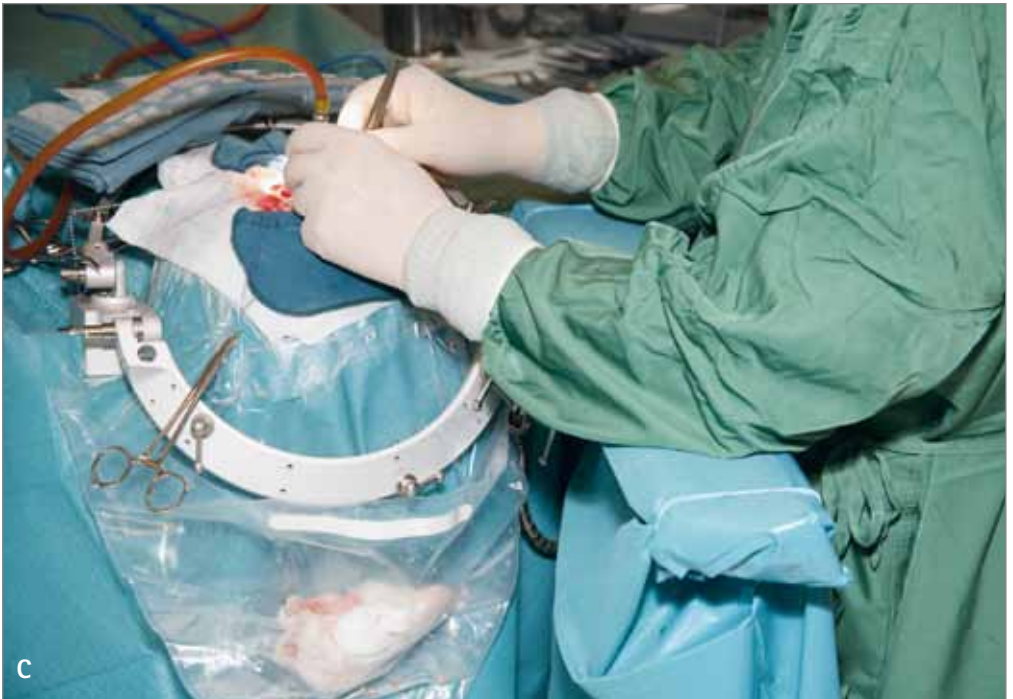
Figure 4-3. (a) Armrest with adjustable height and ball-and-socket joint at the base. (b) Armrest with sterile covering. (c, d) Properly adjusted armrest allows the arms to rest at neutral and relaxed position, while providing stability comparable to sitting position



#### 4.4.4. Head fixation

In Helsinki style microneurosurgery, head fixation is used in all cranial procedures as well as in all posterior and lateral approaches to the cervical spine. The Sugita head fixation device, used in Helsinki since 1980's after Prof. Sugita's visit in 1979, has a good skin and muscle retraction system. It includes also an attachment system for brain retractors, which makes it the preferred head fixation device in Helsinki. The Mayfield-Kees 3-pin head frame with one more joint is more flexible. We use the Mayfield-Kees head fixation device in the sitting position and rarely in park-bench position (only for Janetta operation) when linear skin incisions are used. The Sugita device is preferred when heavy retraction of the skin flap or retractors to support the brain are needed. We do not like any instruments or retractors constantly fixed immediately above the craniotomy, as they may be accidentally displaced and cause serious injuries. Pin fixation sites of the frames, as well as the arch and the counter arch of the Sugita frame, should allow total access to the operative field and not prevent free movements of the neurosurgeon's hands or instruments or the operating microscope. Arterial and venous flow in the neck should not be compromised by head positioning, and we fix the endotracheal tube

by adhesives instead of a string/ribbon around the neck. The head should not be turned too much, the cervical spine flexed or extended to an extreme in any direction, and the trachea overstretched or twisted. In temporal, parietal, and lateral occipital approaches, the park-bench position helps to avoid compression of the jugular veins. After head fixation, further adjustments of the patient's position should be performed 'en bloc' by moving the operation table.

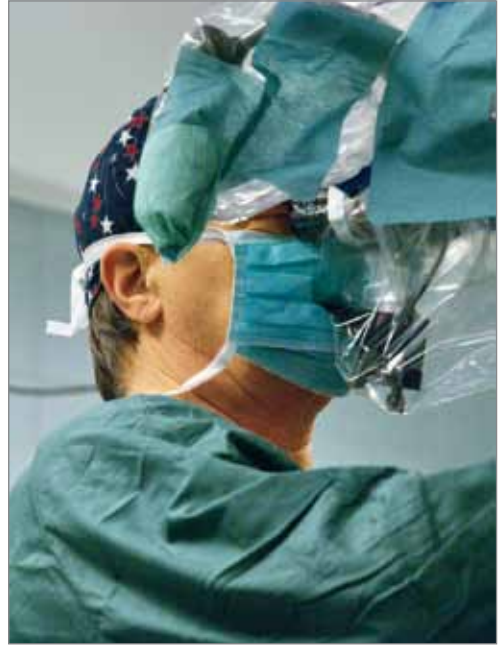## 4.5. NECESSARY OR USEFUL TOOLS

Every neurosurgical style has its own specific demands. Here we list the most important tools, some of which are necessary, some very useful adjuncts of Helsinki style microneurosurgery.

### 4.5.1. Operating microscope

A highly mobile operating microscope is the most essential tool of modern microneurosurgery. High magnification, powerful illumination, and stereoscopic vision constitute the primary assets of the operating microscope. Variable magnifications are achieved using an adjustable zoom system. A surgical field can be viewed at great depth, in sharp focus and stereoscopically. This is essential and facilitates operation at great depth and without a fixed retraction system. Mirrors or endoscopes can be used to see structures hidden from view of the microscope. The counterweight-balanced microscope was designed by Yaşargil, and copied by many manufacturers. This creates an essentially weightless suspension of the microscope optics.

A mouth switch (Figure 4-6) permits translational movement in the 3 planes: left & right, backwards & forwards, and up & down. This feature is very useful for focusing and for minor adjustments of position. With the mouth switch, the surgery becomes more efficient and some 30% faster. It avoids the repetitive use of the hands to make fine adjustments to the position of the microscope, and facilitates fluency of microneurosurgery. Although the use of mouth switch is initially demanding to learn, once you use it you do not ever want to be without it anymore. Insulated electrical heating cables around the oculars prevent fogging of the oculars — a truly helpful device brought to Helsinki by Prof. Yaşargil. For the mouth-switch, two surgical masks are placed on each other before gently biting on the mouth switch.



*Figure 4-6. Mouthpiece permits the movement of a balanced microscope in 3 planes while allowing both hands to use microinstruments continuously in the operative field.*

Two masks are used to prevent saliva from soaking through the mask. Initially, the production of saliva is quite high and uncomfortable in the same way as if learning how to play a clarinet or a saxophone. With the passage of time and familiarity with the system the production of saliva decreases dramatically making for a much more enjoyable surgical experience. But we still usually use double masks.

The microscope is frequently used for all the stages of the operation from the dural opening, until the last stitch of the skin. During the common lateral supraorbital (LSO) craniotomy, interhemispheric approach or retrosigmoid approach, it is mostly used after the placement of the last dural hitch suture and for all the intradural work. In some of the more extensive

approaches such as the presigmoid or the lateral approach to the foramen magnum, already some steps of the craniotomy are performed under the microscope. Modern training should enable the neurosurgeon to work easily and effortlessly through the operating microscope. For those in training, closing the wound under the microscope is one of the most important ways of learning. The development of hand-eye co-ordination, execution of fine movements under high magnification, blind adjustments for focus or zoom with one hand, gentle mouth adjustments for position and focus, and adaptation to stereoscopic vision (having depth perception) under powerful lighting demands regular exercise.

*T&T (Tricks and Tips from Prof. Hernesniemi)*  
Train with a microscope in laboratory and by closing the wounds. Learn to use the microscope as if it was a part of your body.

Several supporting features can be added to the present microscopes such as the image guidance or the fluorescence-based angiography and resection control. These useful but costly additions also require special technical skills in the OR to adjust and maintain the machinery. The neurosurgeon should be familiar with the common types of mechanical and electrical failures of his or her preferred microscope. The present microscope used by Prof. Hernesniemi is Zeiss OPMI Pentero (Carl Zeiss AG, Oberkochen, Germany) equipped with mouth switch, ICG (indocyanine green angiography, see 4.5.7.) module and external Karl Storz H3-M HD camera (Karl Storz GmbH & Co. KG, Tuttlingen, Germany)

*T&T:*

*Know your microscope and some of its trivial failures. Service of the microscope is important. The light source should be exchanged regularly. Once the light source died during an intraoperative aneurysm rupture!*

A system for recording surgeries is essential in the process of learning. Many manufacturers have incorporated such possibility directly into their microscopes. The other option is to attach an external recording device such as a computer with image capture possibility or a digital recorder to the microscope. By watching one's own surgeries later on it is possible to identify unnecessary steps that slow the progress and erroneous habits leading to problems.

*T&T:*

*Always check the microscope for your personal settings before surgery. It takes at least 50 operations before you fully adapt to a new microscope.*

#### 4.5.2. Armrest

Prof. Yaşargil once said to a keen student questioning some principles: "If you ask me to sign your book, I rest my hand and the book so I can sign it nicely. I don't write in the air! To do microneurosurgery, it is better to rest your hands on something." The options generally are to either stand and rest the hands on an arm support or to sit in a chair with armrests.

The armrest can be improvised, like the edge of the bed in the sitting position, or the edges of a Sugita frame. Usually it is in the shape of a standing platform, which is spring loaded and has a ball and socket joint at its base. This allows the surgeon to manipulate its height and angle of tilt as illustrated (Figure 4-3 - page 75).

#### *T&T:*

*There are few surgeons who do well without an armrest. Prof. Peerless was one of them. With experience the need for armrest lessens, it may give only psychological support. This has been verified by me during some visiting surgeries in OR's lacking an armrest.*

#### 4.5.3. Bipolar and diathermia

Bipolar and monopolar cautery are nowadays essential devices in any kind of surgery. It is necessary to be well familiar with the settings of the particular bipolar device used. In Helsinki we use Malis bipolar system (Codman, Raynham, MA, USA) The settings are generally 50 for extracranial work, 30 for intracranial work, and in coagulation of small vessel or aneurysm reshaping as low as 20–25. In highly vascularized tumors the setting is usually 50 or more, up to 70, higher than for other intracranial work. Diathermia can be efficiently used to strip attachments of muscles from bone while doing hemostasis at the same time. It is especially helpful in posterior fossa approaches and posterior or lateral approaches to the cervical spine.

#### 4.5.4. High speed drill

The high speed drill allowing use of various drill heads at up to 100,000 RPM has been almost standard in all advanced neurosurgical units. It allows for a faster, cleaner craniotomy, requiring as few as one access burr hole. We prefer electric drills because they are light, easy to use, fast, safe, and independent of the pressurized air supply. At least in our experience, the pressurized air supply can easily vary in the hospital network. Earlier the pneumatic drills were stronger with more torque, but nowadays with the modern electric drills there is no real difference. High-speed drilling is performed under the operating microscope. The burr is moved with precision by the dominant hand while controlled by proprioception, vision, and the foot pedal. This interplay should be trained on cadaveric work in laboratory. Using both hands to hold the drill and stabilize it is not recommended as it is clumsy and easily leads to greater instability than expected. Instead, the left hand with suction is actually used to guide the drill into a proper position and the drill is stabilized by resting the right palm at the edge of the operative field. All coverings in the area are removed to prevent them from being caught by the drill and damaging surrounding structures by windmill action.

In Helsinki we usually use the Stryker electric drills (Stryker Corp., Kalamazoo, MI, USA) They are heavier than some other high-speed drills, but they are very powerful which suits well with the way how we use the drill. For every case there is the standard set used (Figure 4-7). First drill head (trephine) allows the placement of the burr hole, the second containing the footplate is used for the craniotomy. The third drill head is the same craniotomy blade as the second but the drill guard does not contain the footplate so that the drill bit can be used to thin down a bone ridge before it is lifted and cracked. The same drill bit is used to make small holes for tack-up sutures. The fourth drill bit is a cutting ball drill head which allows drilling and smoothing the edges of a craniotomy for access towards the base of the skull (as commonly in the lateral supraorbital craniotomy). The last drill head is a diamond drill head, which aids in "hot drilling". This is where the bone is drilled without irrigation, resulting in heating and cessation of all bleeding from the bony surface.



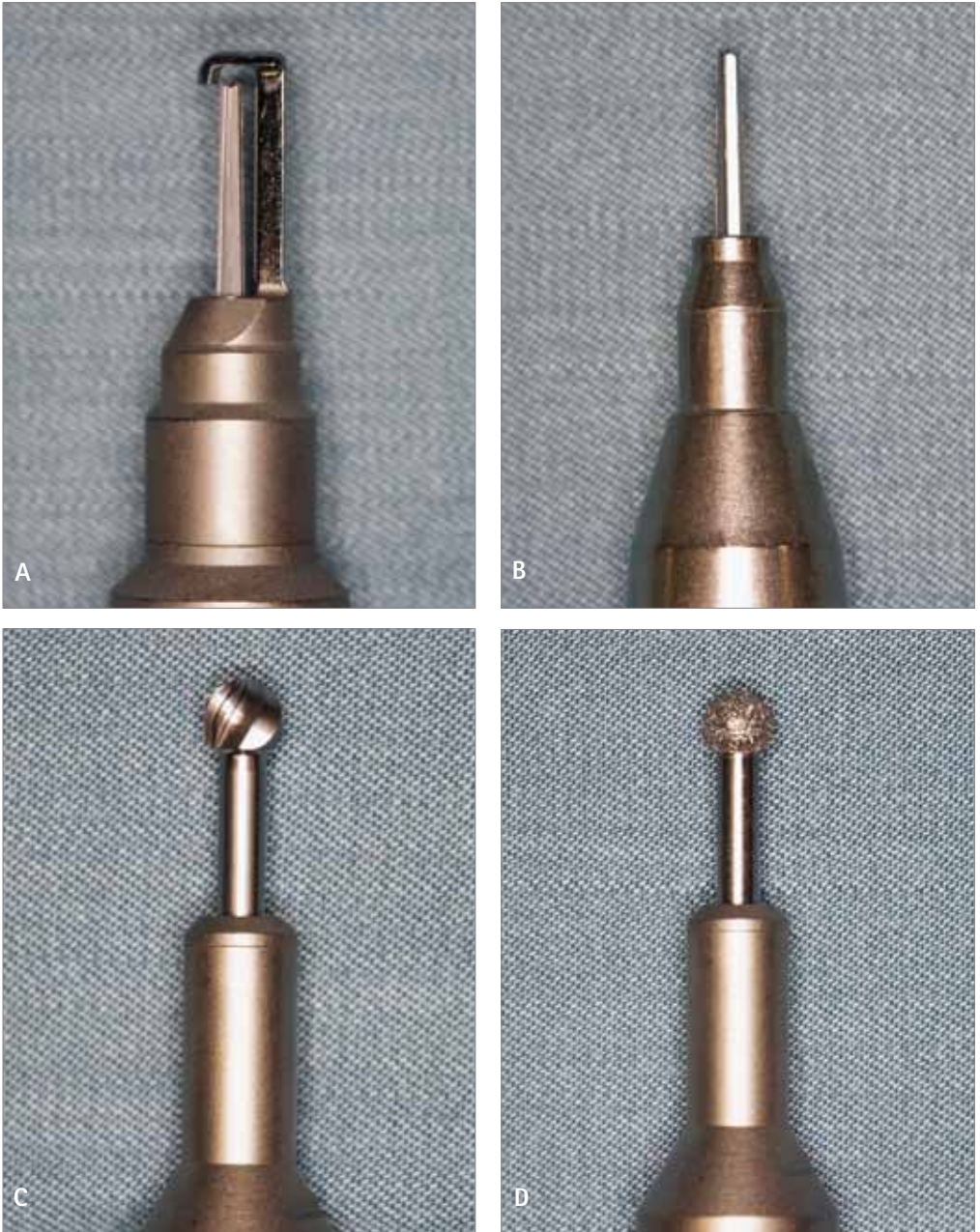


Figure 4-7. The standard drill tips used in Helsinki for craniotomy. (a) Craniotome blade with a footplate. (b) Same craniotome blade without a footplate, used for tack-up suture holes and thinning of bone near the skull base. (c) Cutting ball tip, 5.5 mm. (d) Diamond ball tip, 5.5 mm.

#### 4.5.5. Ultrasonic aspirator

The ultrasonic aspirator is made in different forms by different manufacturers. The one used in Helsinki is Stryker Sonopet (Stryker Corp., Kalamazoo, MI, USA). With a variety of oscillating heads it can be used on soft (tumor) or hard (bony) tissue, to focally and precisely destroy tissue and remove it. Soft tumors can be gently shaved down and excised from e.g. the fourth ventricle. Even more usefully, bone can be cut from the base of skull with precision and without the kicking and shaking associated with the high speed drill. There is no danger of catching nearby cottonoids as there is with a rotating drill head. This is very practical in tight areas surrounded with crucial structures, such as when removing the anterior or posterior clinoid process. The machine has variable settings for power, irrigation and suction, and makes bone removal at the base of skull much simpler and safer. But in the same way as with high-speed drill, laboratory training to get accustomed with the appropriate settings is mandatory.

#### 4.5.6. Fibrin glue

Fibrin glue is a tissue sealant which has been used widely for many years in different surgical disciplines including neurosurgery, cardiac, ENT, general surgery and even orthopedics. Prof. Hernesniemi started to use fibrin glue excessively during the 1980's. Fibrin glue simulates what happens in the physiological process of wound healing and closure. It has hemostatic properties and also can be used to close tissue defects such as the dura (augmented with Surgicel or muscle or other materials) as long as the area is dry and there is no significant pressure gradient or flow across the defect. It is a viscous liquid that settles and covers tissues well. It is a highly concentrated fibrinogen aprotinin solution (30 times the concentration of fibrinogen vs. human plasma; 75–115 mg/ml vs. 2–4 mg/ml in human plasma) that also contains factor XIII and a solution of thrombin and calcium chloride. The factor XIII causes the cross linking of fibrin. The type of fibrin glue used in Helsinki is Tisseel (Baxter, Deerfield, IL, USA).

In Helsinki, fibrin glue is widely used and comes in a ready-made form. This is stored in a freezer at a temperature of  $-10\text{ }^{\circ}\text{C}$ . It costs approximately 100 euros for each 2 ml package. The alternative available to most other countries is the unprepared 5 ml package that takes 20 minutes to prepare. This laborious preparation often discourages its use, and the ready-made preparation although expensive, has clear advantages.

Fibrin glue is used in Helsinki in the following places and situations:

- In the extradural space at the beginning of a craniotomy to prevent later epidural hemorrhage in the middle of an operation
- In the bony hemorrhage
- In sealing mastoid air cells
- In sealing small dural defects in the spine and cranium
- For its adhesive effect at times where a muscle or fat graft is used to seal a defect or reinforce a tissue wall or vessel
- In the cavernous sinus
- In skull base bleedings
- For closure of carotico-cavernous fistulae
- For tumor and AVM vessel embolization intraoperatively by direct injection
- To stop venous hemorrhage from small dural sinuses

Fibrin glue stops effectively bleeding from the region of the cavernous sinus or the tentorium with small injections into the intradural venous plexus. This does not appear to cause any significant or extensive thrombosis beyond the region of interest. The economic use of fibrin glue has clear advantages and benefits especially when trying to stop hemorrhage from the cavernous sinus during transcavernous approaches or extradural approaches to the base of skull. Although the fibrin glue is expensive, it saves operation time and need for blood products. By avoiding many hemorrhagic complications, its use pays more than well back.

#### 4.5.7. Indocyanine green angiography

Microscope integrated near-infrared indocyanine green video angiography (ICG) has been used effectively in Helsinki since 2005. This technology allows the assessment of the cerebral vasculature in the arterial and venous phase under the magnification of the microscope (Figure 4-8). On request, the anesthesiologist gives an intravenous injection of indocyanine green. A dose of 0.2 to 0.5 mg/kg is recommended. Subsequently the field of interest is illuminated with near-infrared light. Real time and dynamic angiographic images are then displayed and recorded. The images show the arterial, capillary and venous phase of flow in the area of interest. A playback facility is available if needed.

The technology is considered by some to be essential for high quality vascular surgery. In aneurysm surgery it allows the confirmation and recording of total exclusion of the aneurysm from the circulation. Also the parent artery, major branches and perforating vessels can be visualized. If any adjustment to the clip position is required for better exclusion of the aneurysm, and, more importantly, to restore flow in an occluded vessel or perforator, it can be done immediately. Its use is simple, practical and can be repeated.

Like all technology it is not 100% sensitive or specific. Caution is required when assessing flow remnant in a clipped thick-walled aneurysm. In such cases flow may not be seen through the thick wall, and the surgeon can be faced with an unpleasant situation if he or she punctures such an aneurysm which is still filling. The use of ICG can be adopted for analysis of flow in AVMs, and localization and analysis of anatomy in other vascular pathologies e.g. hemangioblastomas and cavernomas.

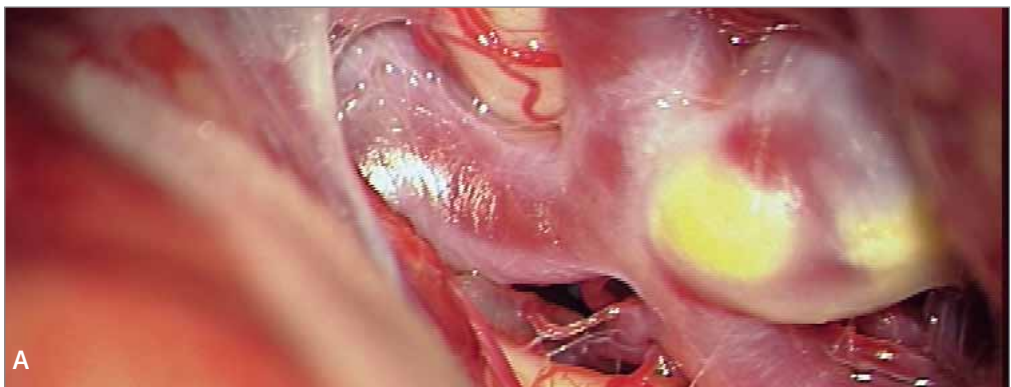

Figure 4-8. (a) Left MCA bifurcation aneurysm in visible light seen through the microscope.

#### 4.5.8. Microsurgical doppler and flowmeter

Doppler allows a qualitative measurement of blood flow in a cerebral vessel or even aneurysm. This is done via a hand held probe the tip of which can be placed on a small vessel or aneurysm to be studied. Flow can be detected and conveyed as a pulsating bruit type of sound. However, the interpretation of the findings may be difficult. Loss of pulsating sound can mean vessel occlusion, but it can also be just due to a poor probe contact or wrong angle with respect to the vessel. On the other hand, sound does not necessarily mean normal flow, it can be also caused by stagnating pulsation in arterial occlusion. There are more advanced types of flowmeters that measure the flow qualitatively. In Helsinki, we use them usually during bypass surgery. These flowmeters provide objective measurements of blood flow in terms of volume/time. However, their efficacy and use is very much operator dependent and requires more expertise in interpretation of the results. But still, micro-Doppler and flowprobes are yet another useful adjunct in the vascular neurosurgeon's armamentarium.



*(b) The same field seen with ICG. (c) The same view after perfect clipping of the aneurysm.*

#### 4.5.9. Neuronavigator

Neuronavigation is routine in many practices, and intraoperative imaging may become so in the future. However, it is important to study the preoperative images very carefully to identify landmarks such as the earlobes, coronal and lambdoid sutures,inion, sylvian fissure, central sulcus by inverted omega hand area, confluens sinuum, straight and transverse sinuses, etc. Neuronavigators may be out of order or too expensive for the institution. Quite frankly, to know neuroanatomy well is by far more important than to own and use a navigator. Careful measurements along the landmarks, the pathology, and the intended trajectory can usually be transferred to the scalp with acceptable accuracy. Many approaches, such as surgery for cerebral aneurysms and most extraparenchymal brain tumors, are so dense with anatomical landmarks that no neuronavigation is needed, just operative experience. That said, there are

certain pathologies, where the use of neuronavigation is of great help. These would be small, subcortical lesions, which are not close to any distinct anatomical landmarks, such as cavernomas and deep AVMs. Furthermore, in distal MCA and pericallosal aneurysms use of the navigator can be most helpful in finding the aneurysm. Also in parasagittal, falx and convexity meningiomas the neuronavigator may be of help in planning the craniotomy of appropriate size and location. But the neuronavigator should never be trusted blindly due to the effect of brain shift once the dura is opened and CSF released. For the neuronavigator to be used effectively one needs to be familiar with the setup, use it routinely and be well aware of the limitations of the system. Using the stereotactic frame can be an option if the neuronavigator is not available, but this is usually more cumbersome.

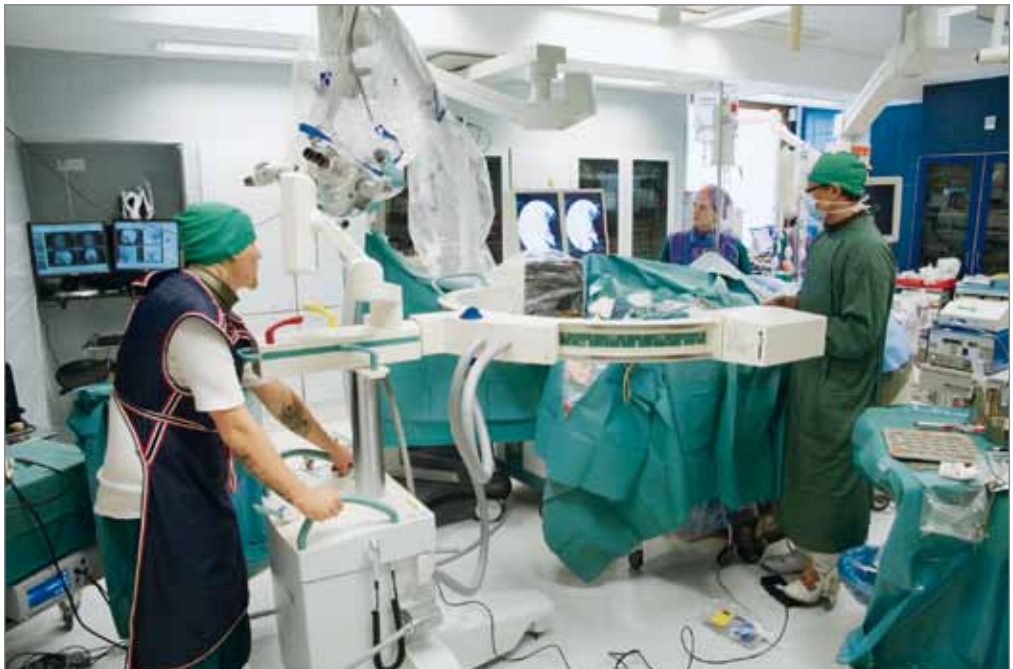

Figure 4-9. OR setup for intraoperative DSA; Dr. Riku Kivisaari performing the angiography.

#### 4.5.10. Intraoperative DSA

Although ICG has significantly lowered the frequency with which intraoperative DSA is being used, there are still special situations where it is very helpful. These include complex, heavily calcified, large or giant aneurysms, bypass surgery, AVM surgery or surgery for dural arteriovenous fistulas (DAVFs). To perform DSA intraoperatively in the OR one needs a C-arm with an option for performing subtraction angiography (Figure 4-9). This is nowadays standard in all modern C-arms. However, where the difficulty arises is the actual technical performance that requires excellent collaboration between the neurointerventionalist, OR technician manipulating the C-arm and anesthesiological nurse moving the operating table. Since most operating tables are radio-opaque, the patient's head is fixed in a radio-opaque frame and there is a lot of other hardware around, standard projections can be seldom achieved. Instead, one usually has to rely on only one or possibly two suboptimal projections. Reading such images requires a lot of experience from the neuroradiologist, especially due to the pressure of time and the surroundings in such a situation. But at the same time the information obtained can be very helpful in continuing, or finishing the surgery. Catheterization can be performed before the start of the surgery in the angio suite, which is technically easier but more time consuming. In this case, the catheter attached to irrigation pump is left in place for the duration of the procedure. We use this technique in clearcut situations when the need of intraoperative DSA is known already at the beginning of the surgery. We do not leave catheters in vertebral arteries, only in carotid arteries, since the risk of vessel wall damage and thromboembolic complications is much higher for vertebral arteries. The other option is to catheterize the patient during the surgery on the operating table, which is technically much more demanding especially if the patient is not in supine position, e.g. in lateral park bench position. We

have also tested radio-translucent head fixation frames made e.g. from carbon fibre. The problem with them, beside the high cost, was that they could not withstand normal everyday use and broke very easily.

*T&T:*

*You can navigate by experience, but even the best fail from time to time! Use navigation in all critical lesions, especially in subcortical ones.*

*T&T:*

*Intraoperative DSA should be used in all complex aneurysms and large AVMs. Intermittent balloon occlusion of ICA, with or without suction, has saved lives in large ICA aneurysms.*

## 4.6. MICROINSTRUMENTS

The microneurosurgical instruments either use a single shaft, such as suction or microdissectors, or two shafts, such as the bipolar forceps, microscissors or aneurysm clip applicators. The instruments are held like a pen; i.e. with the distal aspects of the fingers and thumbs. It is the fine movement from the distal joints that do most of the work. This way the movements, whether subtle or significant, are controlled and well regulated. The instruments are held using suitable points of grip along their shaft and the arms are rested using the adjustable T-shaped forearm support. The ulnar sides of the fingers are placed on the Sugita frame or the craniotomy edge for maximum stability. The array of microinstruments should allow this hand position by various lengths such as short, medium, long, and very long – more so with two-shaft instruments. To minimize physiologic tremor one should always try to use the shortest version of the instrument applicable to the particular situation. There should be clear visualization of the tips of the instruments. Often the first difficulty encountered for residents and those beginning training is how not to allow their hands to obstruct the visual working channel when looking through the microscope.

### *T&T:*

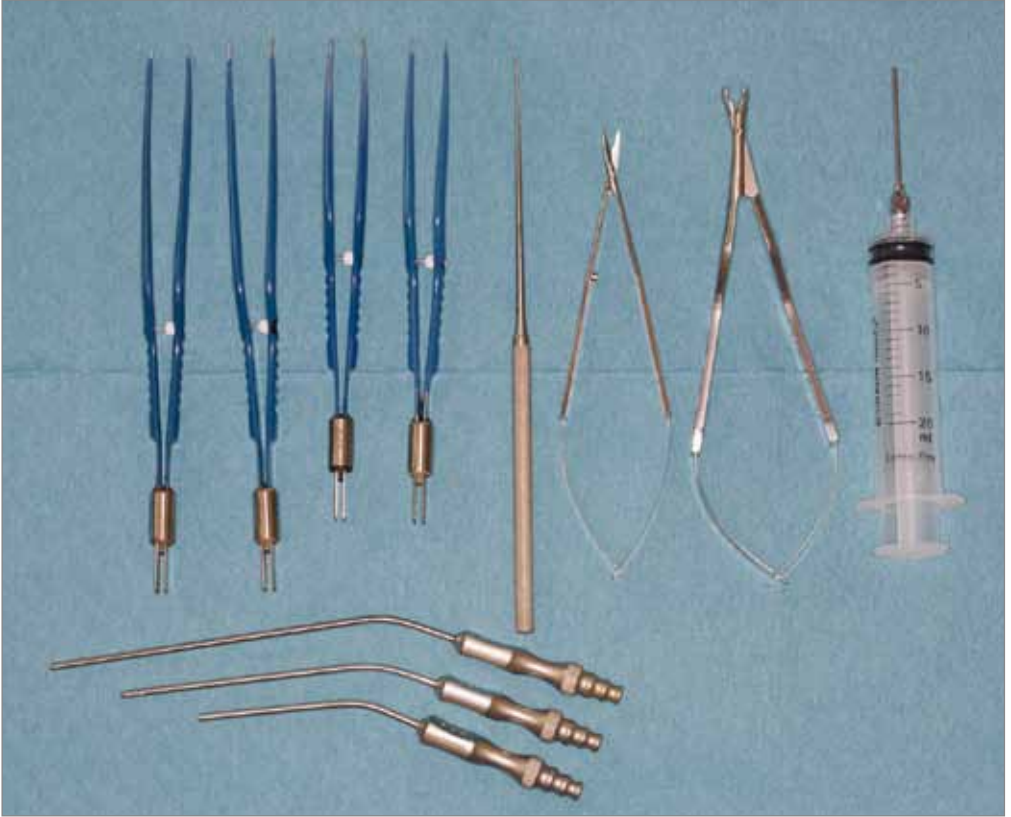
*Use appropriate instrument length, usually the shortest possible to maximize control and to minimize tremor.*

### *T&T:*

*Keep your hand/fingers in specific posture when asking for a particular instrument, it will help your scrub nurse to anticipate your next move and to place the instrument always in a standard way into your hand.*

There are many microneurosurgical sets, such as the Yaşargil, Rhoton or Perneczky set, and a large array of bipolar forceps as used by Prof. Yaşargil. They are all excellent, and serve a good purpose. The surgeon should use whatever he or she likes, and there are no commercial preferences suggested. In Helsinki style microsurgery, there are 11 basic instruments that are used in the vast majority of situations (Figure 4-10). These consist of four bipolar forceps (longer and short, sharp and blunt tipped), microdissector, straight microscissors, aneurysm clip applicator, straight blunt steel needle for irrigation, and three suction tubes (long, medium size, and short) which allow regulation of the suction power through three holes (earlier on, one hole was factory made and the two additional holes self made) by sliding the thumb. By limiting the number of instruments in the standard setup to only those that are necessary, one can save a lot of time. With large microinstrument sets, a lot of time is lost in the process of: (a) selecting the instrument in mind, (b) asking for the instrument, (c) searching for the particular special instrument among so many similar looking ones, (d) placing the instrument into the hand of the surgeon, and (e) finally moving the instrument into the operative field. As this process can be repeated hundreds of times during a single surgery, it is reasonable to simplify it as much as possible. But if required, also less frequently used instruments or their special versions should be easily available.





*Figure 4-10. The basic set of 11 instruments. Four bipolar forceps (longer and short, sharp and blunt tipped), microdissector, straight microscissors, aneurysm clip applicator, straight blunt steel needle for irrigation, and three suction tubes (long, medium size, and short).*

#### 4.7. SOME HABITS IN PREPARATION AND DRAPING

Maybe a better word to use than habit is consistency. A criticism of consistency is that it is unimaginative or just boring. Our philosophy in Helsinki is that until you find some better way to do a certain thing, don't change your ways. Find a good method and stick to it. The people we work with in the OR appreciate our consistency. A significant lack of consistency can even generate anxiety and fear in those around us. Consistency goes hand in hand with a systematic approach. It should not be confused with what is customary or traditional. It should be based on logic, reason and experience. This way assistants around you know what to get for you, how to help you and what to expect. Not just in anticipating what instruments you use next or your surgical technique. But even their familiarity with how you think, talk and behave allows them to understand you and assist you better.

##### *T&T:*

*In your operations, change only one thing at a time! You can be creative, but proceed slowly.*

This is probably best exemplified by how Prof. Hernesniemi positions the patient, drapes and then carries out the appropriate craniotomy in the same predictable way. These steps include the following:

1. Upon arrival in the OR he checks the microscope optics, balance and mouthpiece.
2. He reviews the radiological images before and then once again after checking the microscope, not least to double-check the side of the lesion. This is very important for the position of the surgeon, scrub nurse, microscope and the assistant.
3. The cases where a supine position is necessary the head is elevated above the heart by using a strong round pillow under the shoulders to elevate the upper chest. The exact positioning for each approach is reviewed in Chapter 5.
4. The head is first fixed in the Sugita head frame by four pins. Then all the joints are released and the final positioning of the head is performed in accordance with the operative approach, angle of approach and site of pathology. Only then all the joints are finally fixed.
5. The appropriate incision site is shaved with an electric razor.
6. A hand held razor is used for a finer shave and then gel soap ("Mäntysuopa", a traditional soap used in Finland) is applied to clean the area and comb the hair back away from the wound with the hands.
7. Then Prof. Hernesniemi leaves the OR to wash his hands from the soap, returning to clean the wound area using swabs soaked in 80% alcohol. The wound region is repeatedly cleaned, ensuring all dirt particles, oily secretions and skin debris are wiped away.

8. The incision is drawn using a disposable sterile pen.
9. The wound is infiltrated using usually approximately 20 ml of a solution consisting of a 1:1 combination of 0.75% ropivacaine and 1% lidocaine with 1:100 000 adrenaline.
10. Then large abdominal swabs are laid out isolating the incision area. The swabs are held in place and the incision area is covered using a large Opsite dressing, which is also placed over the sides of the Sugita frame and pins to fix it in place. The ground below the draped region is wiped clean by Prof. Hernesniemi himself. This practice is based on a fall on a slippery floor during a stereotactic procedure in the 70's. The scrub nurse commences the rest of the draping procedure.

*T&T:*

*While preparing the positioning and the operative area, the different steps of the upcoming operations are going through the neurosurgeon's mind. Going through a known routine helps to focus and calm down. Few kind words with the scrub nurse and others ensure readiness for the surgery, and relax the atmosphere.*

## 4.8. GENERAL PRINCIPLES OF CRANIOTOMY

The scalp is minimally shaved, washed, and then infiltrated along the drawn incision line by an anesthetic and vasoconstrictive solution. In the approaches to the anterior and middle skull base, direct incision through the skin and temporal muscle and turning a single-layer flap have been proven safe for more than 25 years. There is no temporal muscle atrophy or injury to the upper branch of the facial nerve. Strong retracting force of the Sugita frame fish hooks gives a wide exposure of the Sylvian fissure and the skull base without large skull-base resections and at the same time controls the scalp and muscle bleedings, which are swiftly dealt with using bipolar coagulation. Most craniotomies require only one burr hole and cutting of the bone flap with a craniotome. The adherence of the dura to the bone increases with age, and additional burr hole(s) may be needed. A special curved dissector ("Jone", Figure 4-11a), designed by a hospital technician from Kuopio and carrying his name, is useful for adequate dissection. In case of a larger bone flap, flexible Yaşargil-type dissector is useful also (Figure 4-11b). The major dural sinuses are more easily detached from the bone by placing the burr holes exactly over them rather than laterally. Over the regions with thicker bone or over sinuses bone is thinned down using craniotome

without the L-shaped footplate. Afterwards, it is possible to crack the bone along this thinned ridge. Craniotome is also used for drilling several holes along the craniotomy edge to be used for tack-up sutures during closure. More bone is then removed with a high-speed drill, working towards the desired direction. Small bleeding from the bone is stopped using a diamond drill without irrigation, the so-called "hot drilling".

A common comment by visitors is the lack of profuse scalp bleeding during the surgery. This is certainly because of good anesthesia keeping the blood pressure normotensive, but mainly due to local infiltration using plenty (up to 20 ml) of 0.75% ropivacaine and 1% lidocaine with 1:100 000 adrenaline several minutes prior to the incision. Additional means to tackle bleeding from the scalp is the use of disposable Raney scalp clips (Mizuho Medical Inc., Tokyo, Japan) at the incision line and heavy retraction/tension in the scalp flap either with spring hooks or sufficient tension in linear wound spreaders. Any further hemorrhage points are taken care of vigorously during the approach. Not only does it save much time and prevents distraction during the crucial parts of the operation but also during the closure. Craniotomy should

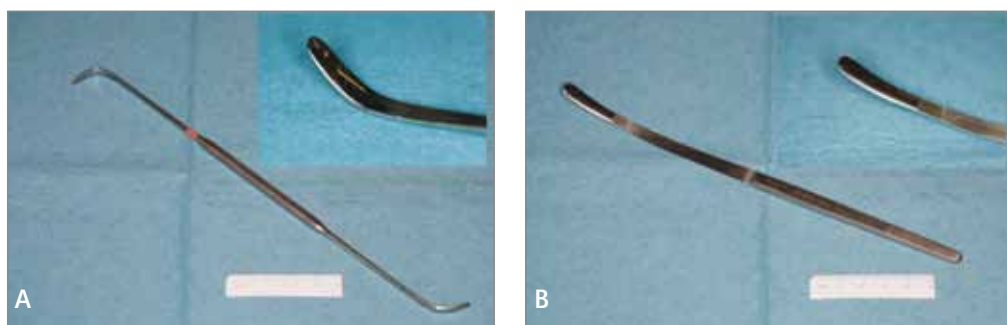


Figure 4-11. (a) The curved „Jone” dissector, used to separate the dura from the inside surface of the skull. (b) The Yaşargil-type flexible dissector useful for larger bone flaps.

not be performed before bleeding from the more superficial layers has been taken care of.

Dura is opened only after careful hemostasis. This is one of the steps that have to be finished before moving forward. Venous oozing from epidural space can be stopped by combination of Surgicel, fibrin glue, and lifting sutures. Permanent tack-up sutures are placed normally at the end of the procedure once the dura has been closed as they prevent additional stretching of the dura to cover small gaps that may be needed during closure. In case of serious epidural bleeding, the permanent tack-up suture may be placed already before opening the dura. Injecting saline into the epidural space makes Surgicel to swell stopping epidural oozing more effectively than simple Surgicel tamponade. The area surrounding the craniotomy is covered with swabs dipped in hydrogen peroxide and a green cloth is attached to the craniotomy edges with staples. The green cloth is used to increase colour balance in the operative field for obtaining a better image from the microscope's video camera, and, quite frankly, the operative field just looks cleaner and better. In general, the operative field is saturated with red colour and especially in older microscope cameras that may cause a significant problem

in image quality. The other reason is to decrease the amount of reflected light from the white swabs, which under microscope's high intensity lamp can be almost blinding. The dura is opened usually in a curvilinear fashion in one or several pieces with wide base(s) and lifted up with many tight sutures to form a tent-like ridge along the opening preventing any further oozing from the epidural space. These sutures under tension keep the green cloth in place and they are fixed onto the surrounding drapings with hemostats (Crile, Dandy or other).

*T&T:*

*Never continue surgery before stopping all the bleedings!*

*T&T:*

*Keep the operative field as clean as possible. It will make visualization of anatomical structures easier and leads to better and faster surgery.*

## 4.9. BASIC MICROSURGICAL PRINCIPLES OF HELSINKI STYLE MICRONEUROSURGERY

### 4.9.1. Simple, clean, fast and preserving normal anatomy

The whole concept of microsurgical principles of Helsinki style microneurosurgery can be summarized into the words "simple, clean, fast, and preserving normal anatomy".

*Simple* refers to doing only what is really necessary and trying to achieve this goal by as little effort as possible. Interchanging instruments is kept at a minimum, the repertoire of instrumentation is kept very standard and limited. In this way both the neurosurgeon and the scrub nurse become familiar with the instruments faster and certain steps of the surgery can be standardized. In addition, the same instrument can be used for several different tasks as explained further on.

*Clean*, bloodless environment is the key factor for a successful microsurgical operation. With high magnification, even a tiny bleeding can fill the whole operating field making orientation impossible. Hemostasis throughout the procedure is of utmost importance but in addition one should also choose such surgical strategy which prevents bleeding from occurring in the first place. This can be achieved by selecting the right approach and sticking to the natural cleavage planes and boundaries. Every bleeding should be stopped as soon as it is detected before moving further. In addition, irrigation can be used very liberally to flush out any blood clots or other obstructions from the operative field.

#### *T&T:*

*Water clears the operative field and the mind, and makes a break in the operation. When you need to think how to proceed, irrigate.*

*Preserving normal anatomy* comes with respecting natural tissue boundaries and cleavage planes. Orientation under high magnification becomes much easier when the dissection is directed along anatomical structures keeping them intact. Anatomical structures should be invaded only when it is absolutely necessary for the procedure. One should always choose the approach that is the least invasive and preserves the normal anatomy to minimize the possibility of new postoperative deficits.

*Fast* does not mean that things should be done in a rush, rather it is the effect of the previous three factors. The majority of time during surgery is lost by poor planning, wrong or inappropriate approach and by tackling undesired situations such as bleedings. Correct surgical strategy and pre-emptive evasion of problems brought by experience increase the speed of surgical performance over time. It is easier to maintain proper concentration during a shorter procedure, one does not make mistakes as easily, and in addition, it becomes also more cost effective as one can perform more surgeries in a given time. But especially at the beginning of the career one should concentrate more on quality of performance than speed. The speed will come with experience.

#### *T&T:*

*In many of the so-called "heroic and long-lasting" surgeries, most of the time is actually spent on correcting one's own mistakes. Especially to stop bleedings caused by the surgeon himself.*

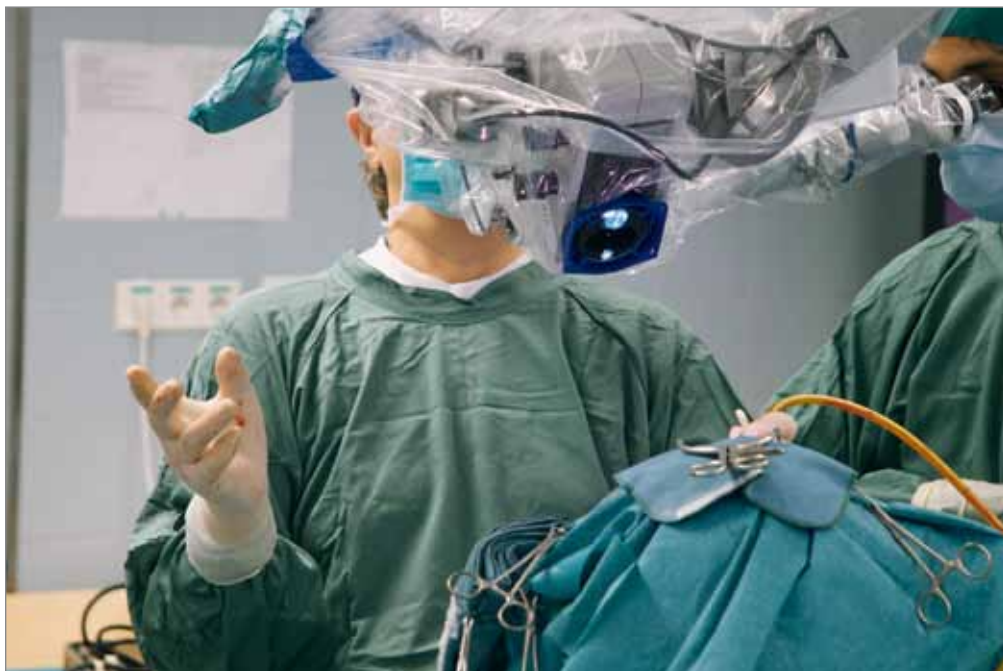

Figure 4-12. The right hand waiting for an instrument, while keeping the eyes on the microscope.

#### 4.9.2. Movements under the microscope

It is considered by some as sacrosanct to use microinstruments only under direct microscopic vision. They remove all the instruments completely out of the wound and away from the vicinity of any crucial and important structures, while their eyes are not on the operative field. The worry is that if you have not got an eye on it, then you cannot be sure what your hand or instrument is doing. However, this slows the surgery down as every instrument has to be repeatedly brought into the operative field. To make the surgery more fluent and effective, one needs to master the technique of the so-called "blind hand". It means movement without direct visual control. The first blind maneuver easily mastered by a microsurgeon is the change of instrument by the right hand. That means the right hand instrument is taken out, and while looking down the microscope the awaiting hand is given the next instrument

by the assisting nurse (Figure 4-12). This is relatively easy as vision is maintained on the more crucial hand and instrument in the surgical field. A more demanding but even more useful adaptation of the blind hand technique can be seen in situations when an instrument is kept in the surgical field without direct vision, while the neurosurgeon casts his or her eyes away from the microscope and looks elsewhere. This may be to take e.g. a cottonoid, or adjust the microscope (Figure 4-13). This is usually done only for brief moments but the remaining hand and the instruments should be kept in the exact same position as before.

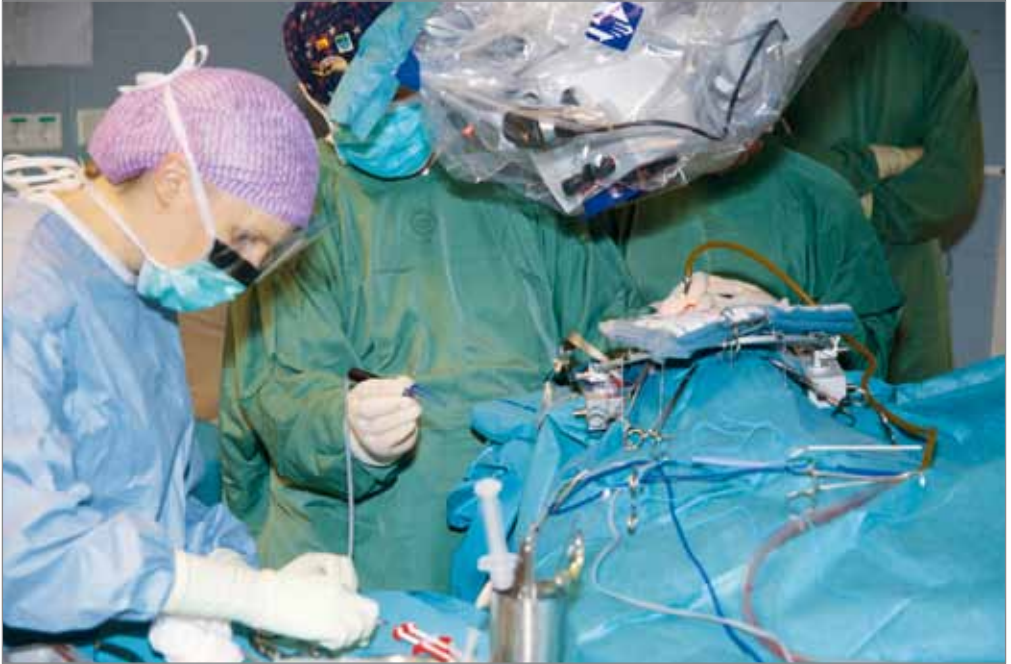In Prof. Hernesniemi's style the pace and fluency of surgery is evident with the use of the blind left or right hand in the operative field. It is a manifestation of confidence and fluency possessed to do this regularly and flawlessly.

The task is performed subconsciously, similar to the way a guitarist plays very fast and intricate notes without looking at his fingers. The ability comes after much practice and experience. After a while when you are so familiar with your senses and ability you can speed up for good reason. And if you are keeping an instrument still and steady then you may not need to visually check the position of your instrument at each and every moment. You are sure from other non-visual senses where it is. A steady pivotal left hand (and occasionally right hand) can significantly shorten temporary clipping times, lessen the need for re-exposure or repeated dissection and retraction. What it does allow is to move and adjust position of the microscope or armrest, take cottonoids or Surgical, and even choose the best aneurysm clip by visual inspection. This while keeping the left hand absolutely still near crucial structures, while the body may even pivot around the left hand instrument.

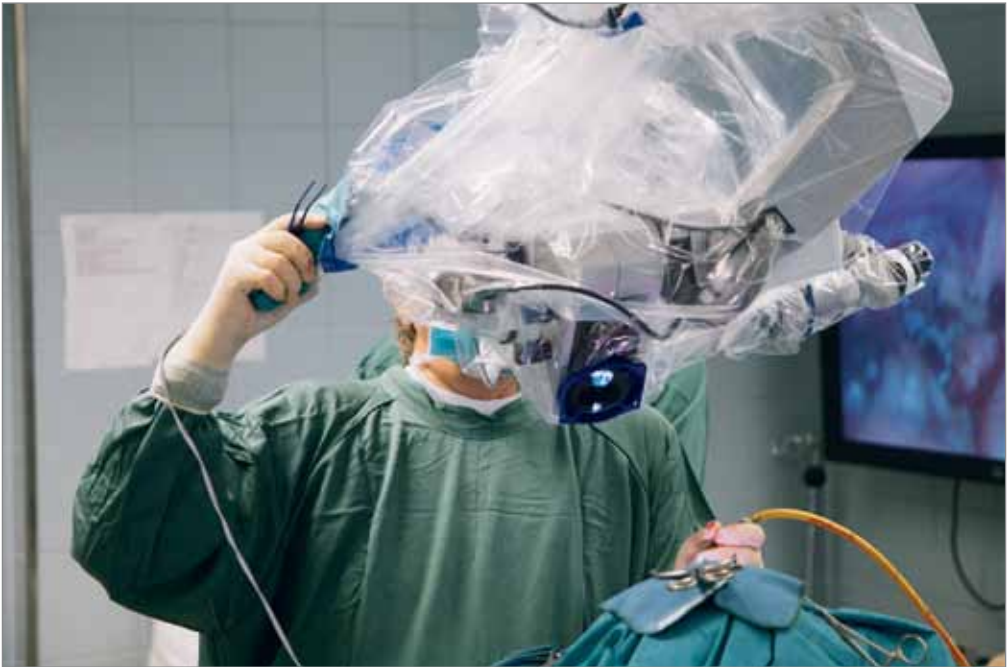Also the interchangeable right and left hand function as small retractors is beneficial. This is very useful, for example, in fast and smooth subfrontal dissection for the opening of the lamina terminalis. When you are faced with an angry swollen brain with hydrocephalus or hemorrhage, it is better to be fast. To make progress, avoid periods of non-action - yet hurrying is not a good thing either. If there is one safe and easy move that can compensate for two, then this move should be carried out. The speed actually comes from leaving out the unnecessary moves and avoiding possible problems, not from doing things in a hurry.

This style demands strength, stability, appreciation of the surgical field, depth perception, feel for tissues, and a joint position sense. The neurosurgeon can hold the sucker to suck, retract, or maintain tissue planes. Under direct vision it can be a consistent reference point in the surgical field after blind change of instruments with the right hand. After much practice and familiarity the microneurosurgeon combines the use of the visual senses, feel for tissues and proprioception to give a high sense of awareness regarding surgical dimensions, depth of wound and relationship of instruments to close and crucial structures. A fast and excellent microneurosurgeon schooled in Helsinki style can place a combination of sucker, microscissors or bipolar into a small wound and move with precision and fluency around small crucial nerves and vessels while performing dissection, cutting, coagulating, excising, occluding or even suturing in the depth; this without disturbing any important structures and without the repeated withdrawal and re-entry of the same instruments and unnecessary gaps of doing nothing. Being aware of such techniques helps training. It is best appreciated by watching many experienced surgeons "live" in the OR, paying attention to their body posture and movements, hand movements, and also the actual microsurgical technique under the magnification of a microscope.





*Figure 4-13. Looking away from the microscope, while the left hand (holding a suction) remains in the operative field.*



*Figure 4-14. Adjusting the microscope with only the right hand. This can be done even with the right hand still holding an instrument.*

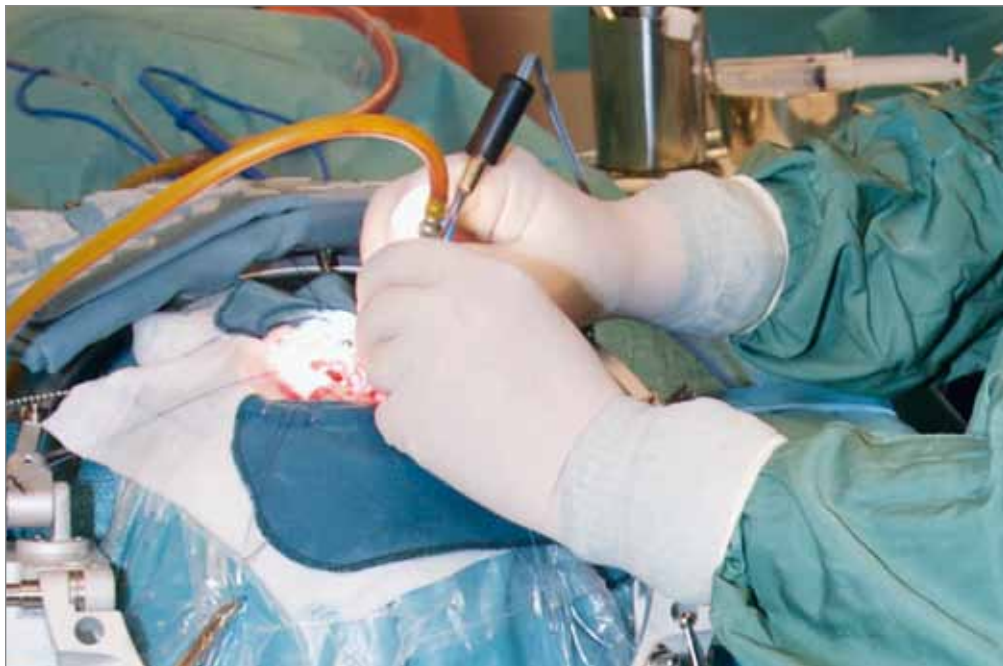### 4.9.3. Moving the microscope

One of the distinct styles of Helsinki style microneurosurgery is the constant movement of the microscope. With the mouthswitch it is possible to move the microscope in the horizontal plane and up and down (Figure 4-6 – page 77). Especially the vertical movement is crucial since it is used for focusing. With fixed focal distance, small vertical movements with the mouth switch are used to focus inside the deep operating field. Also small translational movement in plane is carried out using only the mouth switch. All this movement is necessary especially when operating under a very high magnification. Autofocus is of no use with the mouth switch; rather, it moves the microscope out of focus all the time. With the right thumb the neurosurgeon can change zoom or focal distance on the right handle of the microscope blindly while stabilizing the microscope with the mouth switch. Tilting and chang-

ing the viewing angle requires also the right hand. But even here with the mouth switch as second contact point, the microscope can be turned with only one hand while the left hand and suction is kept in the visual field as a pivot point (Figure 4-14). The standing posture gives very much freedom for even rather extreme and fast changes of viewing angle. Eventually, when watching a neurosurgeon who has mastered this technique, it looks like he or she is dancing around the patient while the microscope is floating.

#### *T&T:*

*A mouthpiece is one of the great introductions of Professor Yaşargil. It is surprising that not every microneurosurgeon is using it!*



*Figure 4-15. For a right-handed neurosurgeon, left hand is mainly used for controlling the suction, the left hand for the other instruments.*

#### 4.9.4. Left hand – suction

For a right-handed surgeon, the suction is in the left hand (Figure 4-15). The suction can be the most dangerous instrument if it is not used properly. But in trained hands its use allows not only suction, but gentle inspection, retraction and dissection. Even the varieties of sounds made while using its suction function gives the surgeon, assistant and scrub nurse information about the state, consistency, nature and character of the fluid or tissue at its tips. The strength of the suction should be regulated by the use of the thumb sliding across the three holes at the base of the suction tube (Figure 4-16). The staff in OR should be ready to quickly adjust the strength of the suction. The tube attached to the metal sucker should be of good quality (e.g. silicon rubber), light, and flexible such that it does not over-burden or hinder the movements of the left hand.

We use mostly two to three different diameters of suckers with three different lengths available (short, medium and long). A dry sucker shaft or one stained with coagulated blood may cause it to stick to the surrounding brain. Instead, it should be clean and slightly wet to facilitate its function as a gentle and most useful retractor. Very importantly, the tips of the suction should be checked regularly to ensure that there are no sharp edges caused by, e.g. use of high-speed drill. The use of regular saline irrigation or washout with a handheld syringe cannot be overstated. Frequent irrigation prevents instruments from adhering to tissues, removes debris and clears the picture seen in the mind of the surgeon. The use of irrigation is discussed further in section 4.9.10.

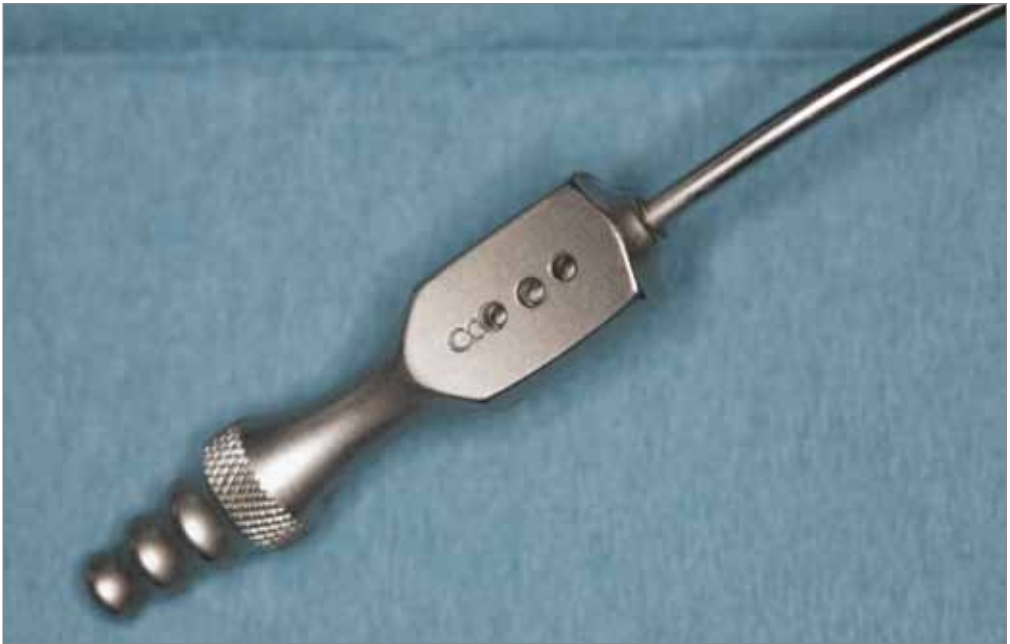

Figure 4-16. Three holes at the base of the suction tube enable controlling the suction force by sliding the thumb.

#### 4.9.5. Right hand

The right hand is generally for the bipolar forceps, but also for the microdissector, microscissors, clip applicators, drills, ultrasonic aspirator and Sonopet alike. There are various styles and methods of using the right hand in microneurosurgery, which becomes evident when observing different neurosurgeons at different departments. Some make little use of the bipolar forceps for dissection and instead use the dissectors or even two jeweler's forceps to a much greater extent. The right hand is also used to adjust microscope settings and to move the microscope. In the beginning it is easier to perform these adjustments with an empty hand, but with time one learns to grab the handle of the microscope while still holding bipolar forceps in the right hand.

#### 4.9.6. Bipolar forceps

In Helsinki style microneurosurgery the bipolar forceps are used frequently and effectively for inspection and dissection of structures and anatomical planes. The bipolar forceps opens by itself, and as long as the opening force is suitable, it can be used to open arachnoid planes, separate membranes, macerate tumor tissue in preparation for debulking, dissect sharply inside glioma tissue using the coagulation function, and obviously simply to coagulate tissue.

There are mostly two lengths of bipolar forceps used by Prof. Hernesniemi. For both lengths there are sharp and blunt tipped versions of the forceps available. Other lengths are available if needed but most of the time these two lengths are sufficient. In situations where coagulation is repeated over and over, like in glioma or AVM surgery, two or more forceps of the same kind are interchanged and cleaned repeatedly by the scrub nurse to save time. The bipolar forceps has several possible functions. It can be used as dissector by using its tips, it can macerate and coagulate tumor tissue and finally its shaft can function as a microretractor. Clean tips are essential for dissection of natural cleavage planes under high magnification. The angled or curved bipolar forceps help in places that are hard to reach behind a corner, such as the olfactory groove.

The use of the bipolar forceps for blunt dissection is consistently demonstrated in most of the microsurgical videos that show the approach to an aneurysm and tumor. It is probably best seen during opening of the Sylvian fissure, during dissection in the cerebello-pontine angle, or during dissection in the interhemispheric approach. There is a natural tendency for the bipolar forceps to open and this is used effectively to gently separate tissue planes. This is done as blunt dissection using blunt tipped bipolar forceps between tissue planes e.g. arachnoid layers, or tumor/brain interface. Or it is done

as sharp dissection by using the sharp tipped bipolar forceps to cut across tissue planes like when opening the lamina terminalis. The bipolar forceps is also used to assess and gauge the consistency of a vessel by gently pinching the vessel, or assessing the consistency of an aneurysm or other lesion by resting the tip of the bipolar forceps on it.

When coagulating, it is important to place a little gap between the tips of the forceps to allow adequate coagulation, and also preferably to use short and small bursts of coagulation to lessen the incineration and charring effect which so often covers the bipolar forceps tips. This technique of "open-close" or "to and fro" or "oscillating" coagulation as well as "hopping" along the length of a vessel where coagulation is required is basic and useful, as is the use of small amounts of irrigation. It allows better coagulation and prevents the sticking of the bipolar tips. "Dirty coagulation", a special technique in AVM surgery or in highly vascularized tumors, is to coagulate tiny perforators with almost nonexistent vessel wall by taking little surrounding brain tissue between the tips of the forceps and coagulating the vessel through this tissue mass.

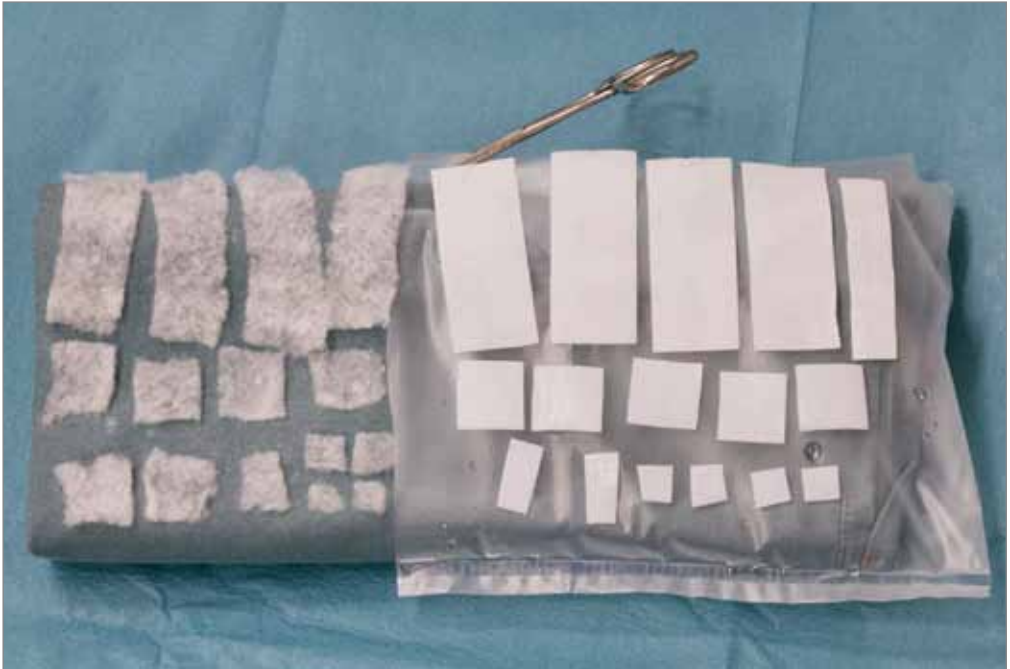#### 4.9.7. Microscissors

The microscissors are used to delicately and swiftly separate arachnoid membranes and layers, not just by use of the cutting blades, but also by using the side of the closed tips. The tips of the microscissors are often used for gentle retraction of small or large vessels, cranial nerves or even inspection of an aneurysm. Such ability to gently and precisely use common instruments for multiple tasks avoids unnecessary interchange of many microinstruments. This prevents the crowding of the nurses tray and shortens the operation time.

#### 4.9.8. Cottonoids

The cottonoids or patties should be readily available in different sizes close to the operative field. We usually prefer cottonoids without strings as the strings get easily twisted or entangled to each other and they are frequently accidentally pulled out (Figure 4-17). Also, the strings easily obstruct part of the operative field especially in deeper locations. On the other hand, using cottonoids without strings requires always meticulous checking of all the operative field that some small cottonoid is not left behind, especially in large resection cavities with structures blocking the view.

The cottonoids can be used for several purposes:



*Figure 4-17. Cottonoids and pieces of Surgicel fibrillar placed on a pad situated next to the operative field; continuously replenished by a scrub nurse during the operation.*

- To facilitate non-traumatic suction on neural tissue and near cerebral vessels
- To protect crucial neural or vascular structures during dissection and approach. For example during the opening of the dura to protect the cortex
- To protect neural tissue from the sharp edge of a retractor blade, sucker or bipolar forceps.
- To cover the surrounding region where Sopenet and CUSA are being used and to prevent the accumulation or adhesions of bone dust and other debris to the surrounding
- For tamponade and hemostatic effects
- To use as soft and atraumatic dissection masses such as in the development of the plane between tumor and surrounding tissue.
- To gently dissect small vessels from surrounding neural tissue.
- To prevent the wall of a cavity to collapse during surgery of large tumors, while providing some tamponade effect against small venous oozing
- To take care of small venous oozing during dissection of e.g. Sylvian fissure
- To use as small expansive masses that can be used to keep a dissected fissure open during e.g. MCA aneurysm surgery, or during an interhemispheric approach
- To keep a temporary clip aside or to orient the aneurysm dome into the better position during final clipping

The cottonoids should not be placed close to an area where a high speed drill is being used as they very often get swept away by the drill and while rotating can cause damage to the surrounding tissues.

#### 4.9.9. Sharp and blunt dissection

Sharp dissection means cutting across tissue planes, and blunt dissection going between tissue planes and anatomical boundaries. The use of the microscissors to cut appropriate arachnoid membranes or adhesions is a classic example of sharp dissection. But an arachnoid membrane can be also opened by puncturing it with sharp bipolar forceps, cutting the membrane with a special arachnoid knife, or by tearing the arachnoid membrane using short jewelers' forceps. A cheap alternative to the arachnoid knife is a disposable, sharp, straight needle attached to a 1 ml syringe acting as a handle. Blunt dissection is usually performed by entering a natural cleavage plane, and following this plane while stretching the plane further on. The common methods in our practice are the use of bipolar forceps, microdissector, small cottonoids, and most importantly the use of water dissection (see below).

#### 4.9.10. Irrigation and water dissection

Irrigation is used very liberally and in large amounts throughout the whole operation. Its main uses are: (a) keeping the operation field clean, (b) identifying bleedings, (c) preventing tissues from drying and sticking to the instruments, and (d) water dissection. For irrigation warm physiologic saline is used. It is applied from a normal, hand-held 20 ml syringe with a straight, blunt needle with a rather large bore.

Perhaps the most popular and distinctive method of dissection seen in Helsinki is the use of water dissection. This was described and popularized by Dr. Toth in Budapest and is not as recognized as it probably should be. It is effective, least hazardous and cheap! Water dissection is used to separate natural planes from each other. First the origin of the dissection plane is identified. Then saline is injected using

a handheld syringe into the cleavage plane that stretches and expands facilitating further identification of planes, structures and further sharp dissection. The same technique can be used to expand any kind of borders or plains, e.g. when dissecting an extra-axial tumor, opening the Sylvian fissure or removing an AVM.

#### 4.9.11. Minimal retraction

In Helsinki style microneurosurgery, where it is possible, no brain retractors are used. There are some exceptions where a narrow tipped Sugita retractor is used such as some ACoA aneurysms or when removing a deep-seated lesion such as e.g. intraventricular meningioma or third ventricle colloid cyst. Then there are certain approaches, such as the subtemporal approach toward a basilar tip aneurysm, which simply cannot be performed without a wide self-retaining retractor, even if a lumbar drain has been used to remove CSF.

Instead, it is primarily the use of the appropriate suction tip shaft and bipolar blades together with cottonoids that provide gentle retraction of the brain but mostly they maintain surgical space already gained, e.g. in the subfrontal dissection for a cerebral aneurysm or to open the lamina terminalis. At first, the bipolar forceps is used for retracting for the suction to release CSF and then the suction is used to maintain that space while bipolar forceps are working. This maneuver is important to understand and is probably best grasped by watching the videos, especially the opening of the lamina terminalis. In experienced hands the role of microretractors by the suction or bipolar forceps are constantly and subconsciously interchanged. This allows the surgeon to almost crawl in along natural planes, e.g. in subfrontal dissection.

#### 4.10. CLOSING

In Helsinki, closing of the wound, including the skin, is performed under the magnification of the operating microscope. This is an excellent way of microsurgical training. At the same time, due to magnification and good illumination, hemostasis can be achieved easier under visual control. One should always be confident on how to bail out, so knowing how to close well is necessary before advancing to any more complex procedures.

Closing is performed in layers. Dura is closed watertight if possible with running 3-0 or 4-0 suture using atraumatic needle. Small dural defects are sealed with fibrin glue. For large dural defects we use either pedicled periosteum flap or some commercial dural graft, several of which are widely available from different companies. Tack-up sutures between the dura and the previously drilled holes at the craniotomy edge are used to stop oozing from the epidural space and Surgicel packing further enhances this effect. Dura is overlaid with some Surgicel before putting the bone back. The bone is fixed with two or more Aesculap Craniofixes. Only in large bone flaps one or several central sutures are used. Muscle is closed in one or several layers with resorbable 2-0 running or interrupted sutures. The fascia of the muscle should be continuous if possible. The next layer, the galea-subcutaneous layer, is closed again with either running or interrupted 3-0 resorbable sutures. Care is needed to have the two wound edges at the same level for optimal cosmetic result. Staples are used for the skin and removed after five to seven days. We do not use any drains, instead rather rely on meticulous hemostasis. The only exceptions for use of drains are very large hemicraniectomies or cranioplasties in trauma or brain infarction patients.



#### 4.11. KEY FACTORS IN HELSINKI STYLE MICRONEUROSURGERY

The key factors and ingredients of Helsinki style microneurosurgery that make surgeries smoother and faster are the following:

- Consistency in preparation. A sound and safe method, including checks and procedures, which have been based on good clinical reasons and principles. The habits contain steps and checks that avoid problems. Have consistency in the operation at all its stages. Everyone who is involved in the operation should know what you want, need and what to expect.
  - Fast surgery because it is better than slow. It does not mean hurry! If there is one move that will compensate for two, go for it. Be efficient.
  - Continuous training. To achieve speed and flare in microneurosurgery one needs a lot of training.
  - Calmness and contemplation, yet ability to adapt for action and what the situation demands.
  - Respect for the teamwork. Being kind, understanding, pleasant and respectful to all the staff and team, yet firm and uncompromising in standards for patients.
  - Working hard. There is no substitute for working hard with dedication.
- More subtle and specific features of the operative techniques and style of Prof. Hernesniemi are the following:
- The interchange of function between left and right hand instruments. Both hands work towards the same goal. At all times the movements are perfectly weighted and as atraumatic as possible. This allows fast and smooth procedures such as the opening of the lamina terminalis when there is an angry swollen brain.
  - Minimal use of traumatic fixed retraction systems. It is much safer to use high magnification on the microscope and make gentle use of mainly the left hand instrument as a retractor.
  - Maximum and efficient use of the best few microinstruments. "Hand signs" for these common instruments allow the scrub nurse to anticipate the next move. Special instruments should be available as well but their use is limited and brief.
  - The use of the blind change of instruments with the right hand and the use of the steady pivotal left hand when needing to look away from the microscope. This avoids the loss of the left hand retractor function, as well as loss of the surgical planes and space that have been gained during earlier dissection. In addition this avoids the repetitive withdrawing and re-inserting of the left hand instrument into the surgical field.
  - Avoidance of unnecessary gaps, pauses and delays. Break can be taken when it is safe to do so. But the general action stays focused on the goal and each movement brings this goal closer.
  - Teamwork together with the scrub nurse. The scrub nurse should know when, what and why something is needed. This is why it pays off to be consistent and keep things fast, safe and simple!
  - Uncompromised approach towards the requirements for successful surgery. Careful planning and pre-emptive evasion of problems result in smooth execution of the surgery.
  - A soft, neutral music in the OR helps to relax the team.

#### 4.12. LIST OF PROF. HERNESNIEMI'S GENERAL HABITS AND INSTRUMENTS

The habits of Professor Hernesniemi as recorded by the nursing staff. This list is updated on regular basis and is used both as memorandum as well as training material for new scrub nurses.

- Always standing throughout operation (except bypass surgery)
- Sugita head fixation clamp and always screws for adults, even for children
- Before covering operating area he puts abdominal swabs and a big Opsite film around the operating area
- Size L operating theatre gown, made of microfiber
- Arm rest stand
- Mayo-stand cover for arm rest stand
- Medena suction tube (Astra Tech)
- Scalpel blade for skin (e.g. Aesculap BB523)
- Scalpel blade for opening the dura (e.g. Aesculap BB515)
- Cottonoids without thread
- Surgicel fibrillar
- Bone wax Aesculap (e.g. Aesculap 1029754)
- Cranial perforator (e.g. Aesculap GB302R)
- As a wirepass drill, he uses craniotomy drill bit without foot plate
- Fibrin glue (e.g. B. Braun Tisseel Duo Quick) should always be ready with straight tip
- Diathermy setting 50, bipolar 50 in the beginning, after dura has been opened 30, for aneurysms 25, with sharp bipolar tip 20
- Around the opening small wet hydrogen-peroxide swabs and a green cloth fixed with wound staples
- In the beginning, a short suction cannulae #12 (e.g. Aesculap GF409R); after craniotomy #8 suction cannulae (e.g. Aesculap GF406R); length depending on the depth (three different lengths)
- Papaverin solution ready for every aneurysm surgery & vascularized tumors
- Tack-up sutures: Safil violet 3/0 hrt26 (e.g. Aesculap C1048742)
- Dural sutures: Safil violet 4/0 hrt22 (e.g. Aesculap C1048329)
- In spinal surgery, tack-up sutures 4-0 Prolene
- Irrigation tip is re-useable blunt steel needle
- "Needle-knife" = 1ml syringe + 18 g pink hypodermic needle
- AVM's and caroticoavernous fistulae -> lots of fibrin glue (e.g. B. Braun Tisseel Duo Quick)
- In every re-craniotomy, free boneflap is soaked in antibiotic solution (cloxacillin), after which boneflap is soaked in saline before re-attachment
- To lift up tentorium in subtemporal approach – YASARGIL MINI temporary Aneurysm Clip (e.g. Aesculap FT210T)
- Small openings: use of a small DIADUST micro needle holder (e.g. Aesculap BM302R) and MICRO-ADSON tissue forceps (e.g. Aesculap BD510R) or bayonet micro forceps (e.g. Aesculap FD111R, BD836R)
- Long narrow DIADUST micro needle holder (e.g. Aesculap BM327R)
- For thin ventricular catheter a barium integrated catheter + green IV cannula
- "Childrens glue" = e.g. B. Braun Histoacryl (for example to wrap an aneurysm)
- For drilling in spinal surgery only long drill tips, not extended drill tips

- 2/0 Safil take-off sutures for muscle and subcuticular sutures (e.g. Aesculap C1048031), skin closed with wound staples
- CranioFix2 clamp, 11 mm, FF490T x 3

### **Craniotomy & instruments**

- High speed power system (e.g. Aesculap HiLAN XS drill system)
- Hi-Line XS Rosen burr (D5.0mm e.g. Aesculap GE408R, D6.0mm e.g. Aesculap GE409R)
- Hi-Line XS Diamond burr (D5.0mm e.g. Aesculap GE418R, D6.0mm e.g. Aesculap GE419R)
- Cranial Perforater Hudson D6/9mm (e.g. Aesculap GB302R)

### **Professor's standard microinstruments**

- **Bipolar forceps**
  - CASPAR Coagulation Forceps "ice-hockey" (e.g. Aesculap GK972R, GK974R)
  - CASPAR Coagulation Forceps 19.5 cm regular (e.g. Aesculap GK940R)
  - CASPAR Coagulation Forceps 16.5 cm blunt (e.g. Aesculap GK900R)
  - CASPAR Coagulation Forceps 16.5 cm sharp x 2 (e.g. Aesculap GK899R)
  - CASPAR Coagulation Forceps 19.5 cm sharp x 2 (e.g. Aesculap GK929R)

### **Suction cannulae**

- Length L, 5 Fr (e.g. Aesculap GF413R)
- Length L, 7 Fr. (e.g. Aesculap GF415R)
- Length M, 6 Fr. (e.g. Aesculap GF394R)
- Length M, 7 Fr. (e.g. Aesculap GF395R)
- Length M, 8 Fr. (e.g. Aesculap GF396R)
- Length M, 12 Fr. (e.g. Aesculap GF399R)
- Length S, 8 Fr. (e.g. Aesculap GF406R)
- Length S, 12 Fr. (e.g. Aesculap GF409R)

### **Irrigation tip, metal blunt**

- short
- 8 cm

- HALSTED-MOSQUITO Haemostatic forceps (e.g. Aesculap BH111R)
- Brain Spatulas (e.g. Aesculap FF222R)

### **Clip Appliers**

- YASARGIL MINI Clip Applier (e.g. Aesculap FT474T)
- YASARGIL MINI Clip Applier (e.g. Aesculap FT477T)
- YASARGIL MINI Clip Applier (e.g. Aesculap FT470T)
- YASARGIL Titanium Clip Applier standard (e.g. Aesculap FT482T)

- **Microscissors**

- Micro dissecting scissors (e.g. Aesculap FD103R)
- Micro scissors 12-17329
- YASARGIL micro scissors straight (e.g. Aesculap FD034R)
- YASARGIL micro scissors angled (e.g. Aesculap FD039R)
- Kamiyama scissors

- **Micro Dissectors / Micro Hooks**

- Micro dissector 200 mm, 8" (e.g. Aesculap FF310R)
- Sharp hook 90° angled, 185mm, 7 1/4" (e.g. Aesculap FD375R)
- Nerve- and Vessel Hook (e.g. Aesculap FD398R)

- **Microforceps**

- Ring Forceps for Grasping Tissue, Tumors etc. (e.g. Aesculap BD766R)
- Ring Forceps for Grasping Tissue, Tumors etc. (e.g. Aesculap BD768R)
- Micro Forceps, short x 2 (e.g. Aesculap BD330R)
- Forceps with teeth (e.g. Aesculap BD886R)

- **Occipital surgery**

- If opening in the midline, patient is in sitting position – very old patients and children are operated in prone position (emergency cases may be operated in prone position because OR technician is not present)
- If opening is lateral suboccipital, patient is in park bench position and surgeon is on either side & nurse is standing at the cranial end
- Sometimes a spinal drainage is used
- Curved self-retaining Retractors Aesculap BV088R (Mastoid retractor) are used instead of Raney clips (e.g. Aesculap FF015P) and Sugita frame fish hooks
- Craniotomy instruments (e.g. Aesculap HiLAN XS drill system)
- Small cotton buns on Kocher clamp (e.g. Aesculap BF444R)
- Vicryl take-off sutures in the lower muscular layer for closure

- **May need:**

- Nicola Tumor clamp (e.g. Aesculap OF442R)
- Kerrison bone punch, noir, detachable, 2mm (e.g. Aesculap FK907B)
- Micro Scissors curved right
- Long DIADUST micro needle holder (e.g. Aesculap BM327R)
- His own long micro instruments
- Long suction cannulae (e.g. Aesculap GF413R, GF415R)
- Long irrigation tips
- "Black Rudolf" tumor clamp 23 - 01049
- Large long ring forceps (e.g. Aesculap FD216R)

- Small long ring forceps (e.g. Aesculap FD214R)
- Long micro hook, semi-sharp, 23 cm (e.g. Aesculap FD330R)
- Long micro hook, blunt, 23 cm (e.g. Aesculap FD331R)
- YASARGIL Coagulation Forceps 21.5 cm (e.g. Aesculap GK775R)
- YASARGIL Coagulation Forceps 23.5 cm (e.g. Aesculap GK791R)
- YASARGIL Micro Scissors straight (e.g. Aesculap FD038R)
- YASARGIL Micro Scissors curved (e.g. Aesculap FD061R)

### **Aneurysm surgery**

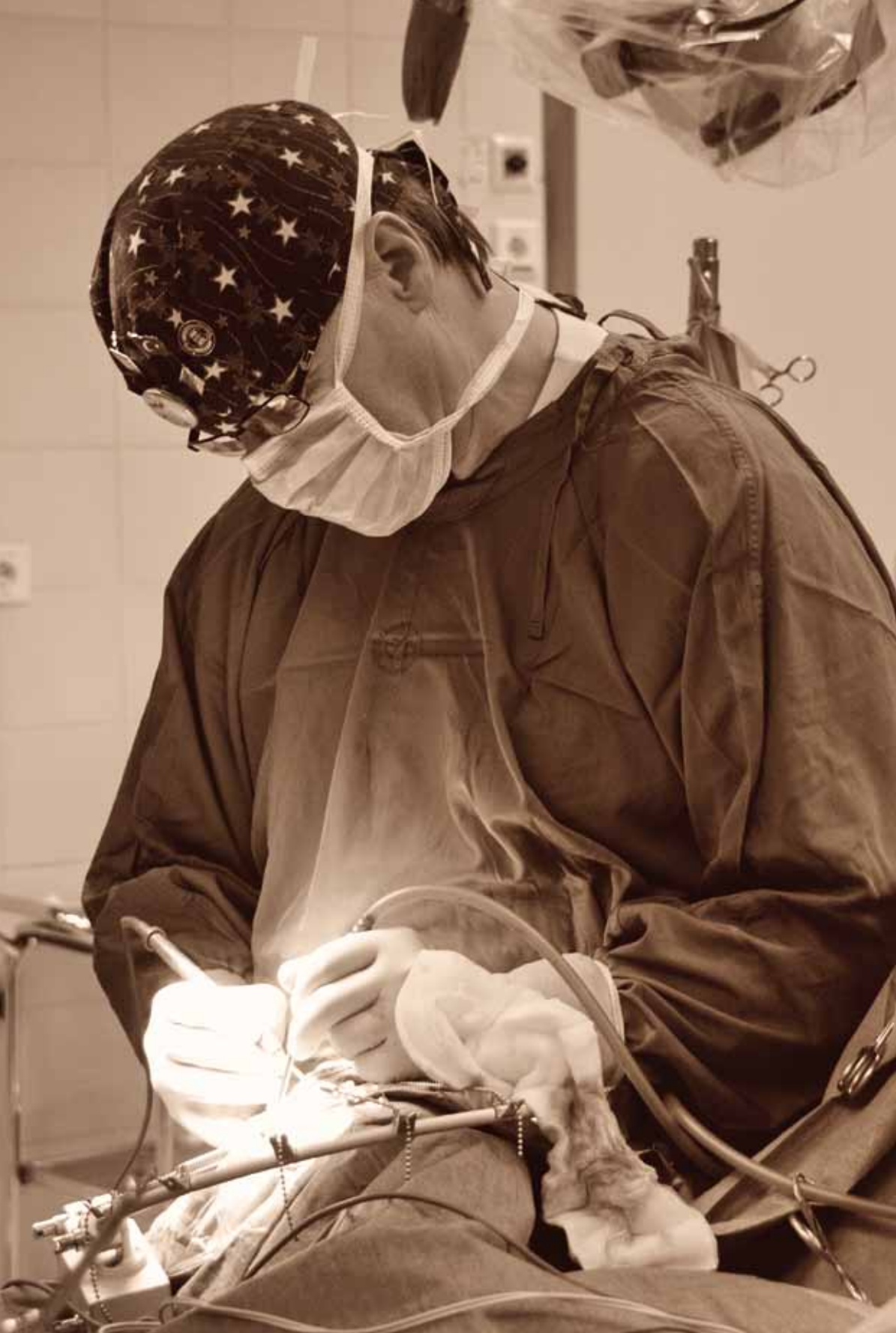- YASARGIL MINI Aneurysm Clips (e.g. Aesculap FT690T, FT720T etc.)
- YASARGIL STANDARD Aneurysm Clips (e.g. Aesculap FT760T, FT740T etc.)
- Papaverin
- Double Bayonet Clip Applier without latch (e.g. Aesculap FT515T, FT516T)

### **May need:**

- Second suction
- YASARGIL Titanium Fenestrated Clips (e.g. Aesculap FT640T, FT597T etc.)
- Might lift tentorium with a YASARGIL MINI temporary Aneurysm Clip (e.g. Aesculap FT210T)
- Histoacryl Blue (B.Braun1050044) "childrens glue" for wrap-ping
- If aneurysm cannot be fully clipped -> 7-0 or 8-0 suture and micro needleholders (e.g. Aesculap FD245R, FD247R, FD092R, FD093R, FD120R)
- MCA aneurysms -> YASARGIL STANDARD Clip Applier (e.g. Aesculap FT480T, FT470T)

### **AVM surgery**

- Equipment like in aneurysm surgery
- Kopitnik AVM Microclip (e.g. Aesculap FE902K, FE914K etc.)
- AVM Clip Applier (e.g. Aesculap FE917K, FE918K)
- Bypass micro instruments
- Lots of fibrin glue (e.g. B. Braun Tisseel Duo Quick)



## 5. COMMON APPROACHES

*Each of the described approaches is also demonstrated on supplementary videos, please see Appendix 2.*

### 5.1. LATERAL SUPRAORBITAL APPROACH

The most common craniotomy approach used in Helsinki by Prof. Hernesniemi is certainly the lateral supraorbital (LSO) craniotomy. The LSO has been used in more than 4,000 operations to access vascular pathologies of the anterior circle of Willis as well as extrinsic and intrinsic tumors of the anterior fossa and basal regions of the frontal lobes. The LSO approach is a more subfrontal, less invasive, simpler and faster modification of the classical pterional approach by Yaşargil. The LSO utilizes smaller incision, it dispenses with the laborious subfacial dissection and involves taking a smaller free bone flap which has less temporal extension than the pterional bone flap.

In the LSO approach the skin-muscle flap is opened as a one layer block and only the anterior portion of the temporal muscle is split open. The partial split of the temporalis muscle has ensured very little risk of problems with the temporomandibular joint, mastication and mouth opening, and late disfiguring muscle atrophy. The facial branch to the frontalis muscle is not damaged as it is not exposed, dissected or cut during the craniotomy. Due to relatively short skin incision and a small bone flap the closure is also simpler. The Finnish people have generally thin and light eyebrows. This precludes the possibility of using an eye-brow incision.

#### 5.1.1. Indications

The LSO approach can be used to access all aneurysms of the anterior circulation, except those of the distal anterior cerebral artery. The LSO approach can be used also for high positioned basilar bifurcation or even basilar-SCA aneurysms. In addition to aneurysms, LSO approach can be used for most pathologies involving the sellar and suprasellar region, and tumors of the anterior cranial fossa and sphenoid ridge. The LSO approach is our preferred route to enter the Sylvian fissure and the pathologies that can be accessed through there. It gives excellent access to the anterior portion of the Sylvian fissure and by extending the craniotomy more in the posterior and temporal direction also the distal part of the Sylvian fissure can be visualized. By adjusting the exact location of the LSO craniotomy, one can achieve either a more frontal or a more temporal exposure. This combined with well-planned head positioning provides usually an excellent accesses to nearly all of the above mentioned pathologies with ease.

### 5.1.2. Positioning

The patient is positioned supine with shoulders and head elevated above the cardiac level. The head, fixed with 3 or 4 pins to the head frame is: (a) elevated clearly above the cardiac level; (b) rotated 15 to 30 degrees toward the opposite side; (c) tilted somewhat laterally; and (d) extended or minimally flexed (Figure 5-1a,b). We prefer to use a Sugita head frame with 4-point fixation. Besides providing good retraction force by its spring hooks, it allows the surgeon to rotate the head during microsurgery. If this feature is not available, the table can be rotated as needed. The head orientation is to allow for a comfortable working angle, downward and somewhat forward. Nevertheless, the position of the head and body is subject to frequent changes as necessary during the whole operation. The exact positioning of the head depends on the pathology being approached and is adjusted on case-by-case

basis. One has to imagine the exact location and orientation of the lesion in 3D space to plan the optimal head position. In general, the head is rotated less to the opposite side than in standard pterional approach. If the head is rotated too much, the temporal lobe obstructs easy access into the Sylvian fissure. The extension of the head depends on the cranio-caudal distance of the pathology from the base of the anterior cranial fossa. The higher the lesion is, the more the head needs to be extended. The upper limit of the access is 15 mm from the anterior skull base in the chiasmatic region. On the other hand, for lesions near the skull base little flexion might be needed. Lateral tilt is used to orientate the proximal part of the Sylvian fissure almost vertical, which helps in exposing the proximal middle cerebral artery and the internal carotid artery.

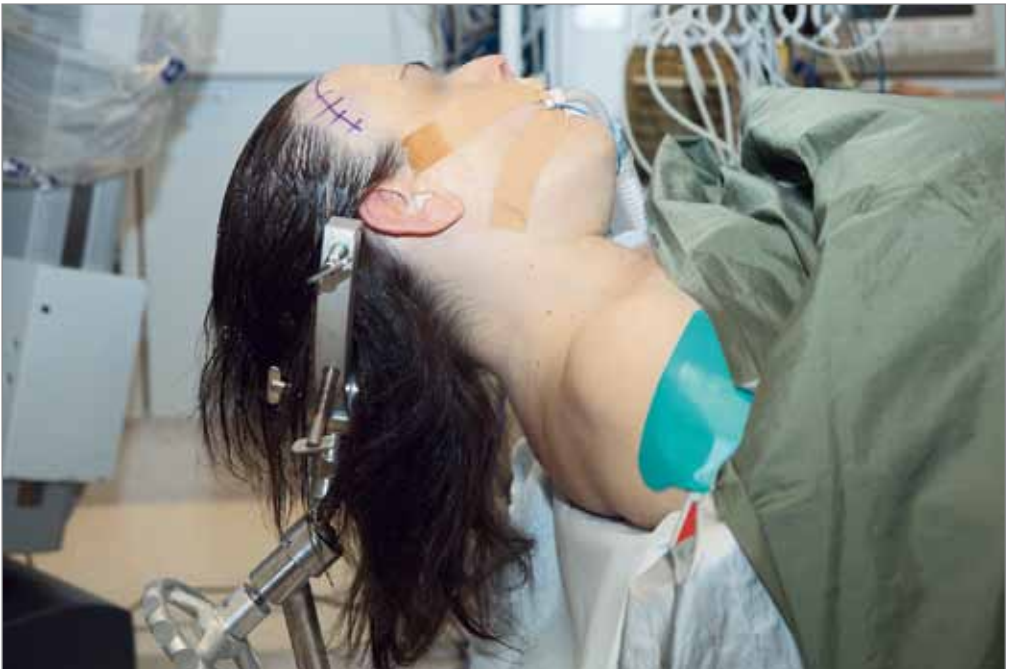

Figure 5-1 (a). Lateral supraorbital approach. See text for details





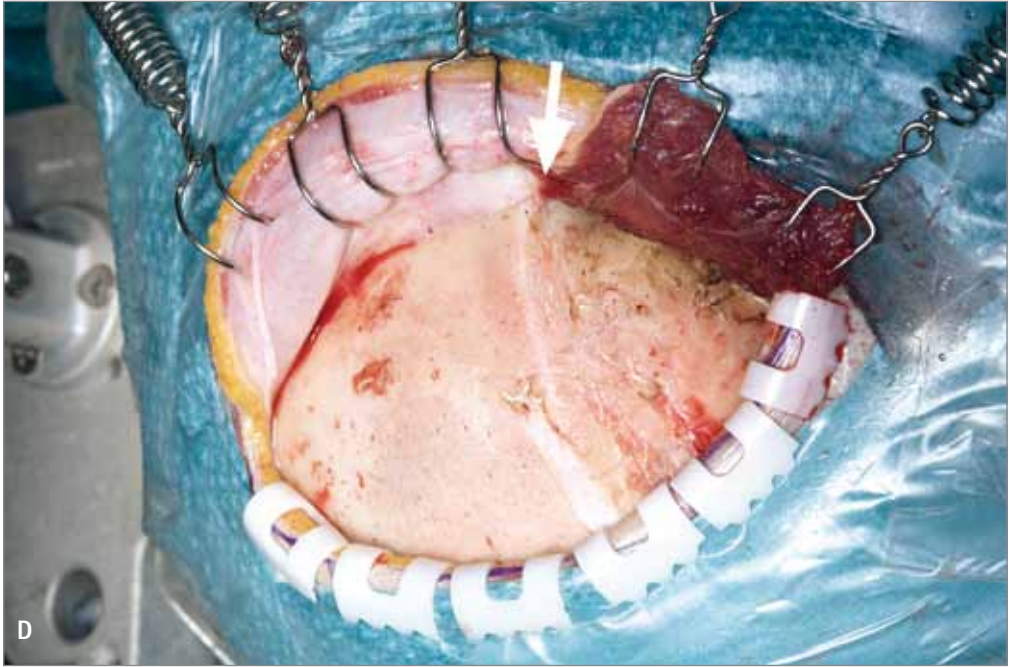
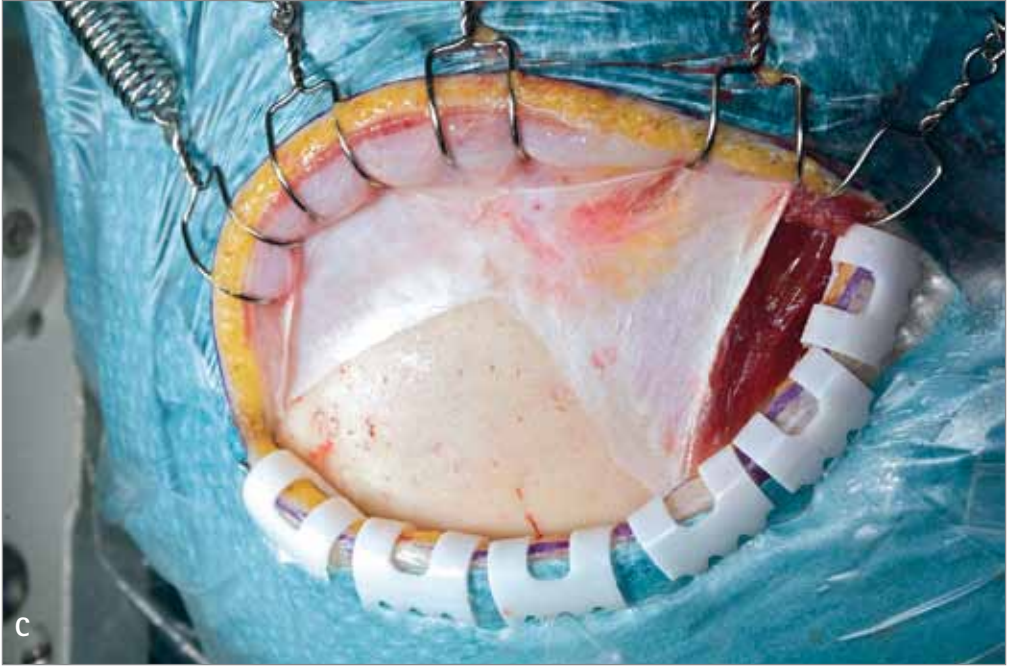


Figure 5-1 (c - d). Lateral supraorbital approach. See text for details

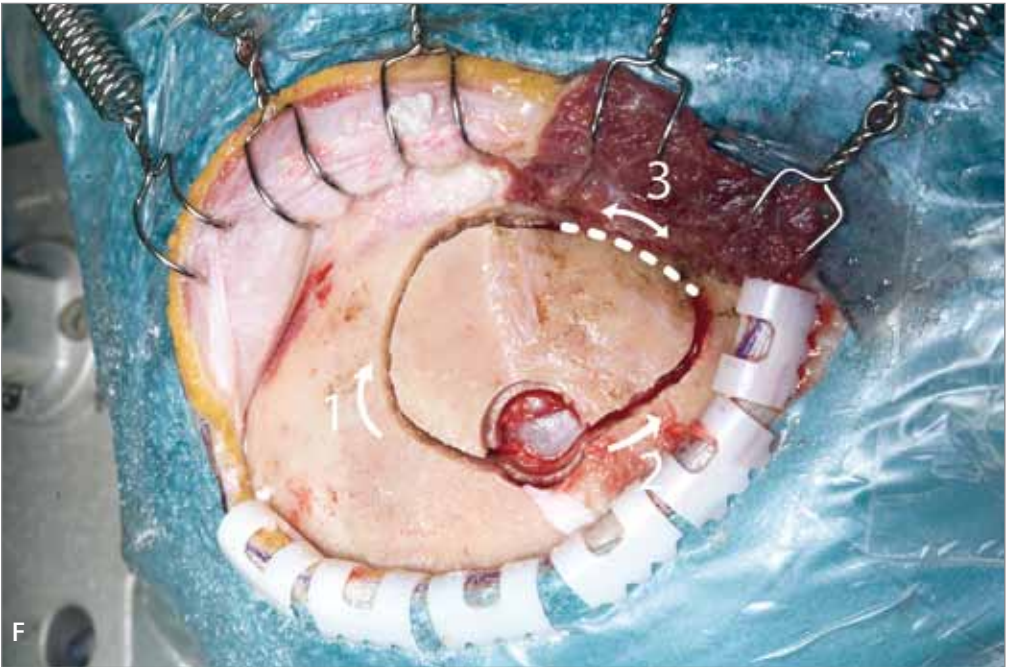
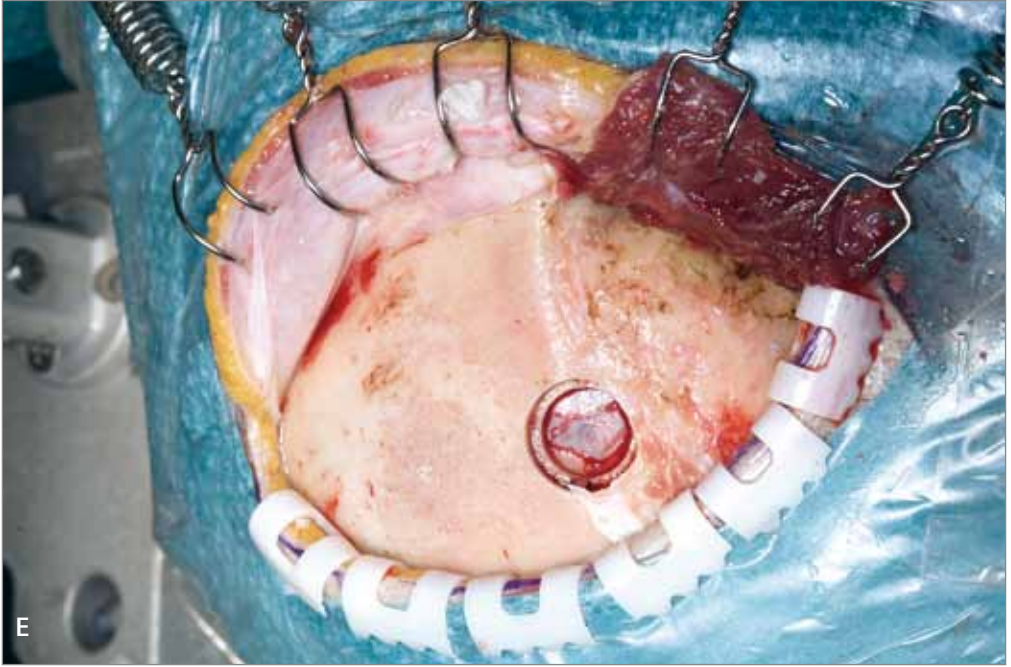


Figure 5-1 (e - f). Lateral supraorbital approach. See text for details

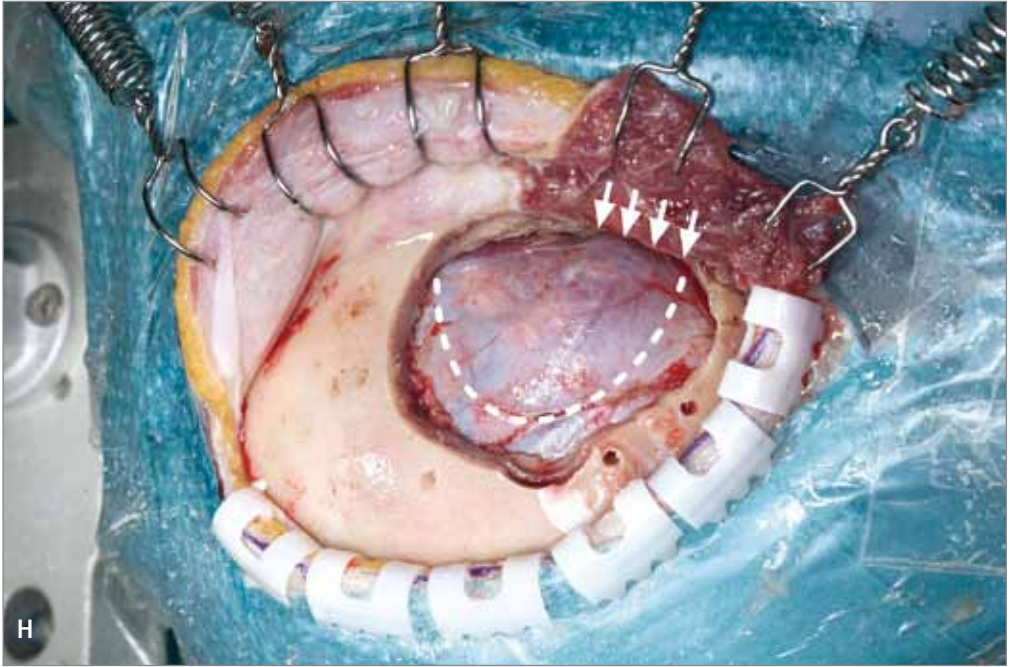
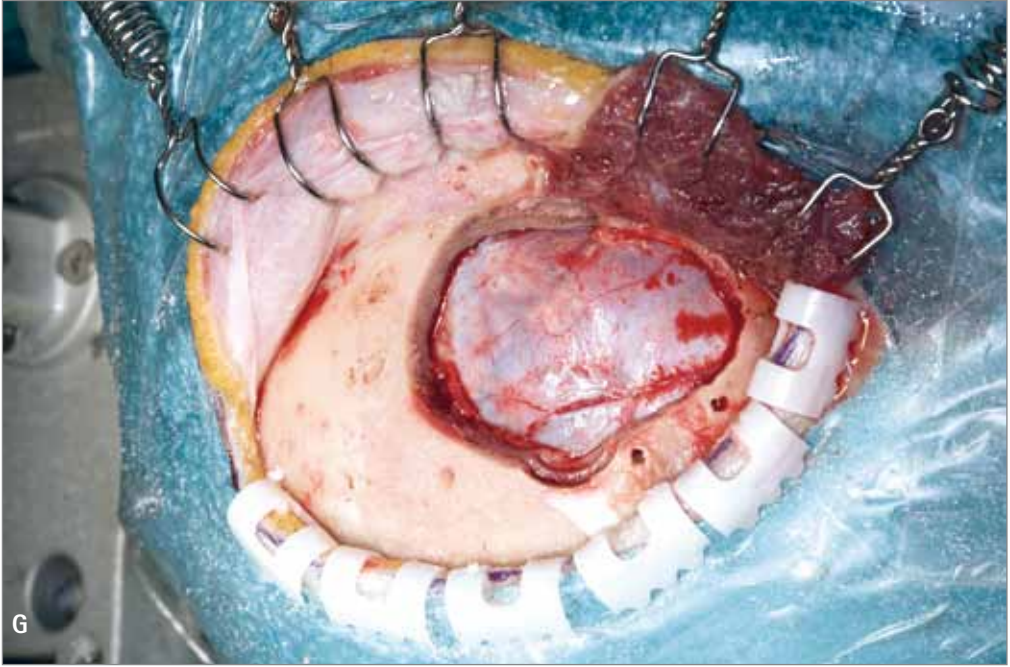


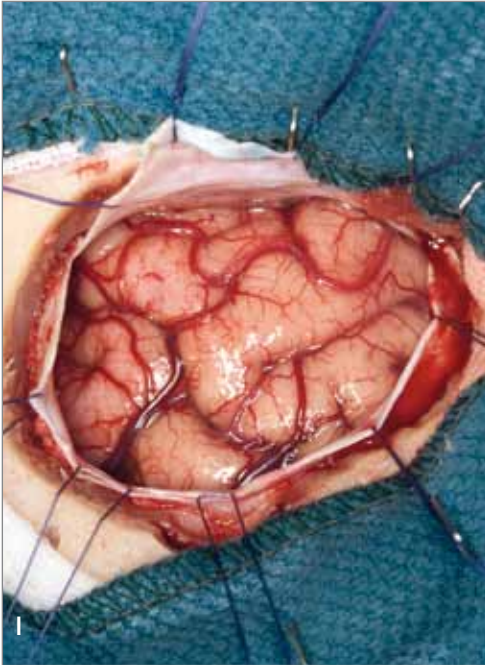
Figure 5-1 (g - h). Lateral supraorbital approach. See text for details

for tack-up sutures. The lateral sphenoid ridge is then drilled off allowing access to the skull base (arrows; Figure 5-1h). The drilling starts with a high-speed drill and continues with a diamond drill. Oozing of blood from the bone is finally controlled by "hot drilling", i.e. using a diamond tipped drill without irrigation heating the bone and sealing the bleedings. The wound is irrigated, and hemostasis is achieved using bipolar, Surgicel and cottonoids.

The dura is opened using a curvilinear incision pointing anterolaterally (dotted line; Figure 5-1h), the dural edges are elevated by multiple stitches, extended over craniotomy dressings (Figure 5-1i). This prevents oozing from the epidural space. From this point on, all surgery is performed under the operating microscope, including the skin closure.

The first goal during intradural dissection is usually to reach basal cisterns for CSF release

and brain relaxation. The dissection starts along the frontobasal surface of the frontal lobe slightly medially from the proximal Sylvian fissure. The first aim is to reach the optic nerve and its entrance into the optic canal. The arachnoid membranes limiting the optic cistern are opened and CSF is released. For further CSF release also the carotid cistern on the lateral side of the optic nerve is entered. With the brain relaxed the dissection continues according to the pathology. In situations with very tight brain and little CSF in the basal cisterns, as e.g. in acute SAH, we try to remove more CSF by opening the lamina terminalis. To reach the lamina terminalis, we continue with the dissection subfrontally, along the ipsilateral optic nerve towards the optic chiasm. This dissection step is often complicated by lack of space and requires high magnification. The frontal lobe can be gently retracted by tandem work of bipolar forceps and suction to reach the gray-bluish membrane of the lamina terminalis just posterior to the optic chiasm. The translucent membrane is punctured with sharp bipolar forceps or closed microscissors and further CSF is released directly from the third ventricle. The dissection then continues as planned.



#### T&T:

- Accurate head positioning, imagine in 3D how the lesion is situated inside the head
- Short incision centered on the orbitocranial joint
- One layer skin-muscle flap, one hook retracts incised muscle downward
- One burr hole at the temporal line
- Bone removed basally to minimize retraction, diamond drill stops bleeding from bone
- Brain is relaxed by releasing CSF from basal cisterns and further through lamina terminalis

Figure 5-1 (i). Lateral supraorbital approach. See text for details

## 5.2. PTERIONAL APPROACH

The pterional approach we have adopted is a slight modification of the classical pterional approach as described by Yaşargil. The biggest differences are: (a) the skin incision is slightly different, it starts closer to the midline; (b) we use a one-layer skin-muscle flap instead of several layers; (c) only one burr hole is used at the superior insertion of the temporal muscle; and (d) we do not remove bone all the way down to the anterior clinoid process or perform extradural anterior clinoidectomy routinely.

### 5.2.1. Indications

Most of the lesions for which pterional approach has been classically used, are treated in our hands using the LSO approach. The pterional approach is reserved only for those situations where wider exposure of both the frontal and temporal lobes as well as the insula is necessary and where we anticipate lack of space during the surgery. Such situations are giant anterior circulation aneurysms, especially MCA aneurysms, AVMs close to the Sylvian fissure or insular tumors.

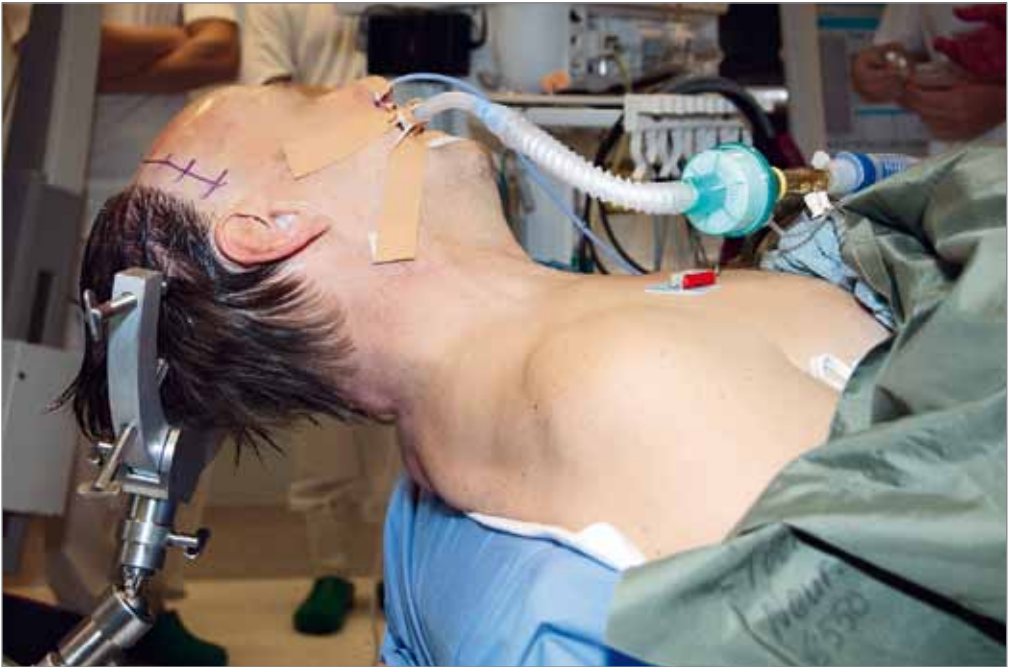

Figure 5-2 (a). Pterional approach. See text for details.

### 5.2.2. Positioning

The positioning for the pterional approach is almost identical to that for the LSO approach (see section 5.1.2.) (Figure 5-2a,b). The angle of approach is the same, the only difference is that pterional approach provides a wider bony window.

### 5.2.3. Incision and craniotomy

The head is shaved about 2 cm along the hairline. The skin incision is planned to start just behind the hairline at the midline. It then extends in a slightly oblique fashion and terminates in front of the ear, close to the level of zygoma (Figure 5-2a,b). Compared to the LSO approach the skin incision is: (a) longer; (b) curves little more posterior; and (c) extends several centimeters closer to the zygoma.

The opening is carried out in a single layer like in the LSO approach. The temporal muscle is split along the muscle fibers and spring hooks are placed to retract the skin-muscle flap in the fronto-basal direction (Figure 5-2c). Raney clips are used along the posterior wound edge. The temporal muscle is detached from the bone with diathermia. The retraction of the hooks is increased so that, finally, the superior orbital rim and the anterior zygomatic arch are exposed (arrow; Figure 5-2c). A groove in the bone marks the expected location of the Sylvian fissure and the borderline in between the frontal and the temporal lobes (blue dotted line; Figure 5-2c).

A single burr hole is placed just beneath the temporal line (Figure 5-2d). The dura is carefully detached first with a curved dissector and

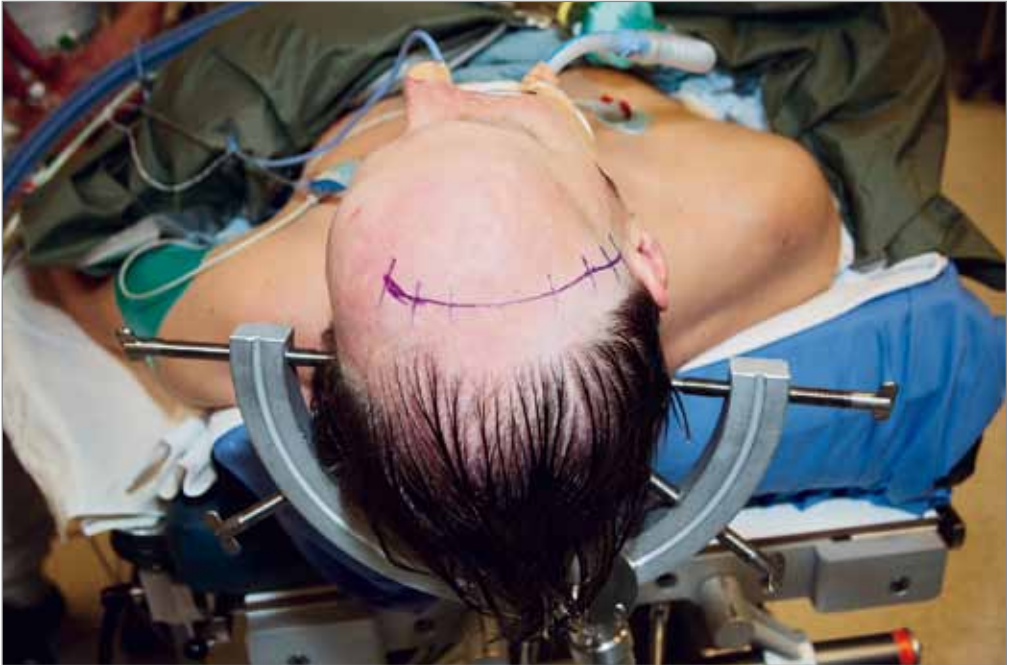

Figure 5-2 (b). Pterional approach. See text for details.

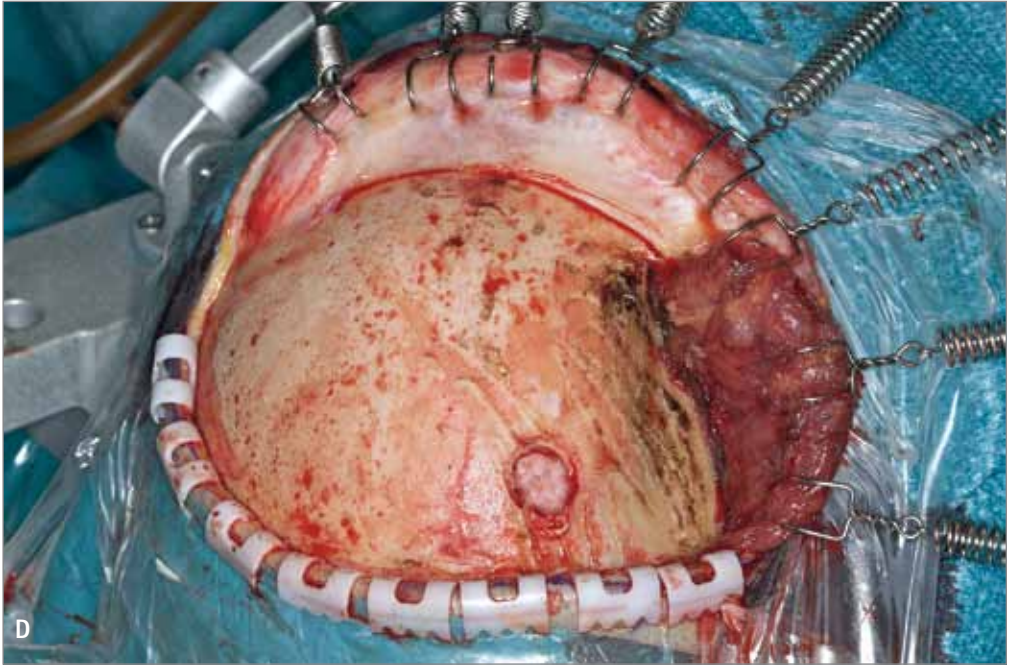
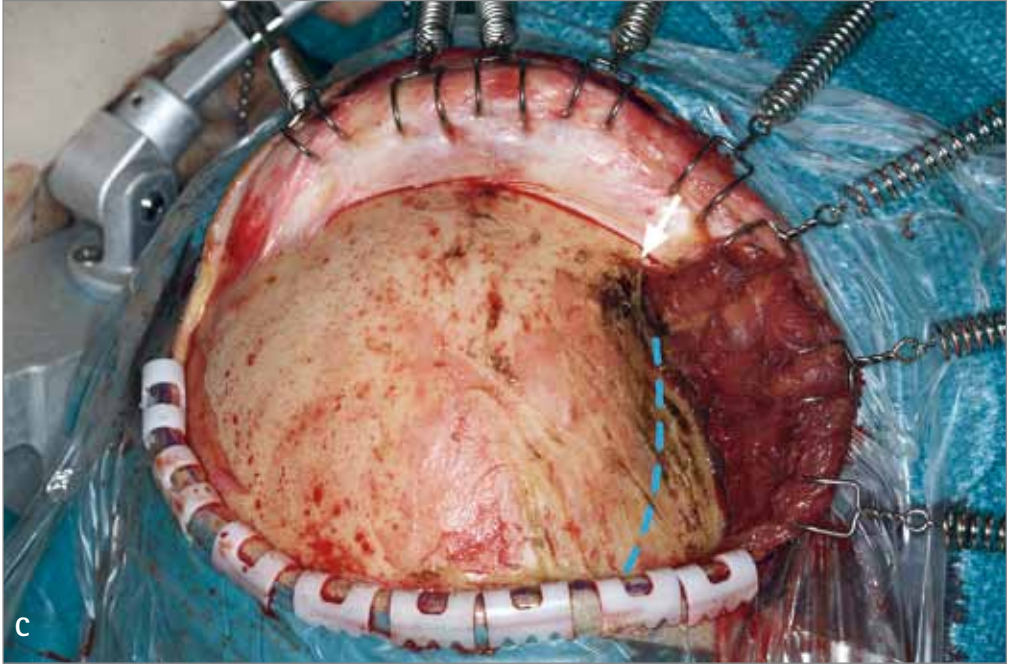


Figure 5-2 (c - d). Pterional approach. See text for details.



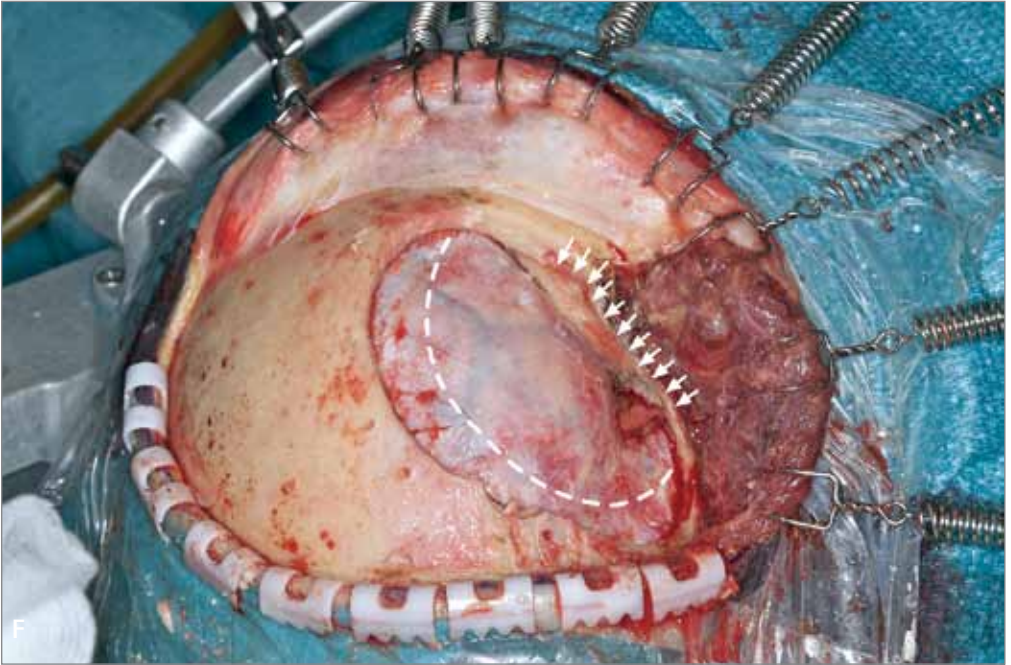
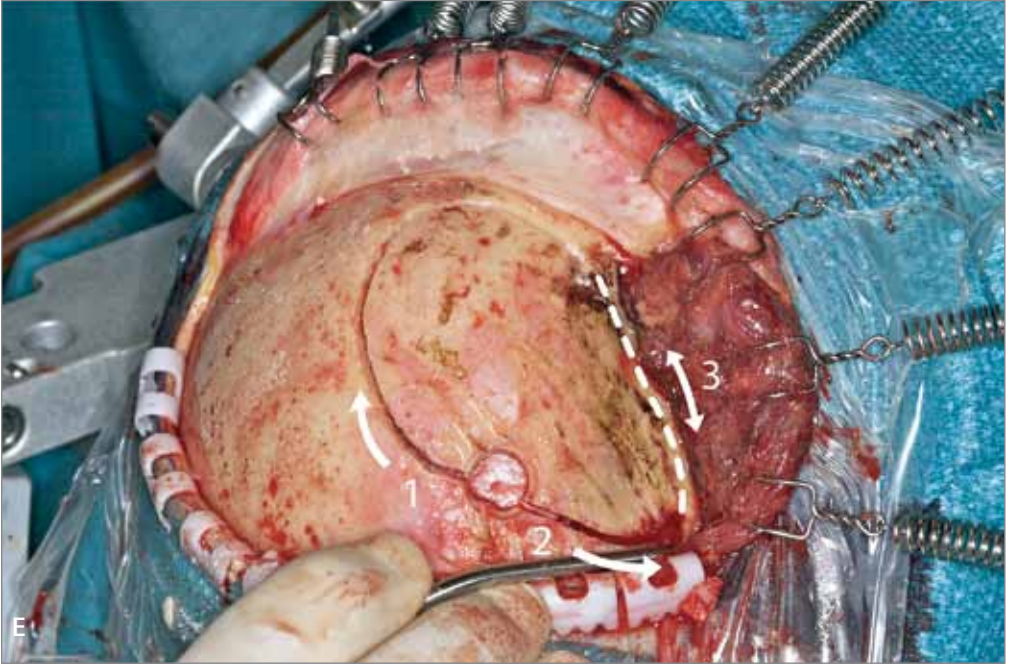

Figure 5-2 (e - f). Pterional approach. See text for details.

then with a flexible (Yaşargil-type) dissector (Figure 4-11b - page 92). Since the bone flap is going to be larger than in the LSO approach, the dura needs to be detached more extensively especially in the temporal direction. Two cuts are made with a craniotome. The first one curves medially and frontobasally and terminates at the sphenoid ridge just after passing the origin of the anterior zygomatic arch. The other cut is directed in the temporal direction almost in a straight line and then curves slightly in the temporobasal direction, towards the zygoma (Figure 5-2e). Finally, the bone is thinned basally over the sphenoid ridge, connecting the two cuts. This is done with the craniotome without the footplate. The bone is cracked and lifted. Before cracking the bone, few drill holes are made for tack-up sutures. Once the bone flap has been removed, the dura is detached further in the basal direction on both sides of the sphenoid ridge. The sphenoid ridge is then drilled away with a high-speed drill (arrows;

Figure 5-2f). Hot drilling with a diamond drill bit is used to seal the small bleedings from the bone. We do not remove the anterior clinoid process.

The dura is opened in a curvilinear fashion with the base in the fronto-basal direction (Figure 5-2f). The dural edges are elevated over the craniotomy dressings with tight lift-up sutures to prevent oozing from the epidural space (Figure 5-2g). Compared to the LSO approach, we see now more of the temporal lobe and the craniotomy extends also little further posterior.

Under the microscope, the first aim is to relax the brain by removing CSF from the basal cisterns and if necessary, from the third ventricle through the lamina terminalis as with the LSO approach. The dissection then proceeds according to the pathology in question, often involving opening of the Sylvian fissure (see section 6.1.6.).

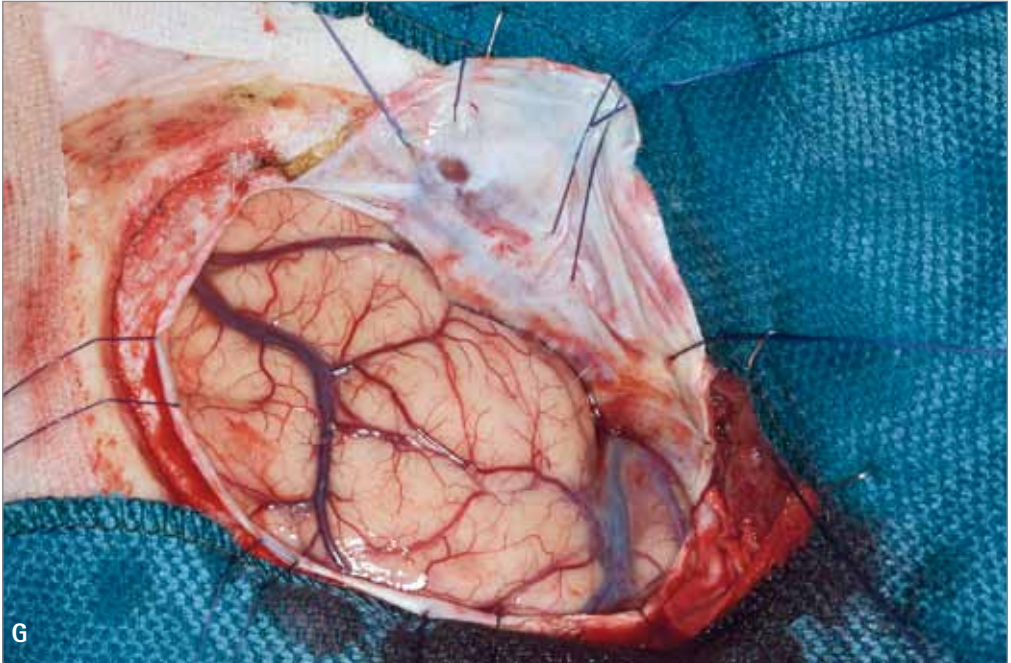


Figure 5-2 (g). Pterional approach. See text for details.

The closure is performed in the standard layer-like fashion in the similar way as for the LSO approach.

*T&T:*

- *Head positioning according to the pathology*
- *Skin incision behind the hairline*
- *Skin and muscle detached in one layer*
- *Only one burr hole necessary*
- *Dura carefully detached before using the craniotome*
- *Sphenoid ridge removed with high speed drill, and hot drilling*
- *No need for routine anterior clinoidectomy*

### 5.3. INTERHEMISPHERIC APPROACH

The interhemispheric approach is used to gain access into the space in between the two hemispheres in the midline on either side of the falx and, if necessary, through the transcallosal route also into the lateral ventricles and the third ventricle. The important aspect regarding the interhemispheric approach is the absence of good anatomical landmarks once inside the interhemispheric space. The falx and the plane between the cingulate gyri mark the midline but estimating the antero-posterior direction is very difficult and one might get easily lost. It is necessary to know the exact head orientation and to check the angle of the microscope to estimate the appropriate angle of approach. The neuronavigator can be helpful in planning the trajectory.

#### 5.3.1. Indications

The most common lesions to be operated via interhemispheric route are distal anterior cerebral artery aneurysms and third ventricle colloid cysts. In addition certain rare pathologies such as very high located craniopharyngiomas or other pathologies of the third ventricle and those of the lateral ventricles can be accessed via this route as well. Parasagittal or falx meningiomas are also approached in this way but the craniotomy usually needs to be more extensive, dural incision and possible removal must be planned in advance. In addition, possible tumor infiltration into the superior sagittal sinus plays a major role.

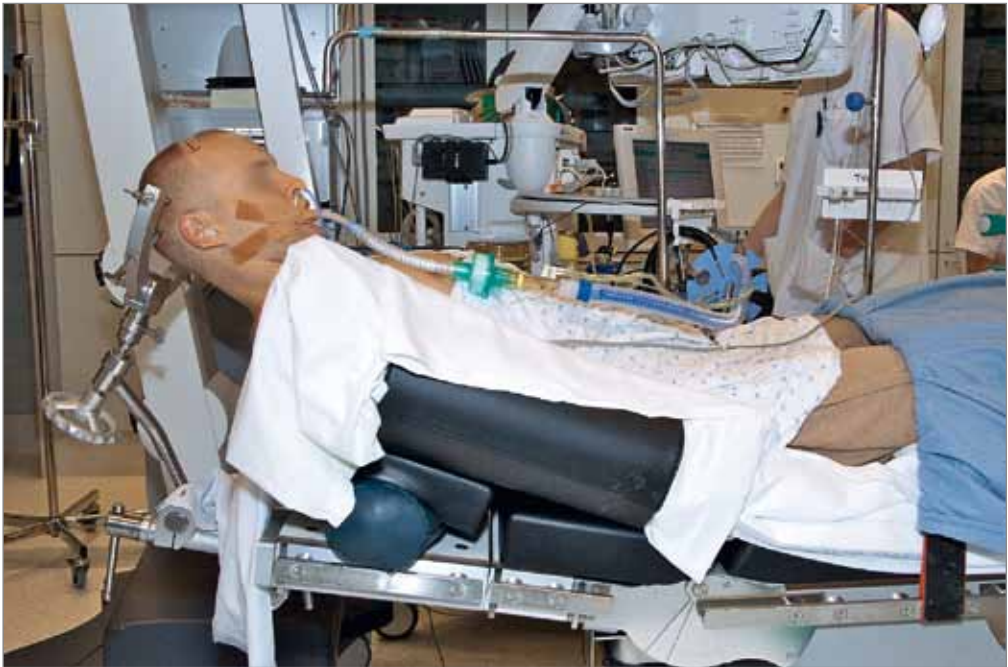

Figure 5-3 (a). Interhemispheric approach. See text for details.

### 5.3.2. Positioning

For the anterior interhemispheric approach the patient is placed in supine position, a stiff pillow beneath the shoulders, with the head fixed in a head frame and elevated about 20° above the heart level. The head should be in neutral position with the nose pointing exactly upwards (Figure 5-3a,b). Tilting the head to either side increases the risk of placing the bone flap lateral from the midline. This would make both entering into the interhemispheric fissure as well as navigating inside it more difficult. The head is slightly flexed or extended according to the exact location of the pathology (Figure 5-3a). In the optimal position the surgical trajectory is almost vertical.

### 5.3.3. Incision and craniotomy

After minimal shaving, a slightly curved skin incision with its base frontally is made just behind the hairline, over the midline (arrow; Figure 5-3b), extending more to the side of the planned bone flap. This incision is used for most pericallosal aneurysms, and third ventricle colloid cysts. For approaches behind the coronal suture a straight incision along the midline is used. Exact location, curvature, and extent of the skin incision depends on the hairline, dimensions of the frontal sinuses, and location of the pathology. A one-layer skin flap is reflected frontally with spring hooks (Figure 5-3c). A bicoronal skin incision is unnecessary since strong retraction with hooks often allows for an anterior enough exposure of the frontal bone.

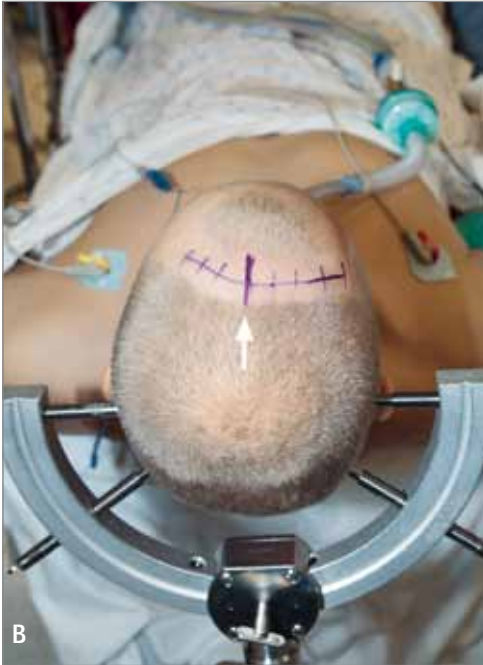


Figure 5-3 (b). Interhemispheric approach. See text for details.

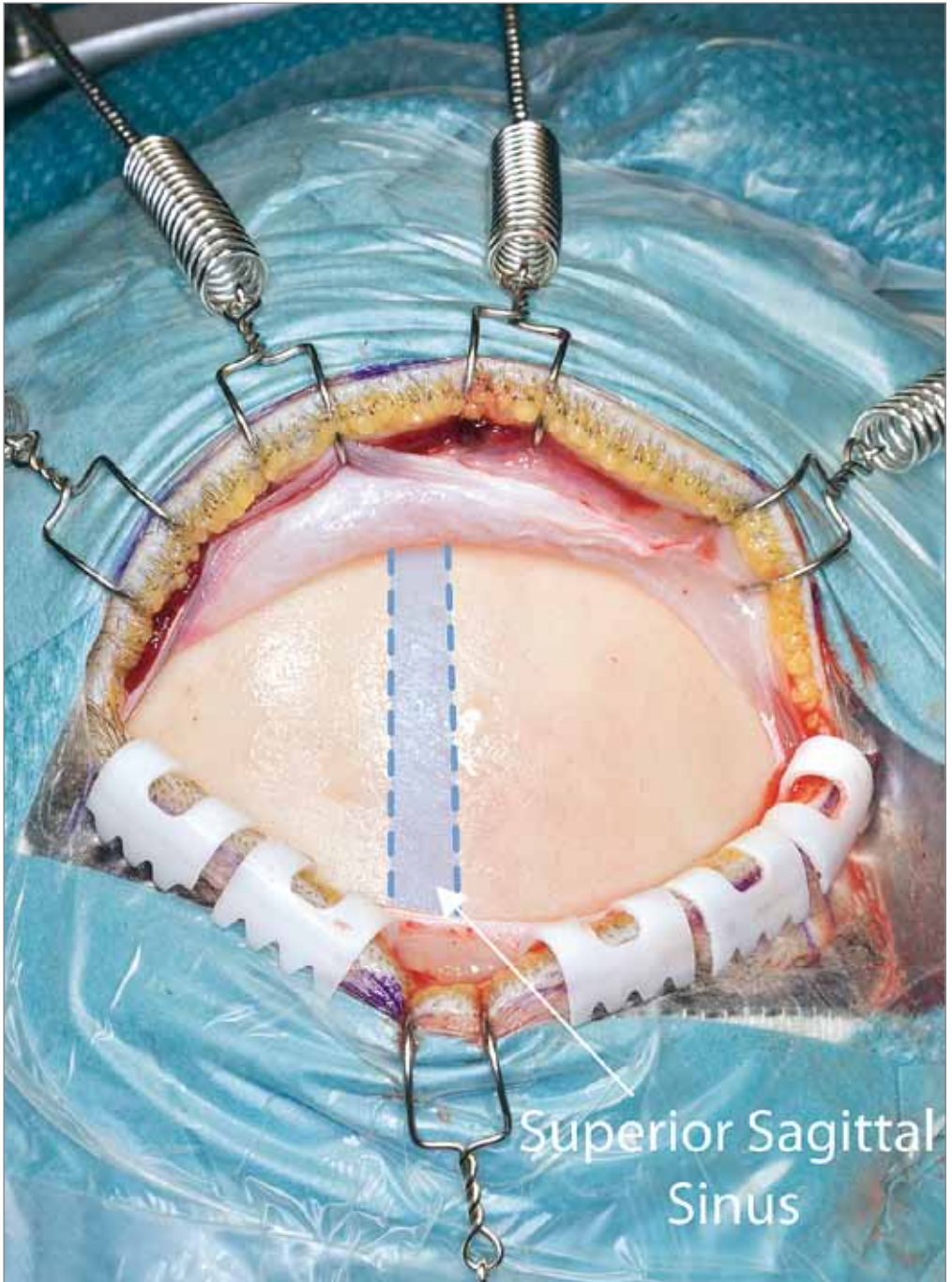


Figure 5-3 (c). Interhemispheric approach. See text for details.

The bone flap is placed slightly over the midline to allow better retraction of the falx medially. The superior sagittal sinus may deviate laterally from the sagittal suture as far as 11 mm. The size of the bone flap depends both on the surgeon's experience and on the size of the lesion. We usually use a 3 to 4 cm diameter flap. Too small a flap may not provide sufficient space for working between the bridging veins. In most patients, only one burr hole in the midline over the superior sagittal sinus at the posterior border of the bone flap is needed (Figure 5-3d). Through this hole, the bone can be detached from the underlying dura. One has to be careful with the underlying superior sagittal sinus, particularly in the elderly with a very adherent dura. With modern trephines we have not experienced any accidental tears in the sagittal sinus. The bone flap is removed using a side-cutting drill (Figure 5-3e). High-speed drill can be used to smoothen the edges or to enlarge the opening if necessary. If the frontal sinuses are accidentally opened during the craniotomy, they should be stripped of endonasal mucosa, packed and isolated with fat or muscle grafts and covered with pericranium.

The dura is opened under the operating microscope as a C-shaped flap with its base at the midline (Figure 5-3f). The incision is first made in the lateral region and then extended towards the midline in the anterior and the posterior direction to prevent opening of the superior sagittal sinus. The dural opening should be planned so that possible meningeal sinuses and venous lacunae are left intact. Bridging veins may be attached to the dura for several centimeters along the midline. Careful dissection and mobilization of these veins is necessary. It is usually during the opening of the dura that accidental damage to the bridging veins takes place. Dural edges are elevated with multiple stitches extended over the craniotomy dress-

ings to prevent epidural oozing into the surgical field (Figure 5-3g).

If the neuronavigation system is used, the correct angle of the trajectory should be verified while planning the skin incision. With the bone flap removed and the dura still intact, the approach trajectory has to be checked again for correct working angle of the microscope. After the dura has been opened and CSF released, brain shift will make neuronavigation less reliable, and one becomes more dependent on visible anatomic landmarks.

#### *T&T:*

- *The head is elevated, flexed or extended as needed, but no rotation or lateral tilt*
- *Check the head position and microscope angle before draping*
- *The neuronavigator is helpful in planning the optimal trajectory*
- *Curved incision frontally for anterior lesions, straight incision on midline for parietal and occipital lesions*
- *One burr hole in the midline over the sagittal sinus*
- *Do not sacrifice bridging veins, flap large enough to go on either side of an important vein*
- *Craniotomy should extend slightly over the midline to allow some retraction of the sagittal sinus*
- *Corpus callosum identified by white color, striae longitudinales and transverse fibres*
- *Pericallosal arteries run usually along the corpus callosum, but can be on either side of the falx*

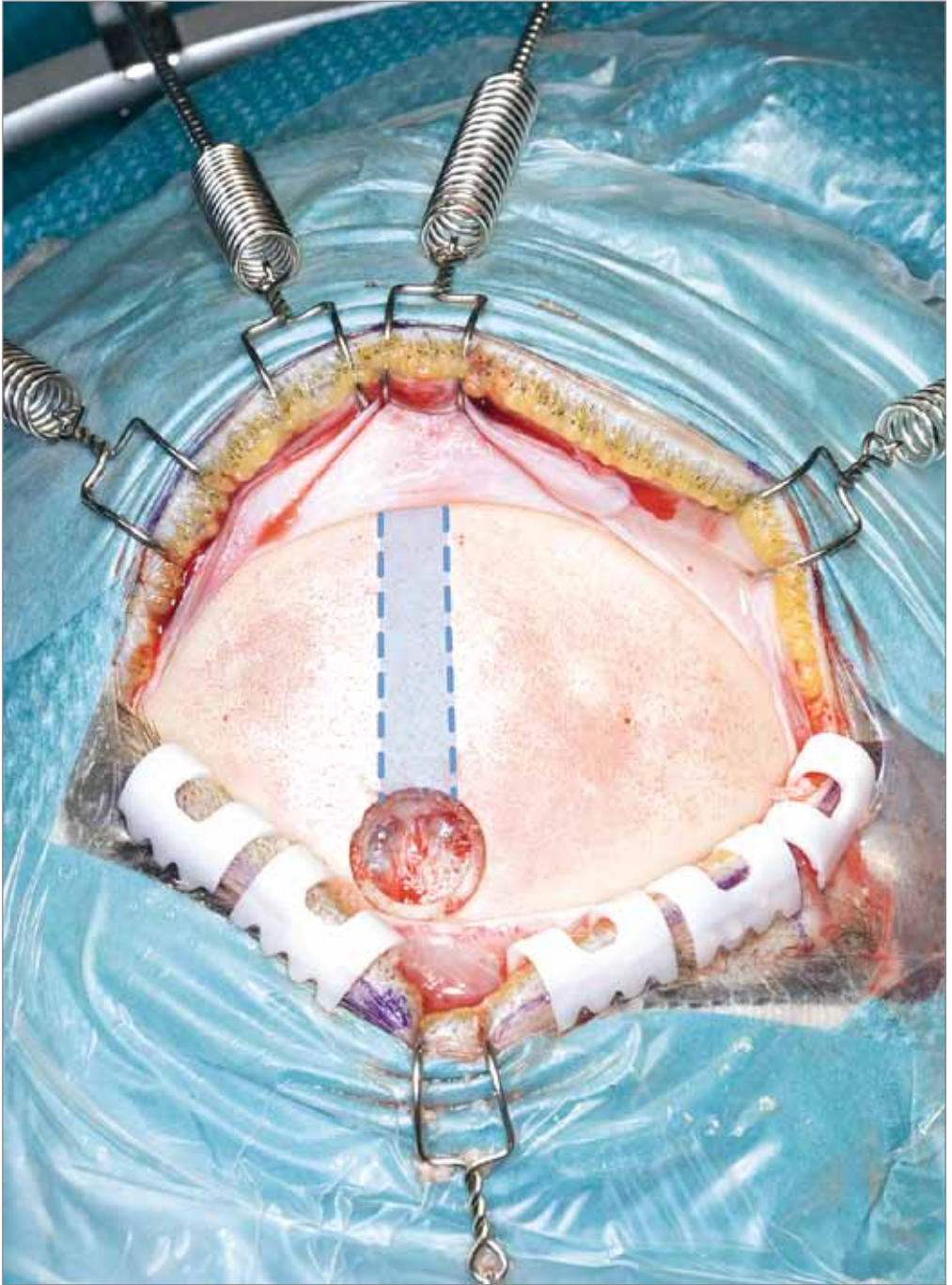


Figure 5-3 (d). Interhemispheric approach. See text for details.



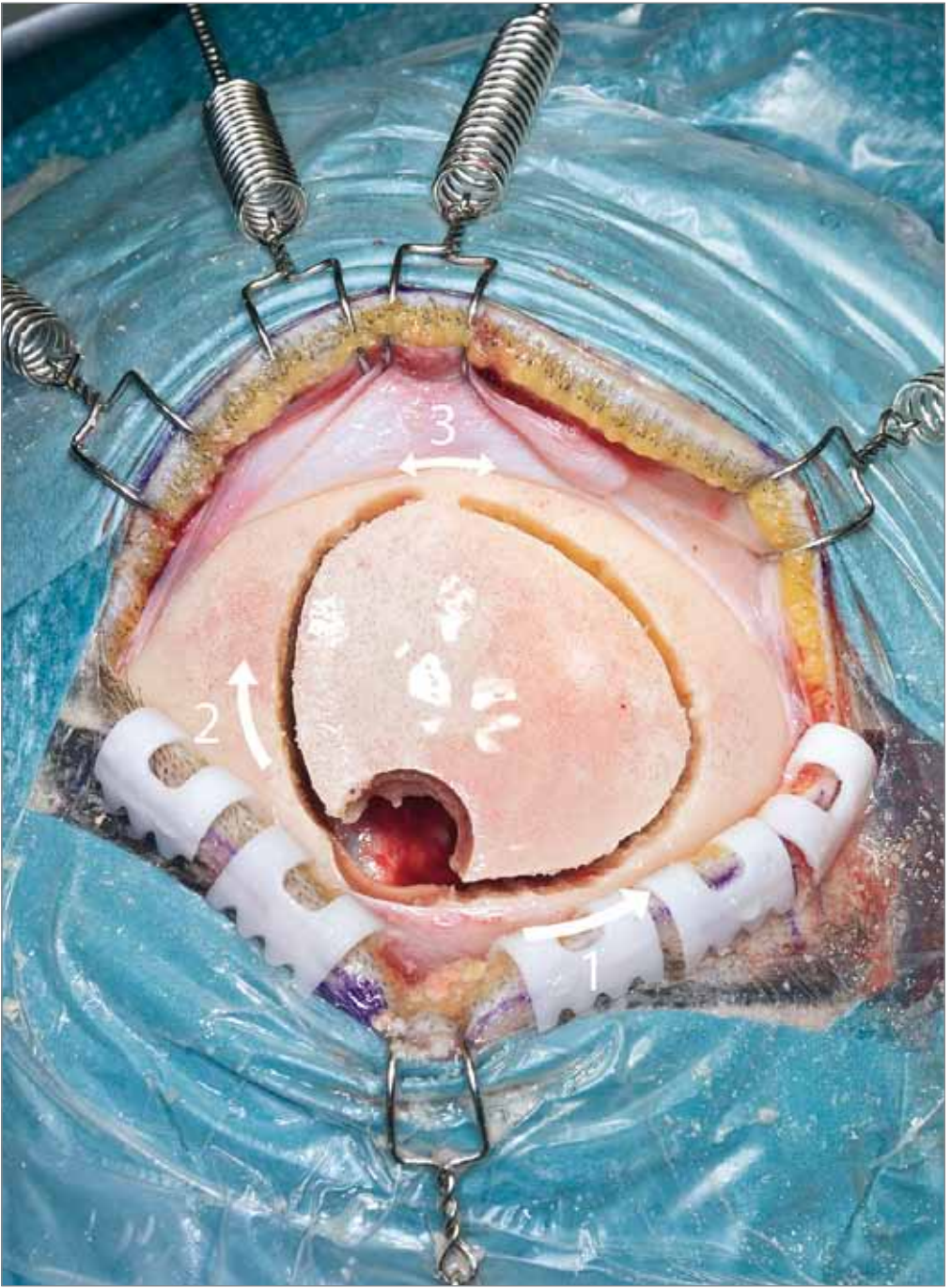


Figure 5-3 (e). Interhemispheric approach. See text for details.

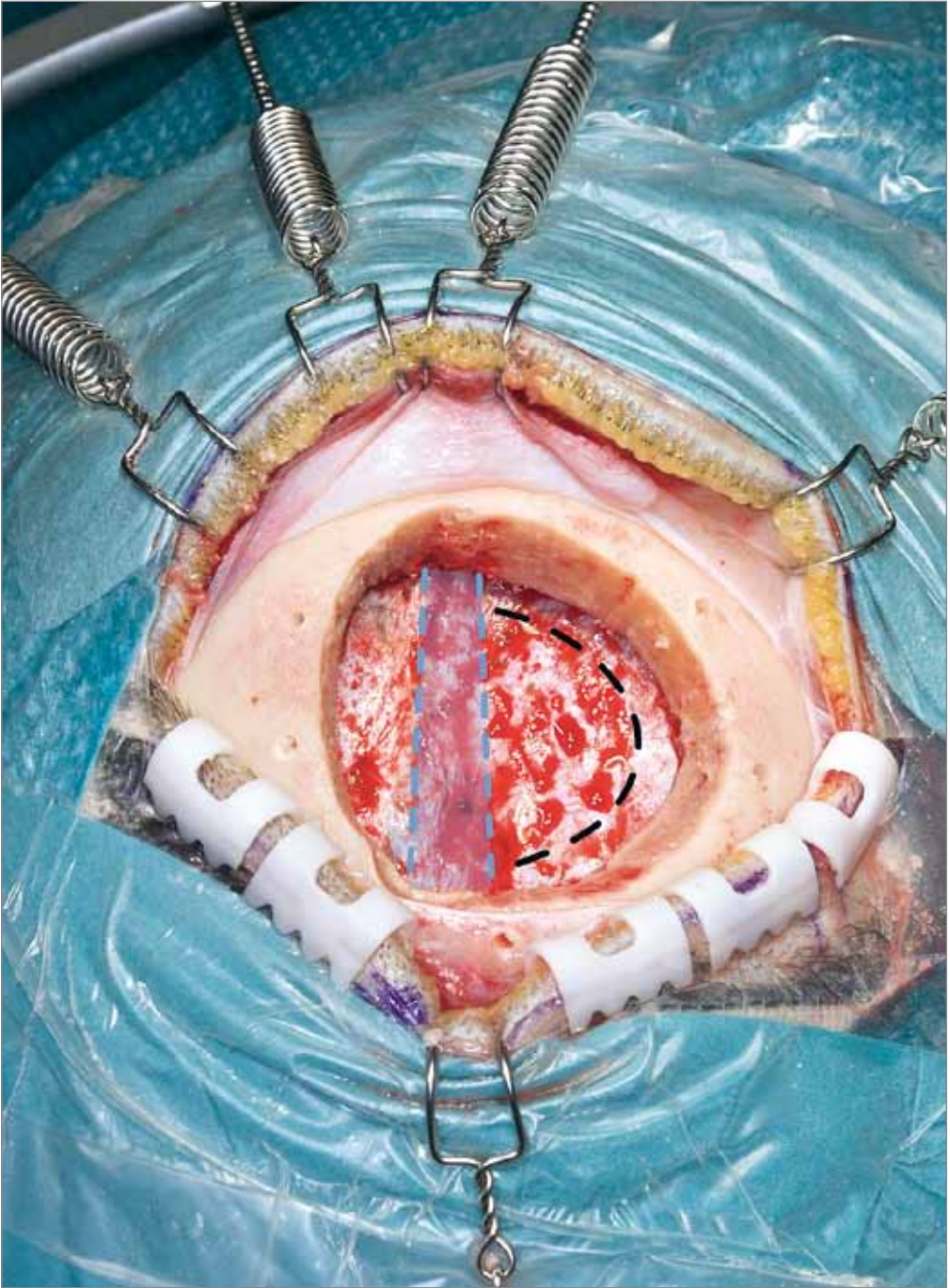


Figure 5-3 (f). Interhemispheric approach. See text for details.

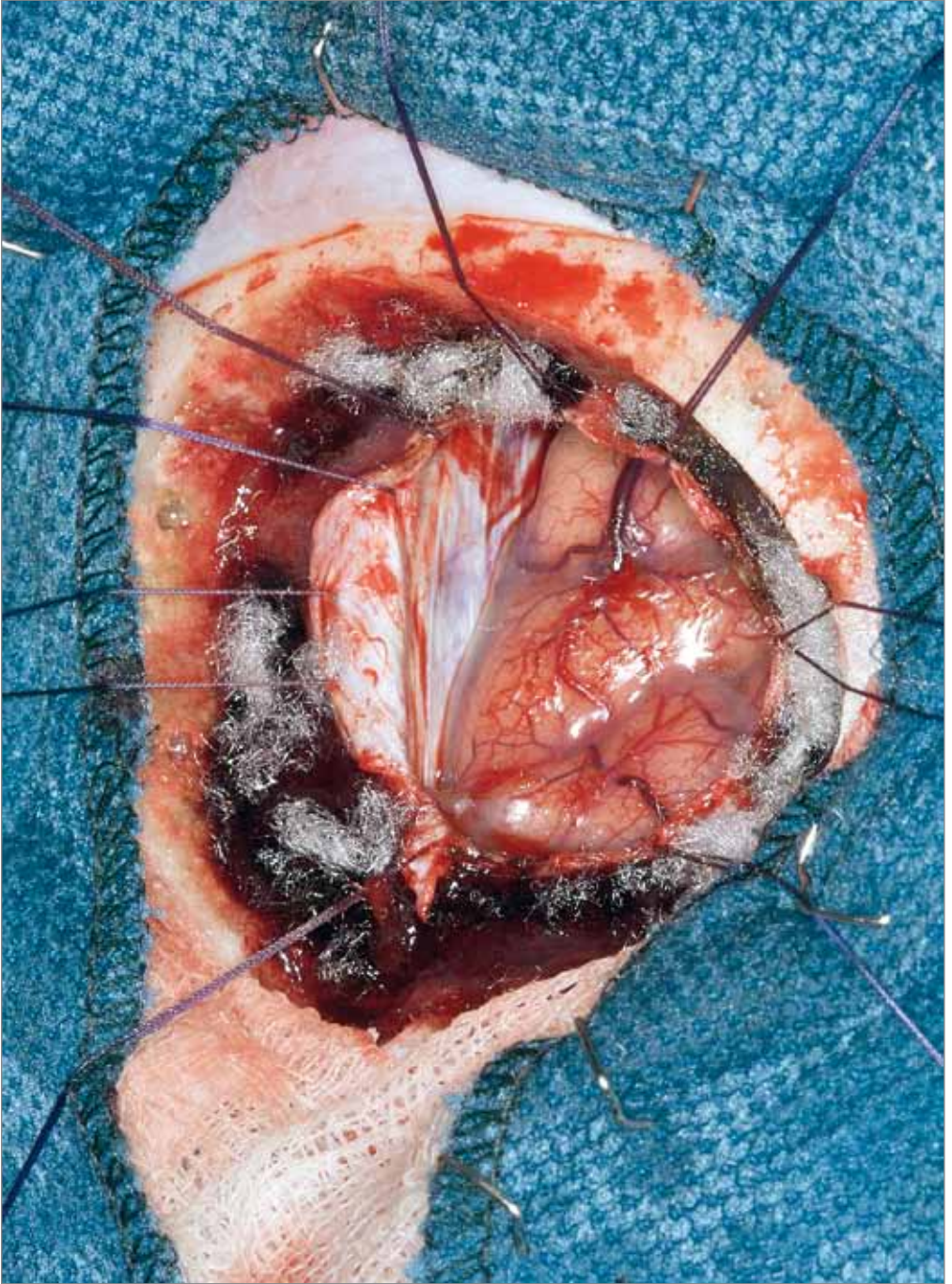


Figure 5-3 (g). Interhemispheric approach. See text for details.

## 5.4. SUBTEMPORAL APPROACH

The subtemporal approach is used mainly to access the basilar tip: basilar bifurcation, basilar-superior cerebellar artery (SCA) and posterior cerebral artery aneurysms (PCA). It gives good visualization of the interpeduncular space and also the floor of the middle fossa. Also P1 and part of the P2 segment of the PCA can be visualized with subtemporal approach. Subtemporal approach is an excellent example of how a relatively simple and fast approach without extensive bony work can be used to access similar structures as with much more complex skull base approaches.

### 5.4.1. Indications

Most basilar tip aneurysms located below the posterior clinoid process and those at the posterior clinoid or less than 10 mm above the posterior clinoid process are treated by using the subtemporal approach. This approach has been used by Prof. Hernesniemi since 1980s and was refined during his training period with Profs. Drake and Peerless in 1989 and 1992–1993. They used the subtemporal approach in 80% of 1234 basilar tip aneurysm patients treated between 1959 and 1992. Advantage of the subtemporal approach is that it provides a lateral view on the basilar artery and provides better visualization of the perforators originating from the basilar tip. These perforators are usually hidden by the bifurcation if accessed through the trans-Sylvian route.

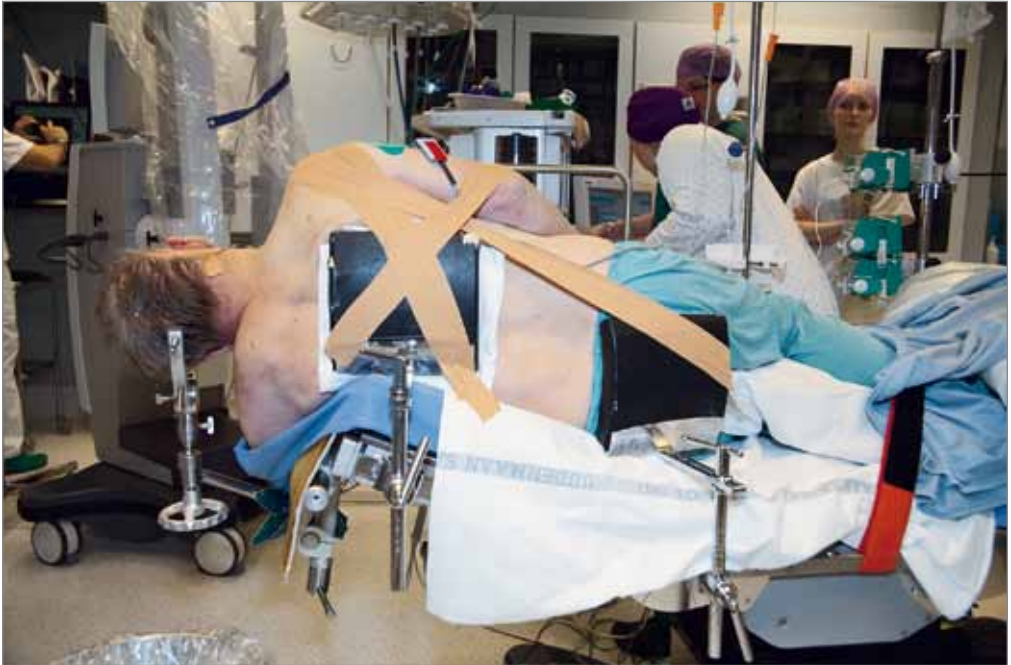

Figure 5-4 (a). Subtemporal approach. See text for details.

### 5.4.2. Positioning

The patient is placed in park bench position with the head fixed in the Sugita frame and: (1) elevated above the cardiac level; (2) upper shoulder retracted; and (3) the head tilted laterally towards the floor, without compromising the venous outflow from the internal jugular vein (Figure 5-4a). The right side is preferred unless the projection or complexity of the aneurysm, scarring from earlier operations, a left oculomotor palsy, a left-sided blindness or a right hemiparesis, requires a left-side approach. An important step is the protection of the pressure points by use of pillows and pads and resting the patient on a padded surface on the lateral aspect of the rib cage, and not only on their shoulder which can damage the brachial plexus. The upper shoulder is retracted away from the head caudally and slightly backward with tape attached to operating table.

The tape should not be under too much tension not to cause traction injury to the brachial plexus. The upper arm is rested on a pillow and gently held in place. The underlying arm is dropped over the cranial edge of the table, supported in place by being partly wrapped in the bed sheet and the sheet clamped in place using towel clips (Figure 5-4b). Again all pressure points are protected with pillows. Finally a pillow is placed between the knees supporting the lower limbs.

Spinal drainage or ventriculostomy are mandatory for the subtemporal approach. Usually a lumbar drain is inserted to ensure drainage of sufficient amounts of CSF to facilitate minimal retraction of the temporal lobe for access towards the tentorial edge. This is imperative and crucial for this approach. Even if CSF is

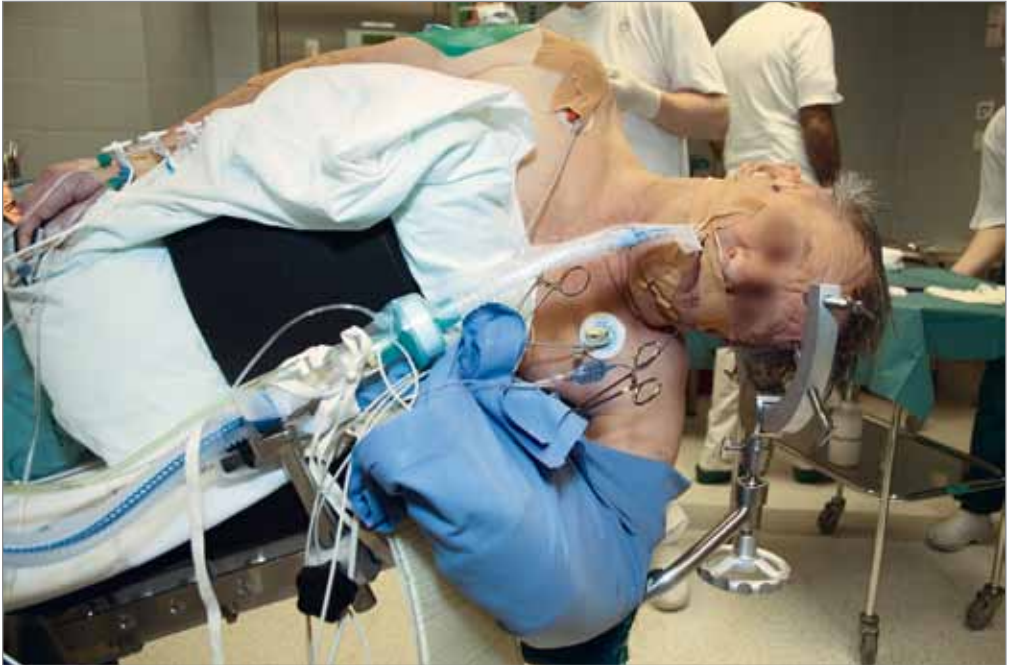

Figure 5-4 (b). Subtemporal approach. See text for details.

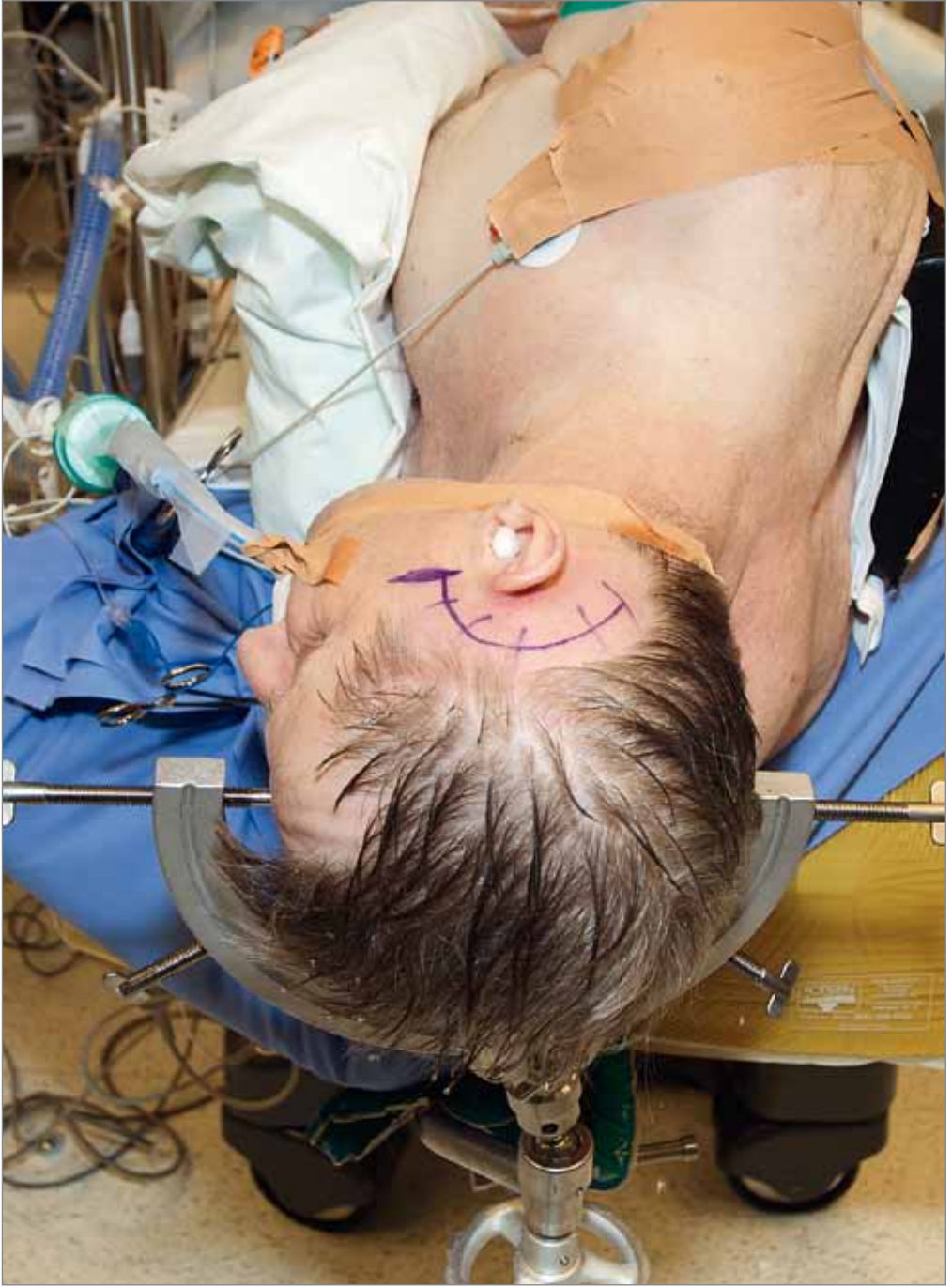

Figure 5-4 (c). Subtemporal approach. See text for details.

gradually drained via suction during inspection of the subtemporal region, it is unnecessarily traumatic. Between 50 to 100 ml of CSF should be removed prior to craniotomy.

#### 5.4.3. Skin incision and craniotomy

This skin incision can be either linear or a small horseshoe-like incision curving posteriorly (Figure 5-4c). The linear incision is placed 1 cm anterior to the tragus and starts just above the zygomatic arch runs cranially 7 to 8 cm. The curved incision has the same starting point but it curves posteriorly just above the earlobe (Figure 5-4d). With the curved incision, the craniotomy can be extended more in the posterior direction, which eventually leads to a wider exposure of the tentorium and the interpeduncular fossa. Visualization of the insertion of the fourth nerve into the tentorial edge will be easier and there will be more room for dividing and lifting the tentorium. At the same time approaching the tentorial edge from slightly posterior direction requires less temporal lobe elevation since the floor of the middle fossa is not as steep here than closer to the temporal pole. Posterior projecting basilar bifurcation aneurysms and P1-P2 segment aneurysms always require this wider approach. The same applies for low-lying basilar bifurcation aneurysms. Lately, we have been using the curved incision in the majority of the cases.

A one-layer skin-muscle flap is turned with the base caudally (Figure 5-4e). The Sugita frame and spring hooks provide strong retraction in the basal direction. The temporal muscle is separated all the way down to the origin of the zygomatic arch, which needs to be identified and exposed. Cutting and removing the zygomatic arch to obtain even more retraction of the temporal muscle is not necessary, strong

retraction with the spring hooks is enough. While retracting the temporal muscle the external auditory canal should be left intact, remembering that the skin is usually thin in this region.

One burr hole is placed at the cranial border of the planned bone flap and a second burr hole is made basally, close to the origin of the zygomatic arch (Figure 5-4f). The reason for this basal burr hole is dense attachment of dura at this site. If only cranial burr hole is used, the risk of dural tear is by far higher. A curved, blunt dissector ("Jone") is used to carefully detach the bone from the underlying dura. It is very important to keep the dura intact so that it can be later retracted basally to provide better exposure in the subtemporal space. A 3 to 4 cm bone flap is detached with a craniotome. The first cut is made anterior in between the two burr holes, the second cut posterior from the cranial burr hole all the way towards the floor of the middle fossa (Figure 5-4g). Finally the bone is thinned down along the basal border of the temporal bone in between the two cuts and the bone flap is cracked. Holes for tack-up sutures are drilled at the cranial border of the craniotomy. The craniotomy is then widened basally by removing bone in the temporo-basal direction with high-speed drill (arrows; Figure 5-4h). Large diamond drill can be used for stopping bleedings using hot drilling. The goal is to expose the origin of the floor of the middle fossa so that there will be no ridges obstructing the view when entering the subtemporal region. A common mistake is to leave the craniotomy too cranial, which then requires more retraction of the temporal lobe, causing unnecessary injury. During drilling, very often some of the air cells of the temporal bone are opened (arrow; Figure 5-4i). This necessitates meticulous closure at the end of the surgery to prevent postoperative CSF leak. Sealing the

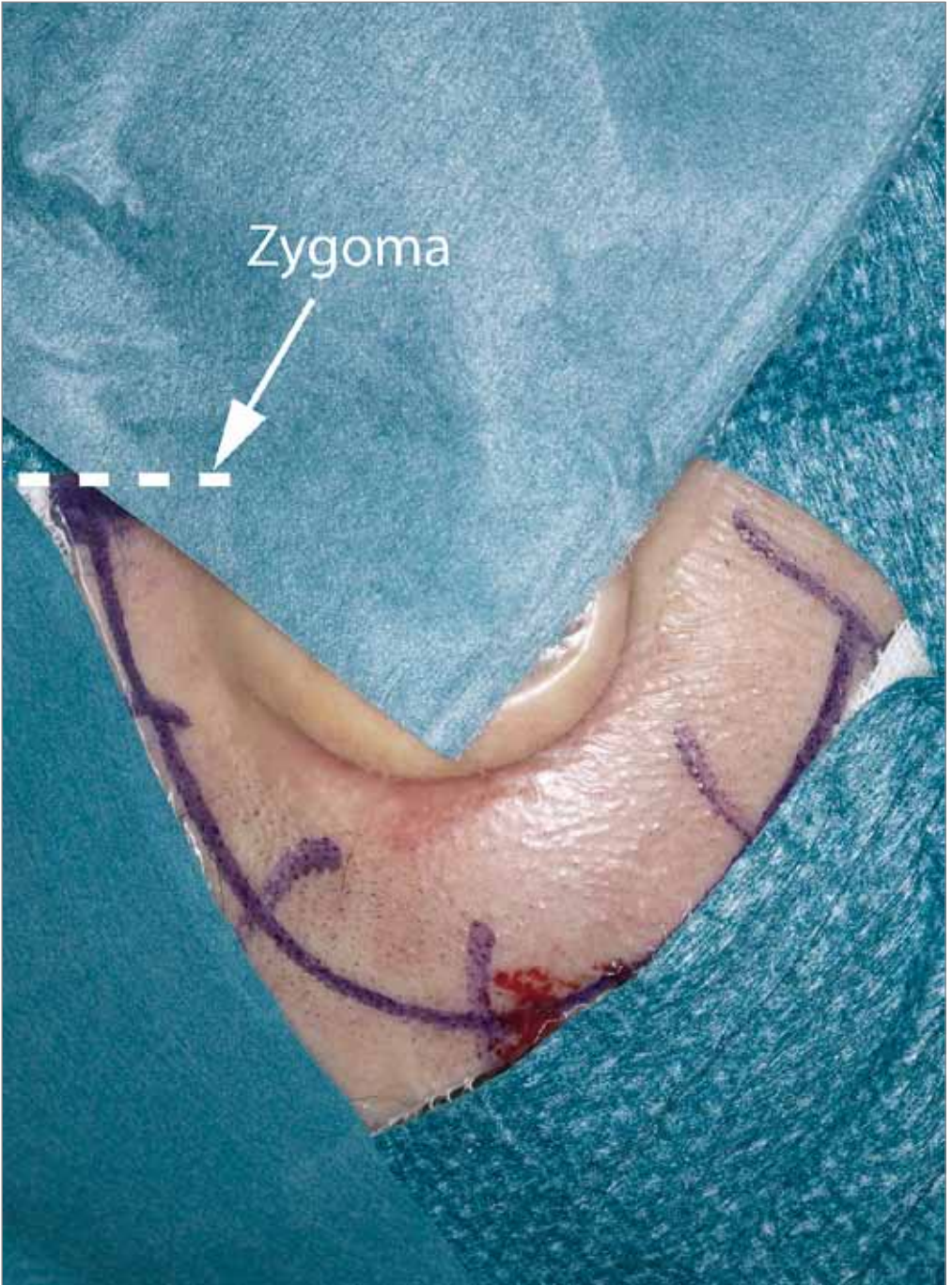


Figure 5-4 (d). Subtemporal approach. See text for details.



air cells with part of the temporal muscle flap everted over the bony edge and sutured to dura is one possible trick ("Chinese-Turkish trick"). Using fat graft, fibrin glue and bone wax are other options.

If the spinal drain functions properly, the dura should feel slack at this point. On the contrary, if the dura is tense all the possible anaesthesiological measures should be implemented to decrease the intracranial pressure. The dura is opened as a curved flap with the base caudally and the dural edges are elevated over the craniotomy dressings (Figure 5-4i,j).

The trick of the proper use of the subtemporal approach lies in getting quickly, without heavy compression of the temporal lobe, to the tentorial edge, where cisterns are opened to release additional CSF and to relax the brain. The spinal drain can be closed at this point. Elevation of the temporal lobe should start close to the temporal pole and the dissection proceeds posteriorly across the caudal surface, while taking care not to stretch the bridging veins too much. The retraction of the temporal lobe should be gradually increased. Abrupt retraction or elevation of the middle portion of the temporal lobe would risk tearing of the vein of Labbé leading to temporal lobe swelling and venous infarction. Once the temporal lobe is mobilized and elevated with the tentorial edge visible, a retractor is placed to retain space for further advance towards the basilar bifurcation. We prefer a relatively wide retractor to have a large surface area without focal pressure points.

The elevation of the uncus with the retractor exposes the opening to the interpeduncular cistern and the third nerve. The third nerve can be mobilized by cutting the arachnoid bands surrounding it, but its palsy can easily occur even after minimal manipulation. In other patients even prolonged manipulation of the third nerve does not lead to any signs of postopera-

tive palsy. Even with the uncus retraction of the third nerve, the opening into the interpeduncular cistern remains narrow. The opening can be widened by placing a suture at the edge of the tentorium in front of the insertion and the intradural course of the fourth nerve lifting the tentorial edge upwards. The original technique of using a suture has been nowadays replaced by a small Aesculap clip which is much easier to apply through the narrow working channel. If lifting the tentorium does not provide a wide enough corridor, we partially divide the tentorium for better exposure. The cut, perpendicular to the tentorial edge and about 10 mm long, is performed posterior to the insertion of the IV nerve, and the tentorial flap is fixed with a small Aesculap clip(s) to get better exposure towards the upper portion of the basilar artery. In cases with a low-lying basilar bifurcation, dividing the tentorium remains absolutely necessary, and a more posterior approach with a larger bone flap is planned from the beginning of the operation. The posterior clinoid process does not have to be removed when using the subtemporal approach to access low-lying basilar bifurcation.

#### *T&T:*

- *Park bench position, always spinal drainage (50–100 ml of CSF removed)*
- *Horseshoe incision preferred, allows more posterior approach*
- *Gradual retraction of the temporal lobe*
- *Covering the temporal lobe with wide rubber strips cut from surgical gloves prevents cottonoids from sticking to the cortex during retraction*
- *Wide retractor to hold the temporal lobe*
- *Oculomotor nerve is the highway to the basilar tip, always passing between P1 and SCA*
- *Always use temporary clipping (or short cardiac arrest with adenosine) of basilar artery and possibly also PCom(s) for smooth clipping of the aneurysm base*

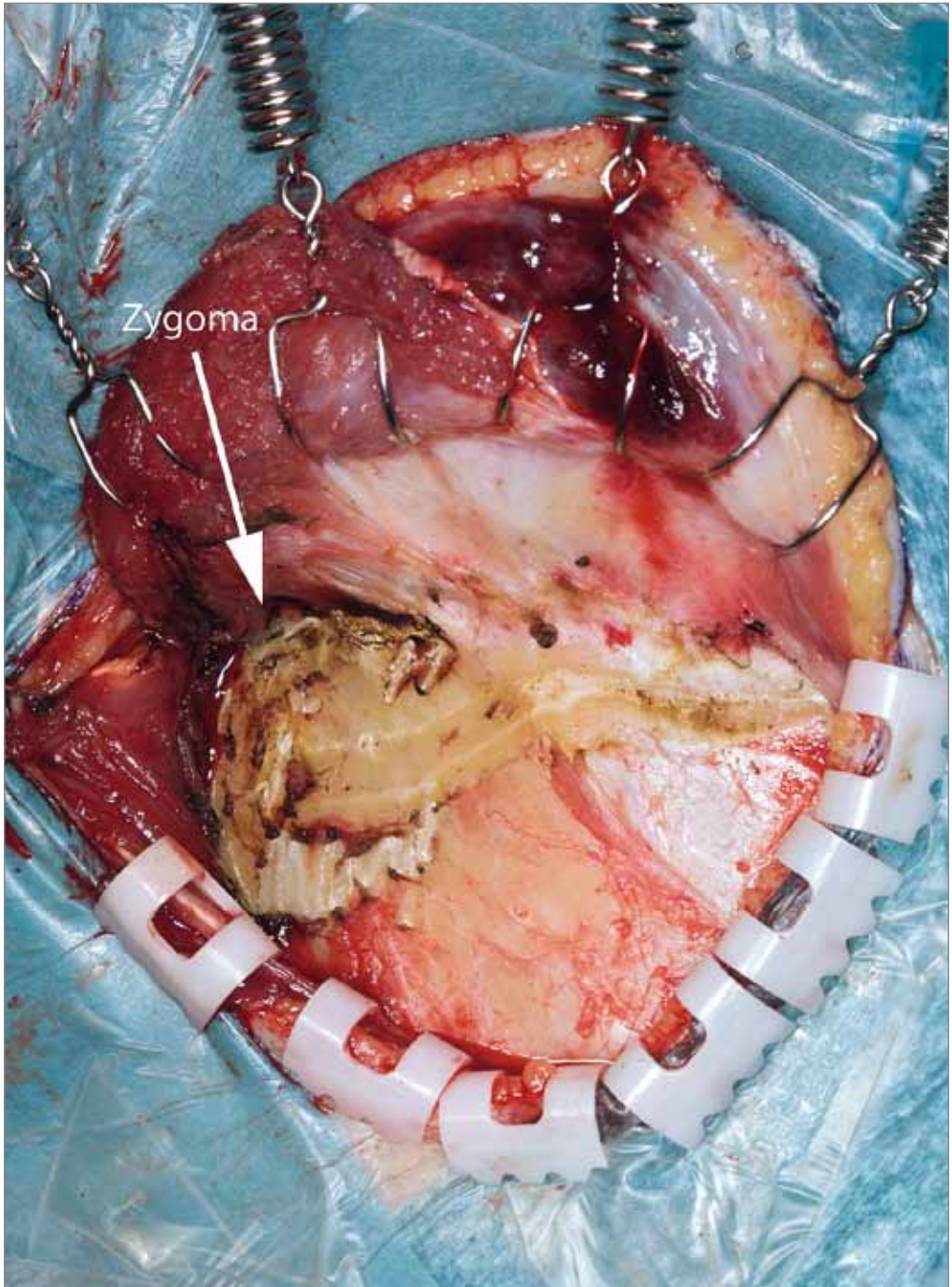


Figure 5-4 (e). Subtemporal approach. See text for details.

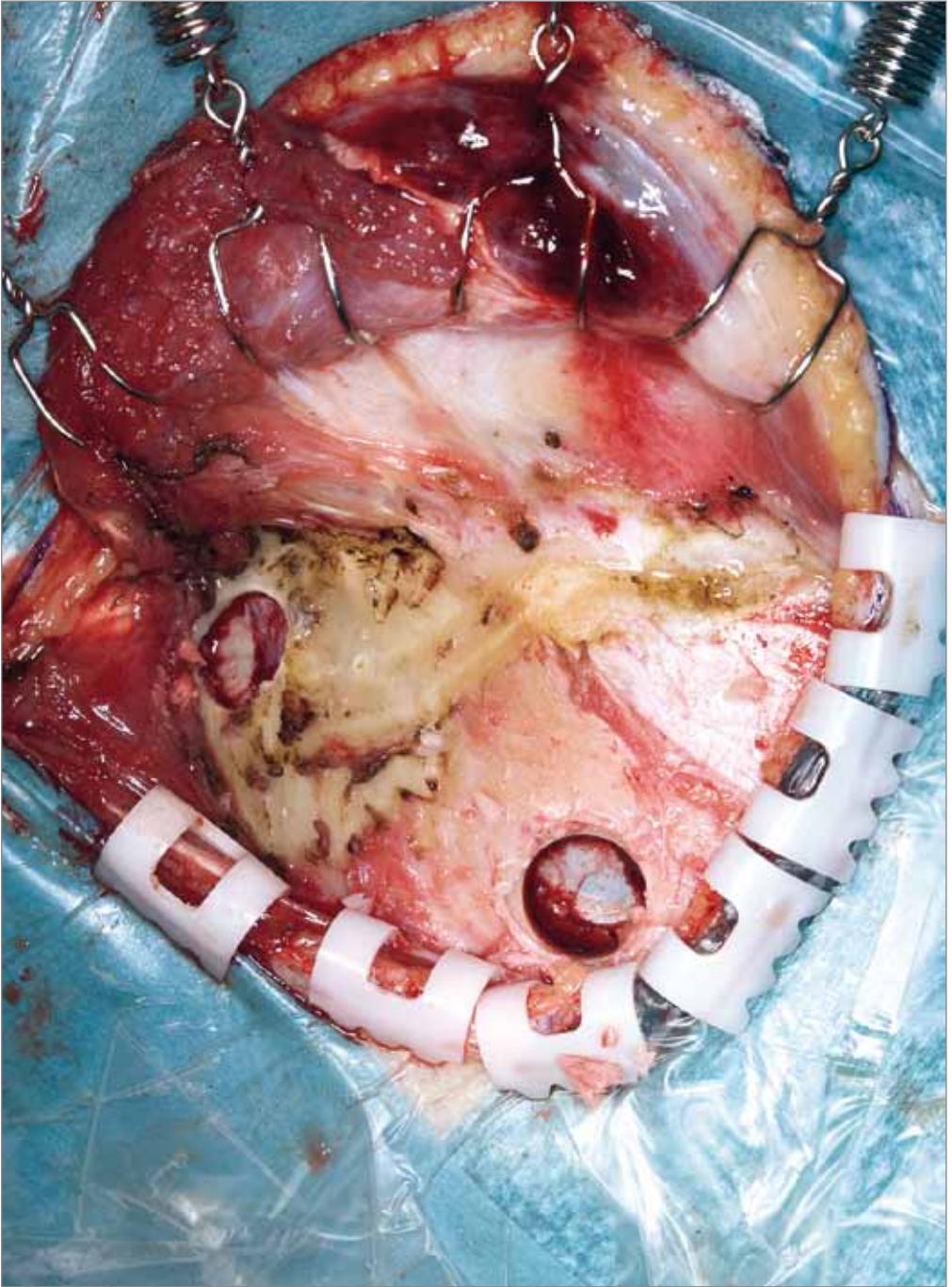


Figure 5-4 (f). Subtemporal approach. See text for details.

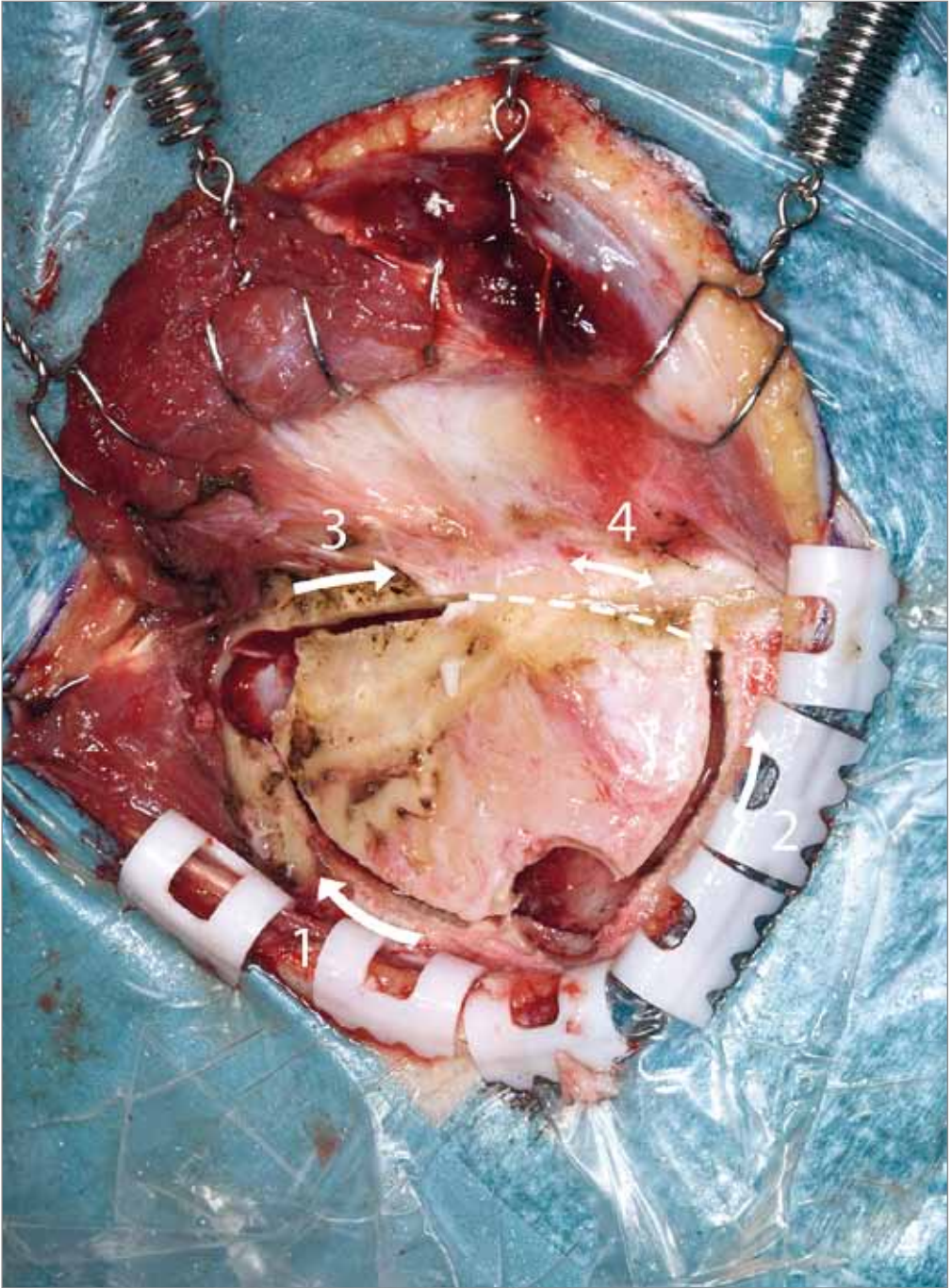


Figure 5-4 (g). Subtemporal approach. See text for details.

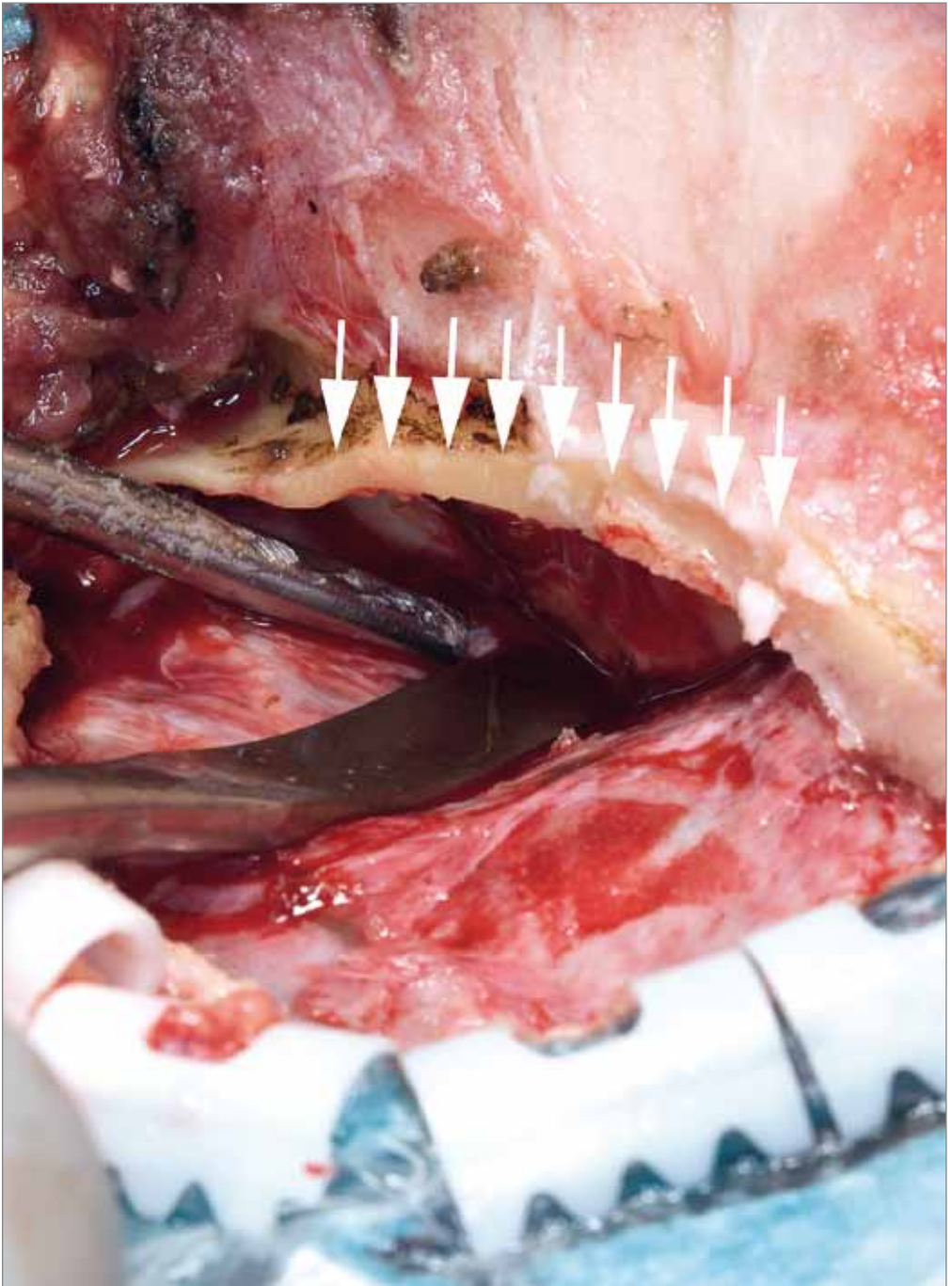


Figure 5-4 (h). Subtemporal approach. See text for details.

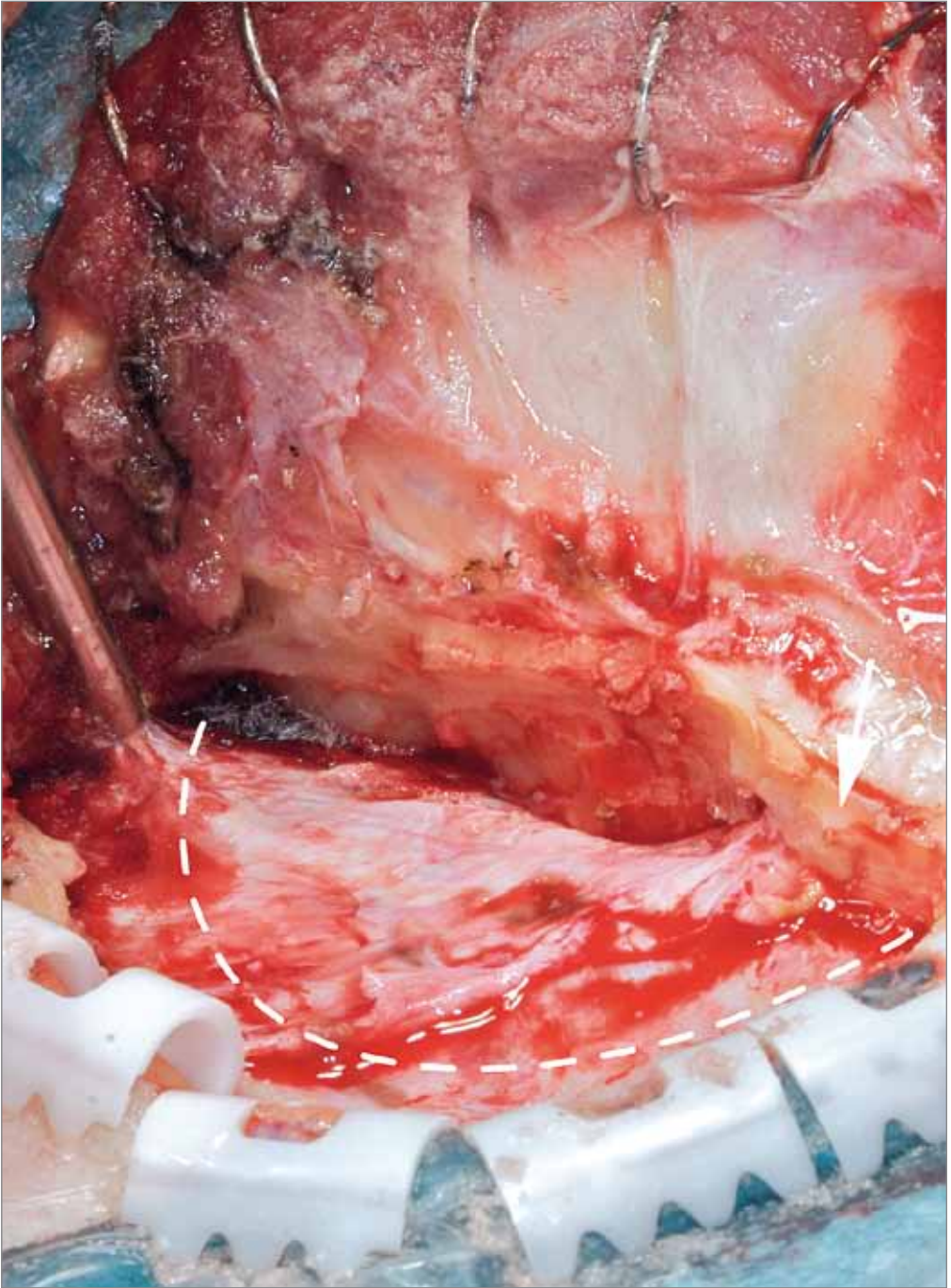

Figure 5-4 (i). Subtemporal approach. See text for details.

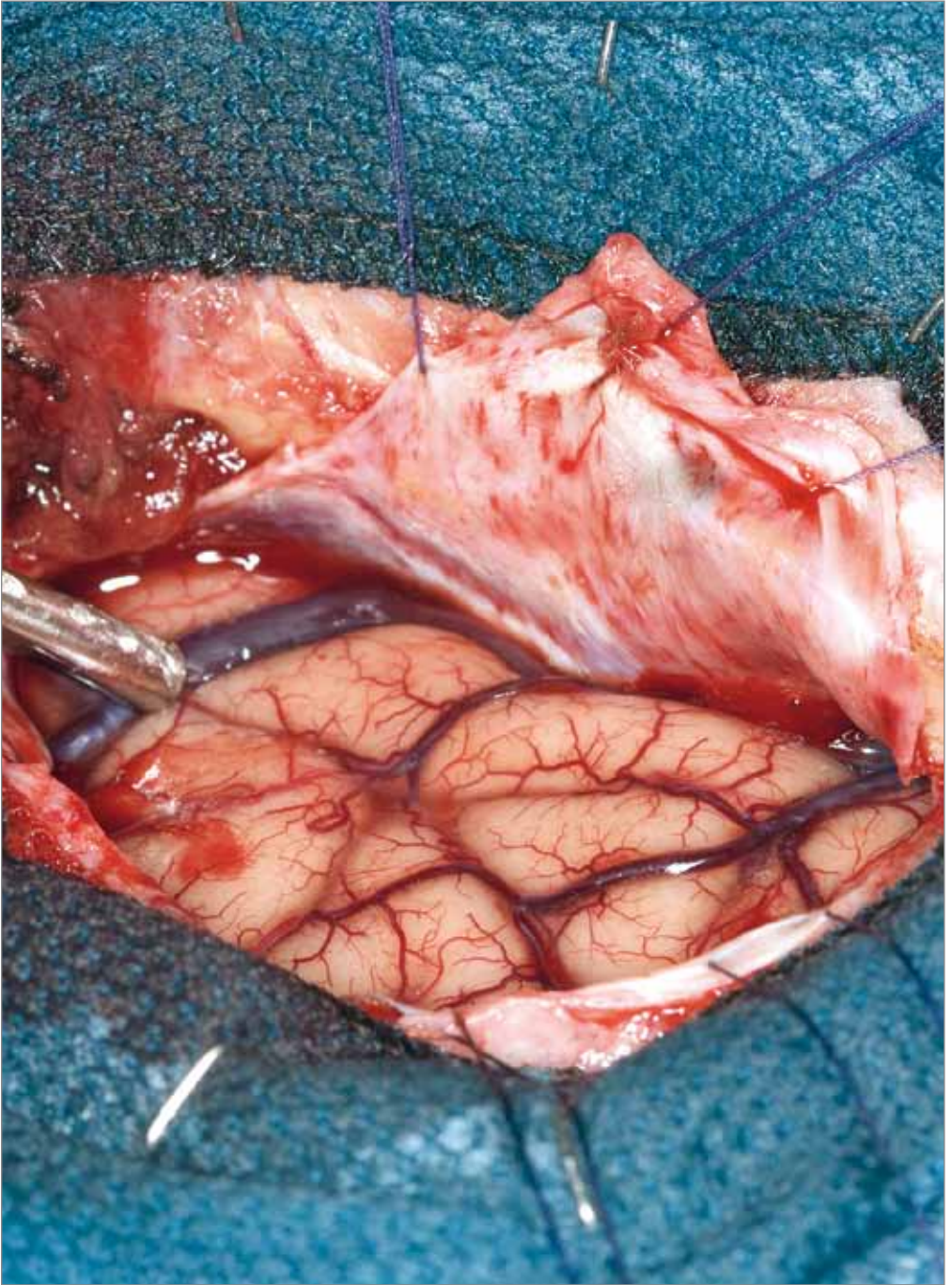


Figure 5-4 (j). Subtemporal approach. See text for details.

## 5.5. RETROSIGMOID APPROACH

The retrosigmoid approach provides good access to the cerebellopontine angle. It is by far simpler and faster with much less need for bone removal than other more extensive lateral posterior fossa approaches. The craniotomy is small and depending on how cranially or caudally it is placed, different cranial nerves and vascular structures can be accessed. The retrosigmoid approach is classically used for vestibular schwannoma surgery but with small variations it can be equally well used for microvascular cranial nerve decompressions, aneurysms and skull base tumors of the lateral posterior fossa. The main difficulty in the proper execution of the retrosigmoid approach is correct patient positioning for an optimal surgical trajectory into the steep posterior fossa, placement of the craniotomy lateral enough so that cerebellum is retracted as little as possible,

and good microanatomical knowledge of all the structures in the posterior fossa, as there is much less room for manipulation than in the supratentorial space.

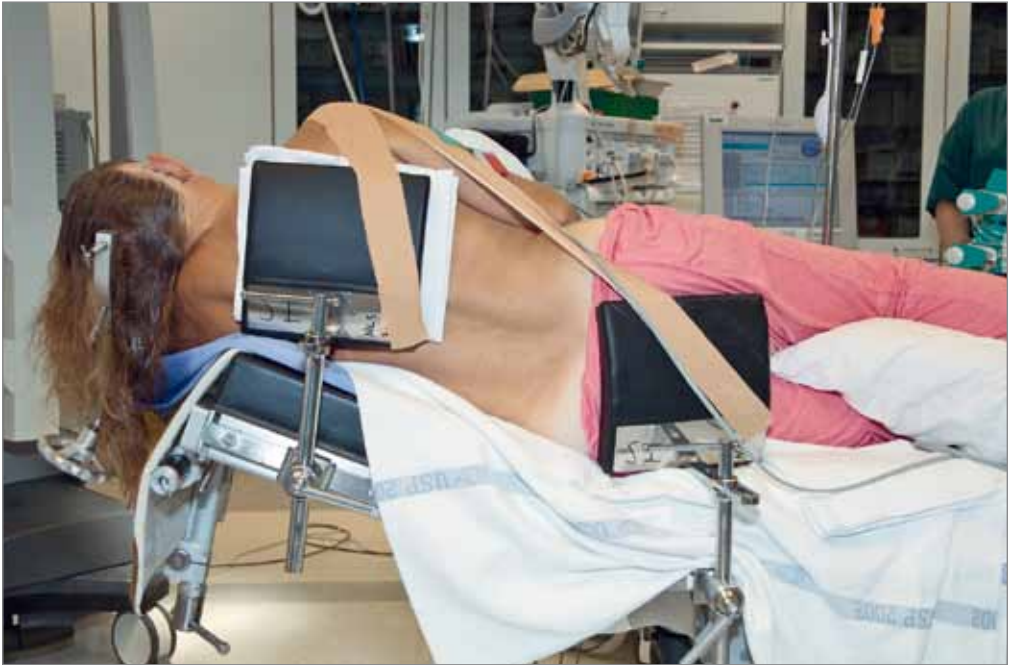

Figure 5-5 (a). Retrosigmoid approach. See text for details.



### 5.5.1. Indications

The most common use for retrosigmoid approach is in vestibular schwannoma surgery. Other common pathologies include vertebral artery – PICA aneurysms, microvascular cranial nerve decompression of the V or VII nerve and meningiomas of the lateral posterior fossa. In general, the lesions that can be approached via the small retrosigmoid "tic" craniotomy should be located at least 10 mm cranially from the foramen magnum. If located more caudally, such as low-lying vertebral aneurysms, some modification more towards the far lateral approach is needed, with the craniotomy extended towards the foramen magnum and dissection of the extracranial vertebral artery. But for lesions well above the foramen magnum a straight incision with a small craniotomy is all that is needed. Cranial to caudal location of the bone flap depends on the exact location of

the lesion in question. The most cranial craniotomy, with its upper border above or at the level of the transverse sinus, is usually made for fifth nerve microvascular decompression. Craniotomy for vestibular shwannomas is located slightly little more caudally and the most caudal craniotomies are typically for vertebral aneurysms at the origin of the PICA. Lesions located inside the cerebellar hemisphere, such as tumors, intracerebral hematomas or cerebellar infarctions can be also approached using a modification of the retrosigmoid approach. In such cases, with no need for the lateral extension towards the sigmoid sinus, both the skin incision as well as the craniotomy are placed more medially preventing opening of the mastoid air cells.

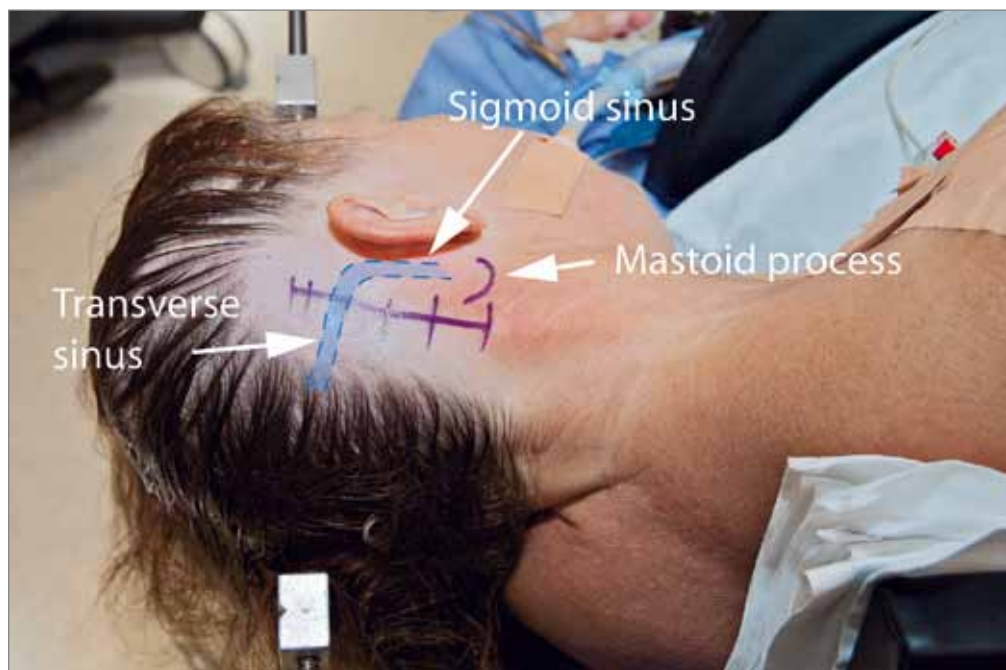


Figure 5-5 (b). Retrosigmoid approach. See text for details.

### 5.5.2. Positioning

For the retrosigmoid approach the patient is placed in lateral park bench position with the head and upper torso elevated so that the head is about 20 cm above the heart level (Figure 5-5a). Two side supports are placed on the dorsal side, one below the level of upper shoulder and the other at the level of pelvis. The shoulder support must not extend cranially from the retracted shoulder as it would get in the way of the surgical trajectory. One ventral side support together with a large pillow is placed to support the thorax and the belly. The upper arm can be placed on this pillow to rest comfortably. The side supports need to be stable and high enough to allow lateral tilting of the operating table during the procedure without the patient sliding off the table. The upper body is rotated slightly (5–10°) backward so that the upper shoulder can be more easily retracted

caudally and posteriorly with tape (see Figure 5-4c in previous section). The head, fixed in head frame, is: (a) flexed a little forward; (b) tilted laterally; and if needed (c) slightly rotated towards the floor. The lateral tilt should not be too extreme to prevent compression of the jugular veins. The most important trick in executing the retrosigmoid approach is to prevent the upper shoulder from obstructing the surgical trajectory. The floor of the posterior fossa drops very steeply towards the foramen magnum, so that the actual approach trajectory is much more from the caudal direction than one usually expects. This is the reason why it is so important to open the angle between the head and the upper shoulder as much as possible. This is achieved with: (a) proper head position (the flexion and the lateral tilt); (b) the slight counter rotation of the upper body;

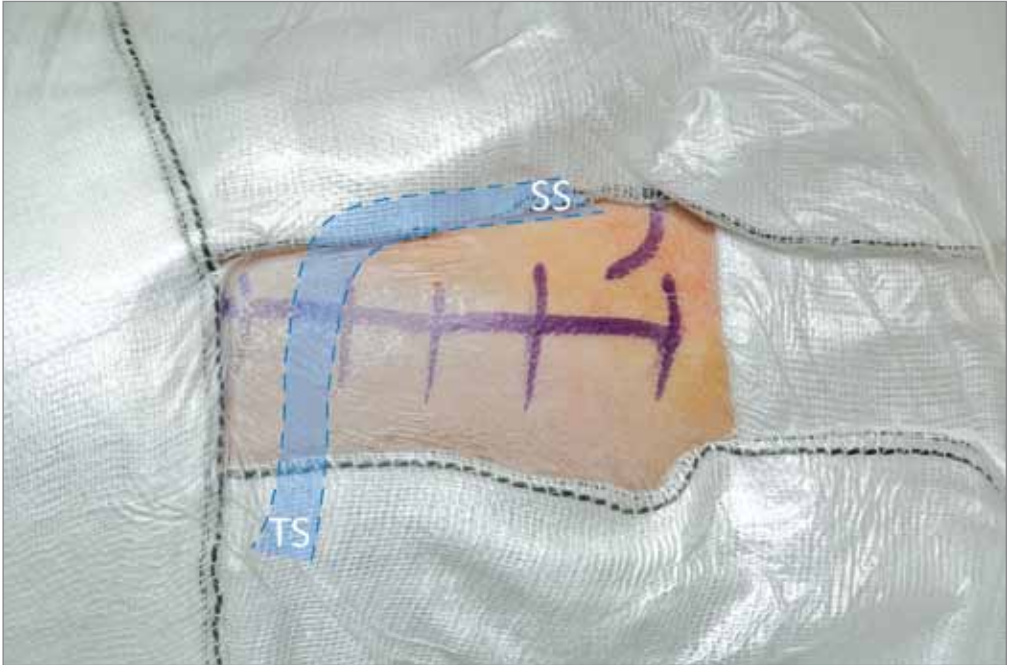

Figure 5-5 (c). Retrosigmoid approach. See text for details.

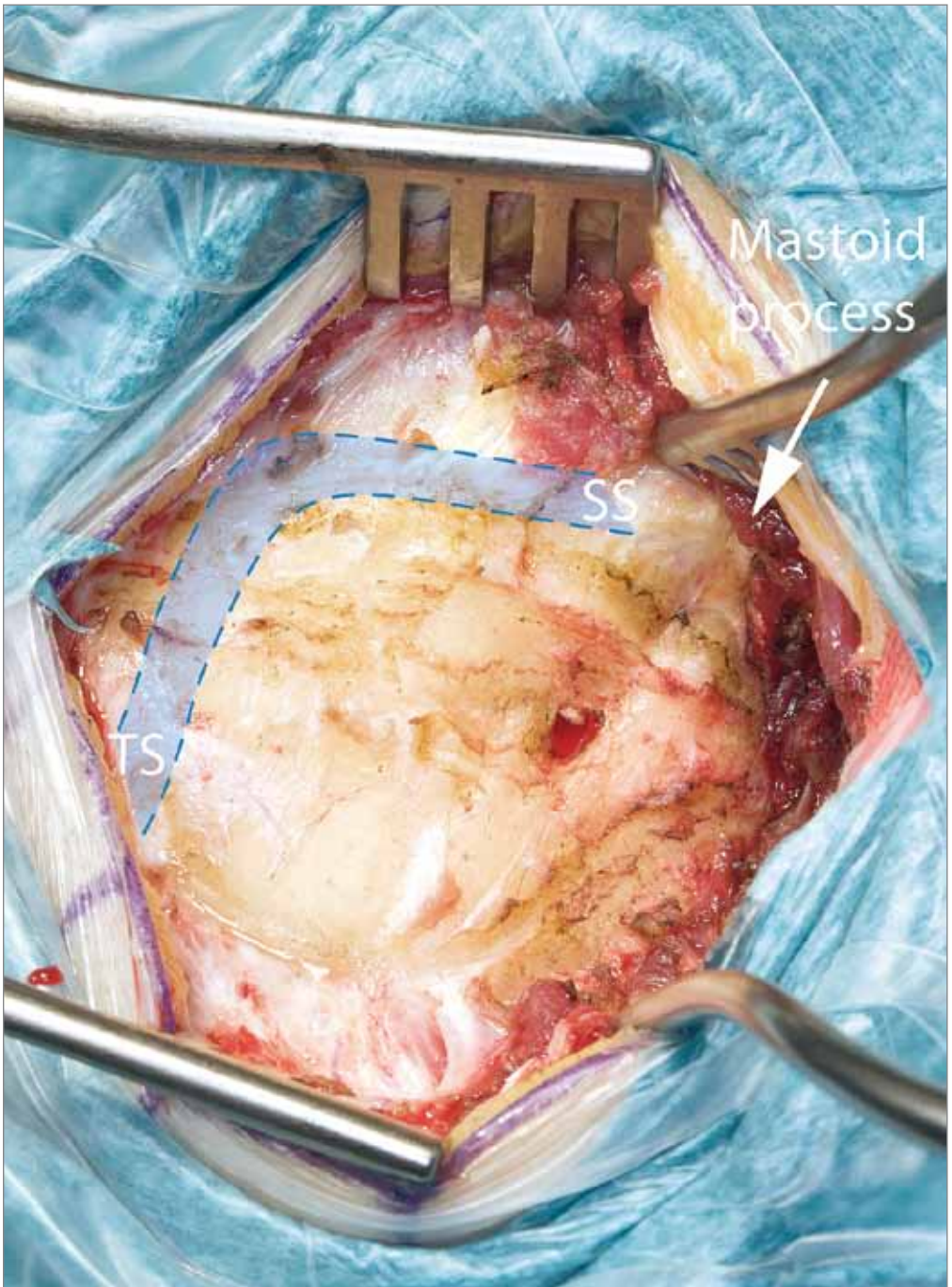


Figure 5-5 (d). Retrosigmoid approach. See text for details.

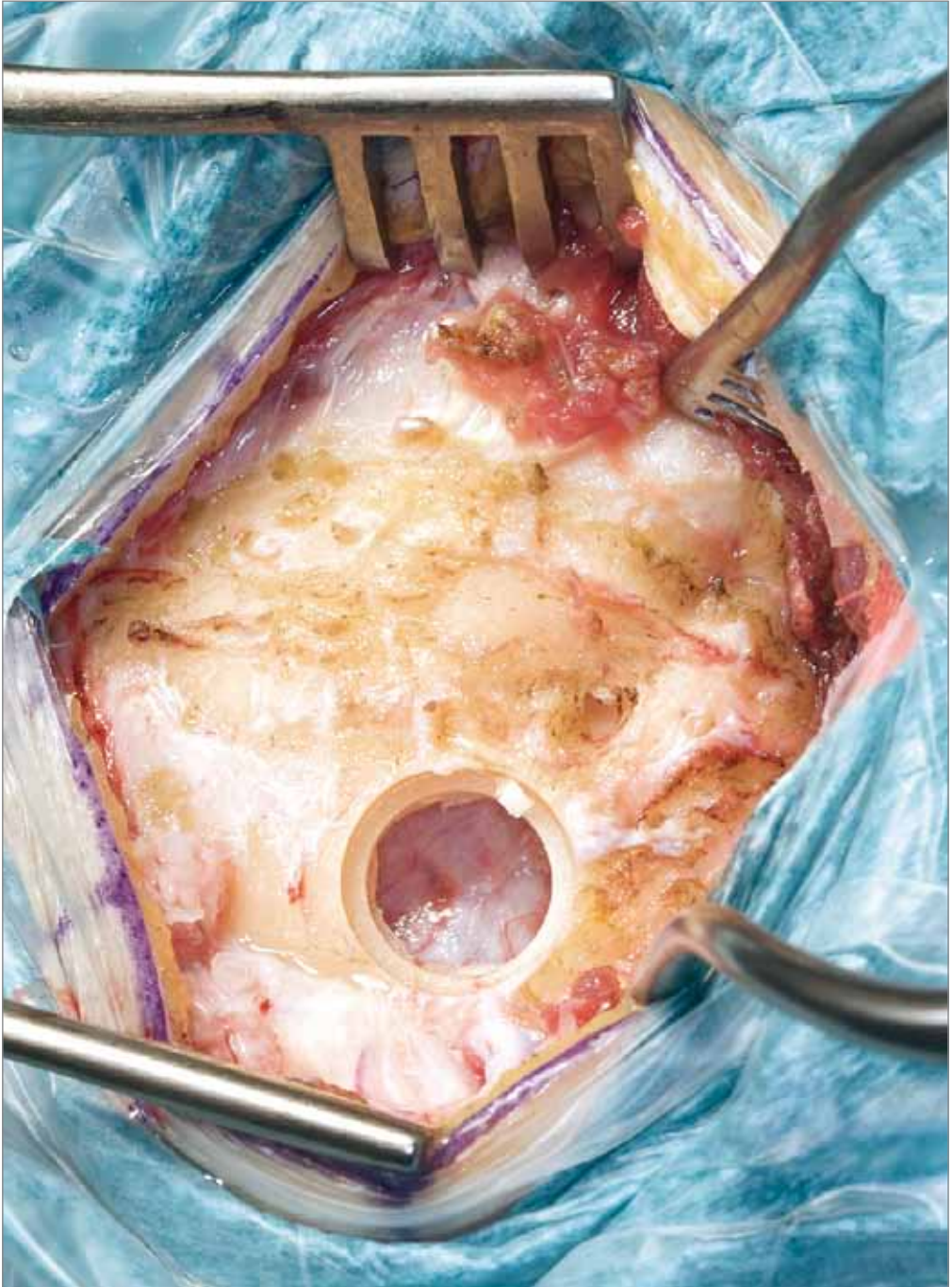

Figure 5-5 (e). Retrosigmoid approach. See text for details.

and (c) retraction of the upper shoulder with tapes caudally without damaging the brachial plexus. This shoulder retraction is the key point of the positioning. The lower arm is supported in place by being partially wrapped in the bed sheet under the patient, and the sheet clamped in place using towel clips. In addition, all the vulnerable pressure areas (elbow joints, ulnar nerves, hands, shoulders and brachial plexus) need to be protected with gel pillows. Once the positioning is ready, the lumbar drain is placed and 50–100 ml of CSF is released before the dura is opened.

### 5.5.3. Skin incision and craniotomy

A linear skin incision is placed about one inch behind the mastoid process (Figure 5-5b). The exact cranial to caudal location of the incision varies depending on how high or low from the foramen magnum the pathology lies. To access the highest located structures of the lateral posterior fossa (e.g. during microvascular decompression of the fifth nerve or high-lying meningioma) the junction between the transverse and sigmoid sinuses needs to be exposed and identified, whereas, for accessing the area close to the foramen magnum a more caudally placed incision suffices. The junction of the sigmoid and the transverse sinus is usually located just caudal to the zygomatic line (a line drawn from the origin of the zygomatic arch towards the external occipital protuberance) and posterior to the mastoid line (a cranial to caudal line running through the tip of the mastoid process). When planning the skin incision, it is important to have it extend caudally enough (Figure 5-5c). If the incision is too short and too cranial the stretched muscles and skin will prevent an optimal view into the posterior fossa and the use of craniotome, which is coming from the caudal and lateral direction, not just

lateral as one might initially expect. So the skin incision has to extend several centimeters below the level where caudal border of the craniotomy is planned.

A large, curved retractor (wound spreader, also referred to as a mastoid retractor) under high tension is placed from the cranial side of the incision. If needed, a second, smaller curved retractor can be used from the caudal direction (Figure 5-5d). The subcutaneous fat and muscles are split along the linear incision with diathermia. The external occipital artery runs often across the incision. In practice, it is nearly always cut and has to be coagulated. After reaching the bone of the posterior fossa, the insertions of the muscles are detached from the bone and the bone is followed caudally. The level of the foramen magnum is determined with finger palpation. While progressing deeper and closer to the foramen magnum, a layer of yellowish fat is encountered. This should be taken as a warning sign, since the extracranial vertebral artery running on the cranial edge of the C1 lamina is usually close by at this point. For a simple tic craniotomy it is not necessary to proceed any deeper to expose the foramen magnum itself. That is reserved only for the extended approach where also the C1 lamina is exposed and the course of the extracranial vertebral artery is identified. Instead, a bony area of 3 to 4 cm in diameter is cleared from all the muscle attachments and the curved retractors are repositioned to gain maximal bony exposure. One burr hole is placed at the posterior border of the incision and the underlying dura is carefully detached with curved dissector without damaging the transverse or the sigmoid sinuses (Figure 5-5e). Two curved cuts with the craniotome are made anteriorly towards the mastoid, one cranially and the other caudally (Figure 5-5f). Finally, the bone is thinned down with a craniotome

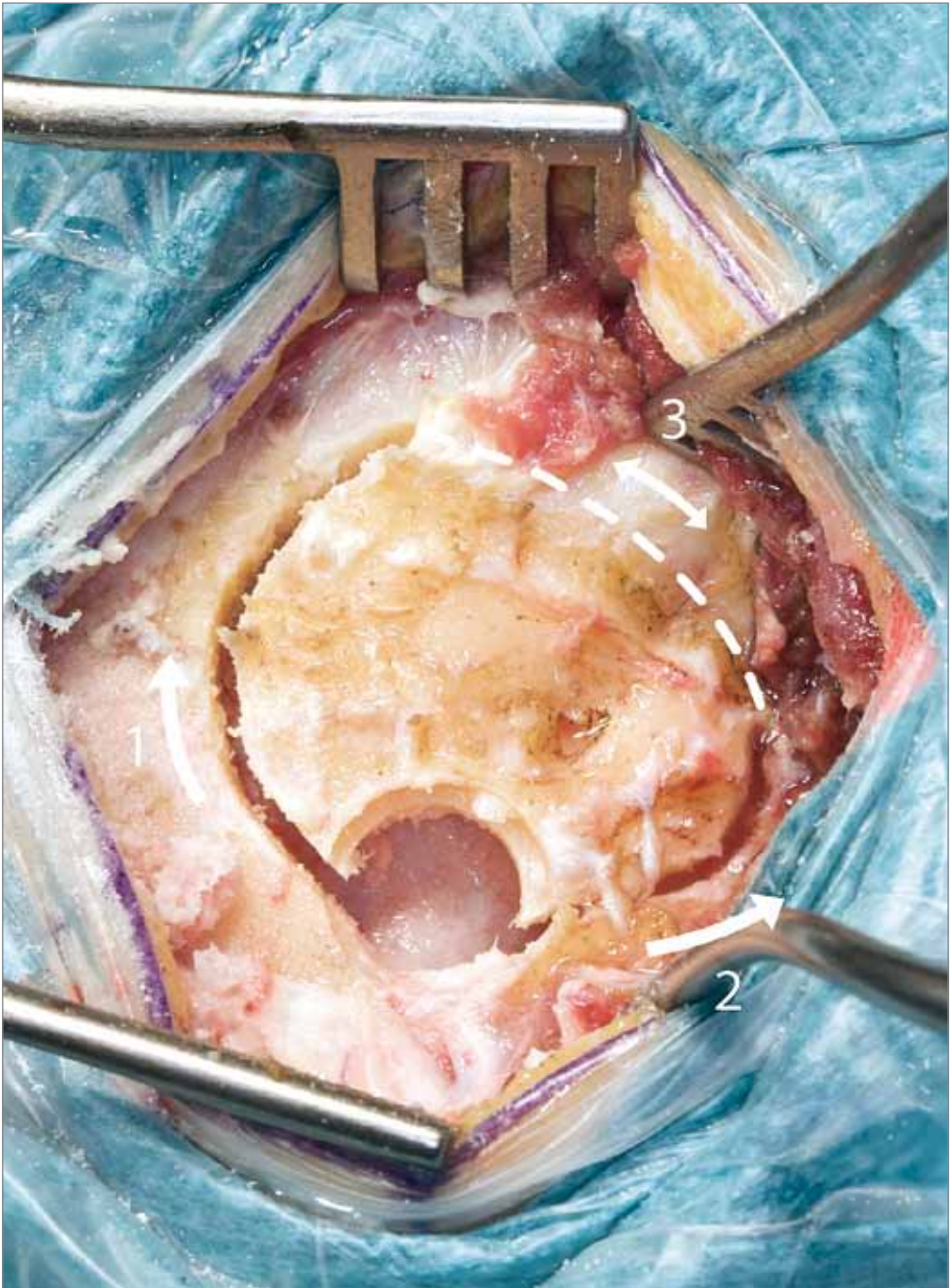


Figure 5-5 (f). Retrosigmoid approach. See text for details.

in a straight line along the anterior edge at the border of the mastoid air cells, the bone flap is cracked and detached (Figure 5-5g). A 2 to 3 cm bone flap is usually sufficient. A high-speed drill is used to extend the opening closer towards the temporal bone and to level the edges (arrows; Figure 5-5g). If mastoid air cells open these should be carefully waxed with bone wax and a fat or muscle graft can be used to cover the defect to prevent postoperative CSF leak. In case of injury to the sinus and large venous bleeding, the first measure is to get the head higher by tilting the table into anti-Trendelenburg position and then the bleeding site is covered with Surgicel or TachoSil and tamponated with cottonoids. A linear cut can be repaired with direct suture.

The dura is opened in a curvilinear fashion with the base towards the mastoid (Figure 5-5g). The dural edges are elevated with sutures extended over the craniotomy dressings (Figure 5-5h). Especially when close to the junction of the sigmoid and transverse sinus, the dura is opened in three-leaf fashion with one of the cuts directed exactly towards the junction to get better exposure. Even a small scissor cut into the sinus should be repaired immediately with a suture. Coagulation with bipolar makes such a hole only bigger and liga clips, although easier to apply, tend to slide away under manipulation, usually at a moment when least appreciated.

If a spinal drain was used and 50–100 ml of CSF has been removed, the brain should be slack after opening the dura and the drain can be closed. But if the brain remains tight, other strategies for releasing more CSF must be adopted. By tilting the microscope towards the caudal region one might be able to enter the cerebellomedullary cistern (cisterna magna) to release additional CSF. The other option would

be to enter the cerebellopontine cistern and to remove CSF from there, but that usually requires more compression of the cerebellum and possible injury to the cranial nerves in situations with lack of space.

To enter the cerebellopontine cistern, compression and retraction on the cerebellum is increased gradually while simultaneously removing CSF with suction. To obtain optimal viewing angle, it might be necessary to tilt the table away from the neurosurgeon. Arachnoid limiting the cistern is opened with microscissors and now the cranial nerves can be inspected and the pathology identified. The tentorium is an excellent guide as a reference point for locating and identifying the cranial nerves. One should look for the bridging veins upon entering the cerebello-pontine angle, especially at the beginning of the dissection. If possible, the veins should be left intact, but if the procedure is significantly hampered by them, they should be coagulated. The petrosal vein is an area of debate and is the most common and prominent vein seen when approaching the tentorium or upper cranial nerves. It is safer to preserve this vein as some surgeons have observed complications after its occlusion.

For closure the area over the mastoid air cells is waxed after closure of the dura. Where the dura cannot be closed completely in a watertight fashion, a dural substitute covered with small amount of fibrin glue can be used to close the defect. What is far more important is to close the mastoid air cells and prevent postoperative CSF leak using a small muscle or fat graft and fibrin glue. There should be a three layer (muscle, subcutis, skin) firm closure of the wound, which helps in preventing CSF leakage. There is occasionally debate whether to do a craniectomy or craniotomy for suboccipital or midline cerebellar approaches. In Helsinki it is

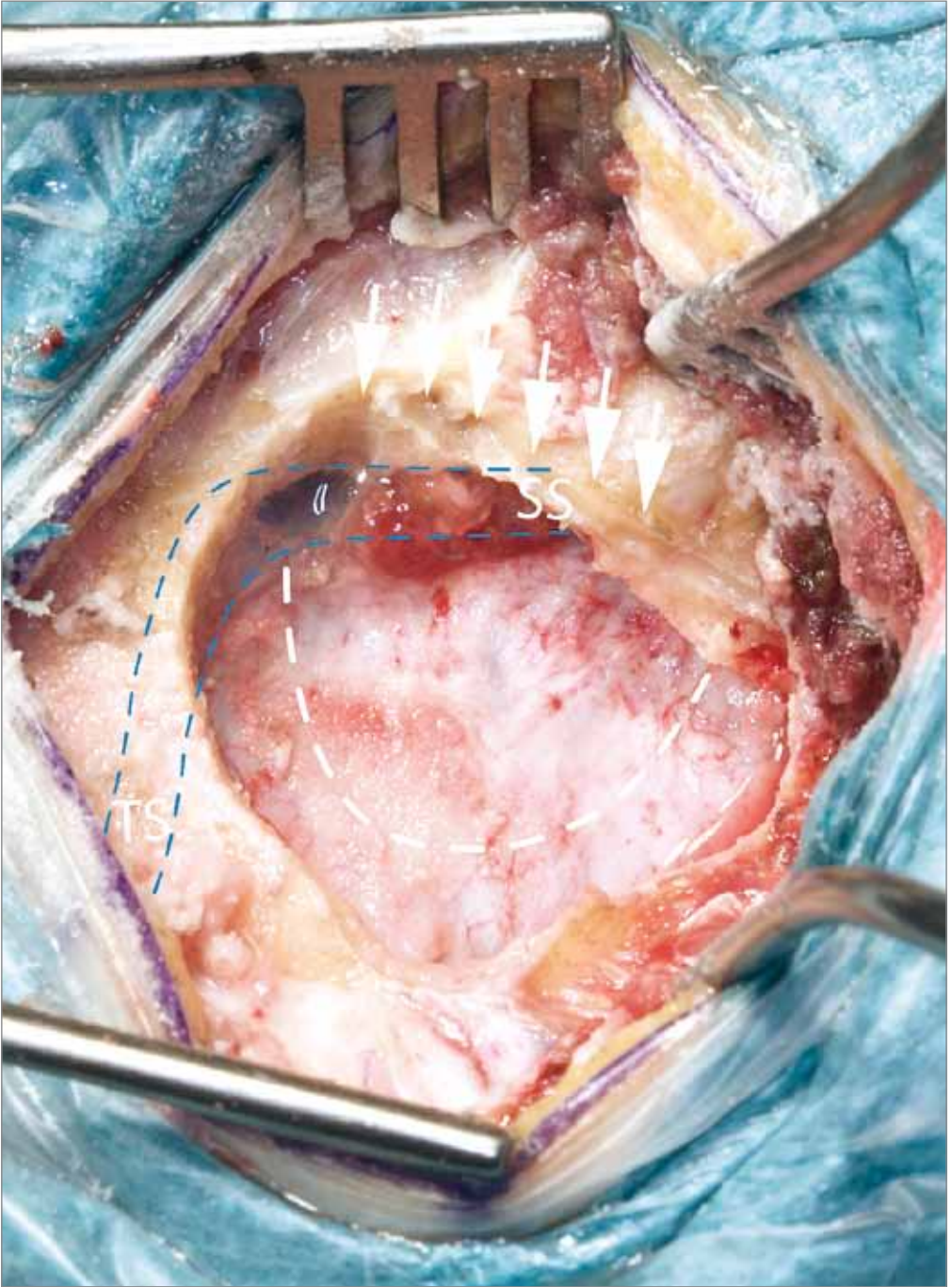


Figure 5-5 (g). Retrosigmoid approach. See text for details.



craniotomy! It decreases the chance of a pseudomeningocele or persistent headaches, and also makes any re-exploration and recurrence at a later date easier and safer to deal with. Without questions, filling the craniotomy defect with the patient's own bone or artificial material provides comfort and feel of security to the patient.

*T&T:*

- *Park bench position, spinal drainage except in very expansive mass lesions*
- *The upper shoulder retracted backwards and downwards with tape*
- *Short straight incision preferred*
- *After dural opening, release CSF from cisterna magna if the brain is still tight*
- *Start retracting the cerebellum and the tonsils medially and slightly upwards as if taking them in your hand*
- *VA, PICA and lower cranial nerves identified – their relation with the lesion determines the exact approach*
- *Out of all cranial nerves the IX-X deserve the highest respect, even temporary dysfunction can be dangerous*
- *If the lesion is 10 mm or more above the foramen magnum, only a simple tic craniotomy is needed*

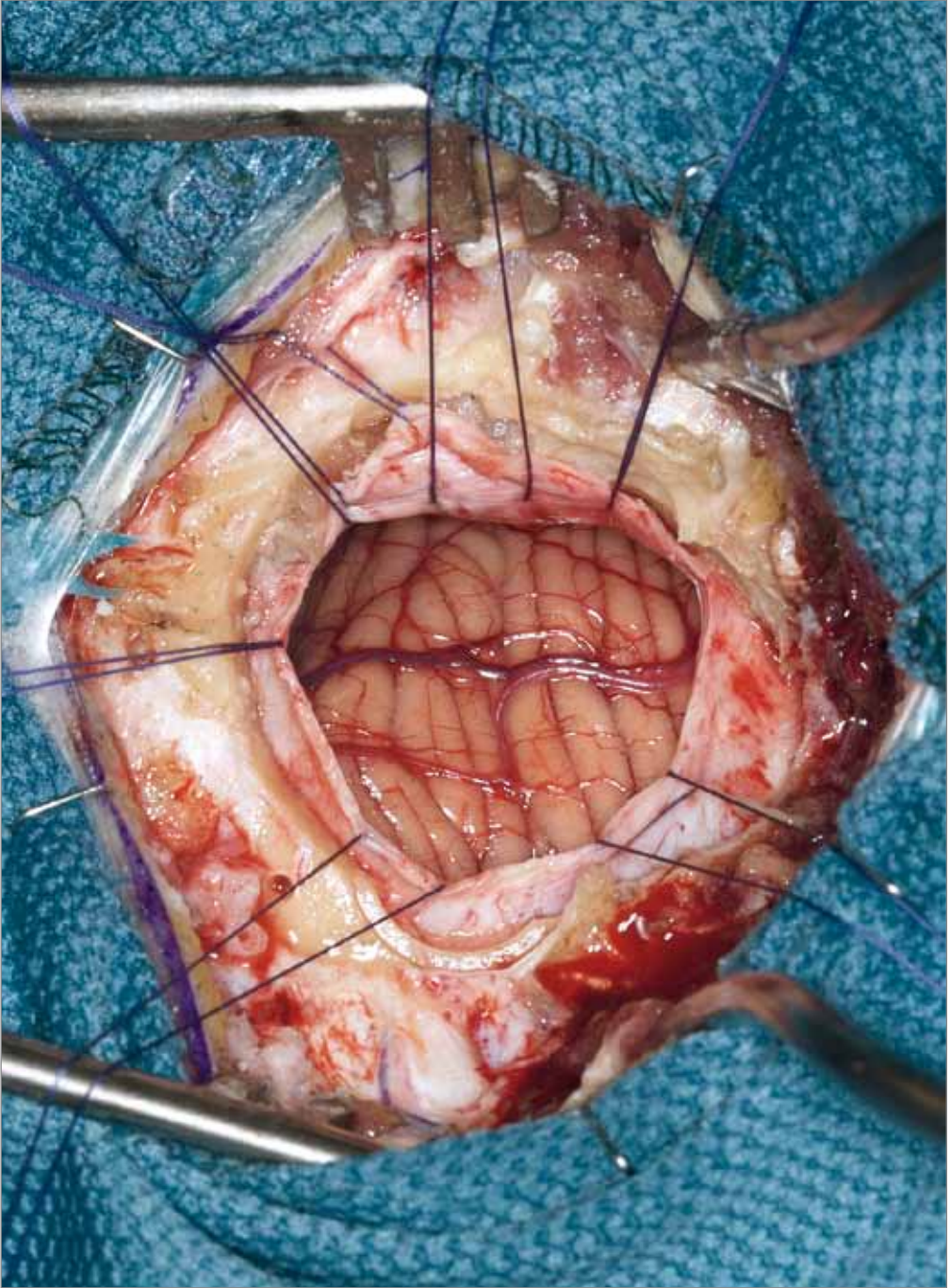


Figure 5-5 (h). Retrosigmoid approach. See text for details.



## 5.6. LATERAL APPROACH TO FORAMEN MAGNUM

The retrosigmoid approach using the small tic craniotomy cannot be used for pathologies that are close to the level of the foramen magnum (less than 10 mm). To access these lesions a caudal extension to the retrosigmoid approach is necessary. Some authors call this the "far lateral approach". We use the actual far lateral approach rarely. Instead, when access to the lateral parts of the foramen magnum is necessary, we settle for a so-called "enough lateral approach", a faster and simpler modification of the far lateral approach. The biggest difference compared to the classical far lateral approach is that the occipital condyle is left intact or only a minimal portion of it is removed. In addition the vertebral artery is not transposed, the sigmoid sinus is not skeletonized and the extracranial/intraosseal course of the lower cranial nerves is not exposed. The classical far lateral approach with extensive bone removal, and resection of the condyle requires occipito-cervical fixation, which removes nearly all movement of the neck. This causes such a significant discomfort to the patient that we do not recommend it unless absolutely necessary. Our lateral approach can be combined with C1 hemilaminectomy if even more caudal exposure is needed. The biggest challenge in the lateral approach is to locate the vertebral artery at the cranial edge of the C1 lamina and to keep it intact during the various steps of craniotomy and C1 hemilaminectomy. The other problem is the venous plexus at the level of the foramen magnum, which can bleed severely.

### 5.6.1. Indications

The most common indications for the lateral approach are low-lying vertebral aneurysms, foramen magnum meningiomas or low brain stem cavernomas and intrinsic tumors. The cranio-caudal length and location of the lesion determines whether the C1 lamina needs to be resected as well. We try to leave C1 intact to assure better stability of the craniocervical junction. Even if C1 hemilaminectomy is performed we do not use any fixation systems as the bony defect is relatively small and the occipital condyle is not removed. The risk of swallowing disturbances is very high in low-lying lesions due to manipulation of the lower cranial nerves and most patients require tracheostomy to prevent aspiration. The tracheostomy is usually performed on the first postoperative day after tests for dysphagia have been carried out. In the majority of the patients the function recovers during several months after surgery.

### 5.6.2. Positioning

The position used for the lateral approach is almost identical to that for the retrosigmoid approach (see section 5.5.2). The lateral tilt of the head towards the floor may be slightly increased to give a better viewing angle towards the foramen magnum.

### 5.6.3. Skin incision and craniotomy

A straight skin incision is planned in the similar fashion as for the retrosigmoid approach. The incision is placed about one inch behind the mastoid. The incision starts below the zygomatic line but extends more caudally, usually 4–5 cm caudal from the tip of the mastoid. The initial exposure is carried out in the same way as for the retrosigmoid approach. The subcutaneous fat and muscles are divided in a linear fashion and a large curved retractor is used to open the wound. The bone of the posterior fossa is exposed and the location of the foramen magnum and the C1 lamina is identified with finger palpation. From this point onward the rest of the foramen magnum exposure and vertebral artery exposure should be carried out under the magnification of the surgical microscope.

The next step is to identify the course of extracranial vertebral artery. Microdoppler can be used for this purpose. First the C1 lamina is exposed with blunt dissection using cotton balls held by a hemostat. The lamina should be exposed close to the transverse process of the C1. The vertebral artery, after passing through the transverse foramen of the C1, should be coursing along the cranial surface of the C1 lamina towards the midline before it enters intradural space at the level of the foramen magnum. It is crucial to identify this whole extradural segment of the vertebral artery as well as the exact place where it becomes intradural. With the vertebral artery visualized the rest of the posterior fossa bone can be safely cleaned from attached muscles all the way down to the foramen magnum that is now clearly exposed. At the anterior border of the exposure the condyloid canal is often encountered marked by rather heavy venous bleeding. The occipital emissary vein runs through this channel, and connects to the suboccipital venous plexus. The bleeding can be stopped with bone wax and later on using "hot drilling" with diamond drill.

A second medium or large curved retractor is inserted from the caudal part of the incision to maximize the exposure.

One burr hole is placed at the posterior border of the exposed bone and the underlying dura is carefully detached with a curved dissector. The curved dissector can be also inserted from the caudal direction through the foramen magnum, but only close to the midline and with minimal force. The first cut with the craniotome is directed from the burr hole slightly superior and towards the mastoid as far as it easily proceeds. Then the second cut is made from the burr hole in the caudal direction all the way to the foramen magnum, well posterior to where the vertebral artery enters intradural space. The bone ridge at the foramen magnum is quite thick and if the cut cannot be made directly, the bone should at least be thinned down with either drill or craniotome. With the two cuts ready, the bone is thinned down along the anterior border of the planned bone flap with either craniotome or high-speed drill. The bone flap is then cracked and removed. The anterior borderline of the craniotomy should be placed anterior to the intradural origin of the vertebral artery. The ligaments attached to the foramen magnum region are usually quite strong and they might need to be cut before the bone flap can be lifted. Removal of the bone is often followed by heavy venous bleeding either from the paravertebral venous plexus or the dural venous sinus surrounding the foramen magnum. Lifting the head higher, tamponation with Surgicel or injecting fibrin glue settles the situation.

With the bone flap removed, the bony window needs now to be extended in the anterior direction. The table is lifted higher to have a better view towards the condyle and then, using a high-speed drill, bone is removed in this direction. We prefer to use a diamond drill as it also

coagulates bleedings from the bone. We do not remove the occipital condyle or skeletonize the sigmoid sinus. Also the hypoglossal canal is left intact. If the mastoid air cells are opened, careful waxing and muscle or fat grafts with fibrin glue are applied during closure to prevent post-operative CSF leak. In case the C1 extension for the approach is planned, C1 hemilaminectomy is carried out next. The C1 lamina, which was exposed earlier, is drilled away with a high-speed drill. Drilling starts close to the midline and extends towards the transverse foramen. Usually, it is not necessary to remove all the bone covering the vertebral artery inside the transverse foramen, as we seldom need to mobilize the artery. With the bone removed, the ligament is removed to expose the dura of the lateral spinal canal, but with care to not harm the C2 root.

The dura is opened posterior to the intradural origin of the vertebral artery with a straight incision, which is curving anterior at the most cranial part of the craniotomy. Sutures extending over the craniotomy dressings are used to lift the dura and to prevent oozing from the epidural space. CSF can be released from the foramen magnum that can be well accessed with this approach. During all further steps of the dissection a lot of care is needed not to sever the lower cranial nerves. It might be necessary to lift the cerebellar tonsil a little to access the structures on the lateral aspect of the brain stem hidden by the tonsil.

Closure is performed in the same way as with the retrosigmoid approach. The dura is closed watertight if possible, the bone is placed back, all the mastoid cells are occluded, often with a fat or muscle graft, and the wound is closed in layers. The C1 hemilaminectomy is left as such.

*T&T:*

- *Park bench position, spinal drainage useful*
- *Straight, rather low-placed incision*
- *Bone removed laterally only as much as needed, excessive bone removal avoided*
- *Occipital condyle is not resected, occipito-cervical fixation not needed*
- *Cutting of 1-2 denticulate ligaments helps in releasing tension of the medulla*
- *Vertebral artery can be temporarily clipped also extracranially*
- *VA, PICA and lower cranial nerves identified – relation to the lesion determinates how to proceed to the lesion*
- *Respect the IX-X cranial nerves, even temporary dysfunction is dangerous*



## 5.7. PRESIGMOID APPROACH

In our practice, for lesions purely in the posterior fossa we prefer the retrosigmoid approach and for those only in the middle fossa the subtemporal approach. But for lesions that extend to both middle- and posterior fossa, we use a combination of these two approaches: the presigmoid-transpetrosal approach with partial petrosectomy. For convenience reasons, we call this approach just "presigmoid approach". The presigmoid approach classically refers to an approach that is used to access posterior fossa anterior to the sigmoid sinus by means of performing a transmastoid approach. This classical approach gives only very limited access to the middle fossa and should not be confused with the approach we call presigmoid approach, which refers to an approach with by far wider exposure but less drilling of the mastoid.

### 5.7.1. Indications

We use the presigmoid approach to access mainly two types of lesions: (a) low-lying basilar tip and trunk aneurysms; and (b) petroclival tumors, mainly meningiomas. Most basilar tip aneurysms can be accessed either by (a) trans-Sylvian route, if they are located high above the posterior clinoid, or (b) by subtemporal approach if they are at or just below the level of the posterior clinoid. Infrequently, the basilar tip is located extremely low below the posterior clinoid, where the aneurysm itself can be accessed via the subtemporal route but placing the temporary clip on the basilar artery would not be possible. For such aneurysms we use the presigmoid approach that combines access from both the middle and the posterior fossa. The other type of aneurysms requiring the presigmoid approach are basilar trunk an-

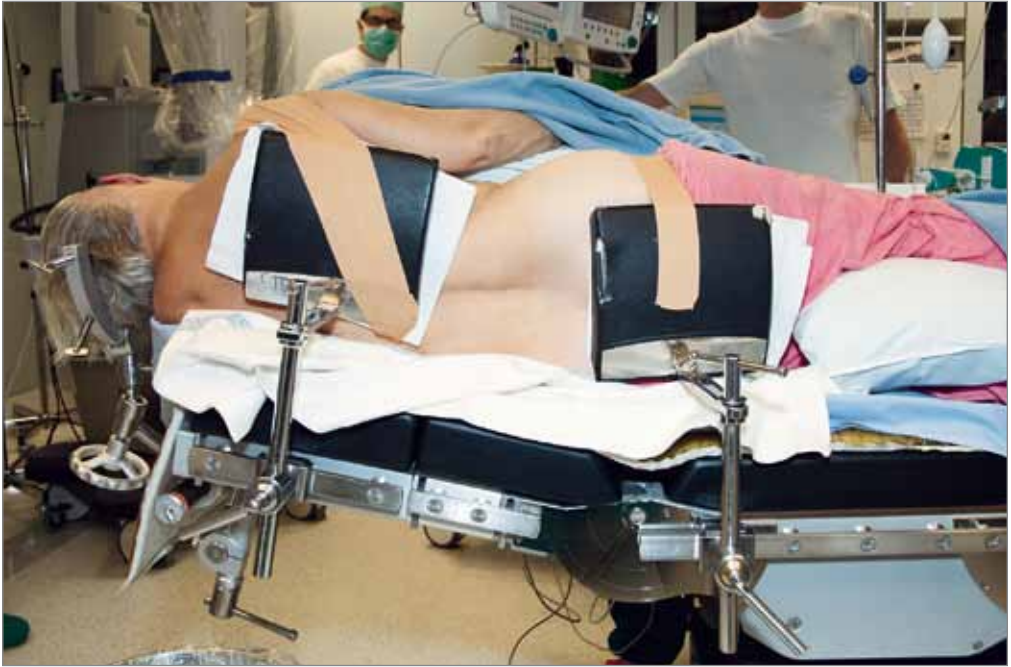

Figure 5-6 (a). Presigmoid approach. See text for details.



eurysms. The presigmoid approach allows good visualization of the midbasilar region as well as the posterior parts of the middle fossa and the petrous bone. The presigmoid approach can also be used to access the P2 segment of the posterior cerebral artery in certain bypass procedures. On the other hand, the presigmoid approach is time consuming (even in experienced hands it takes at least one hour), it is possible to injure the transverse or sigmoid sinus, and the risk of postoperative CSF leak is much

higher than in the simple subtemporal or retrosigmoid approach. So, the presigmoid approach should be used with caution and only when truly necessary. The mastoid air cells are always opened during the presigmoid approach, and a very careful covering with temporal muscle or fat is necessary when closing.

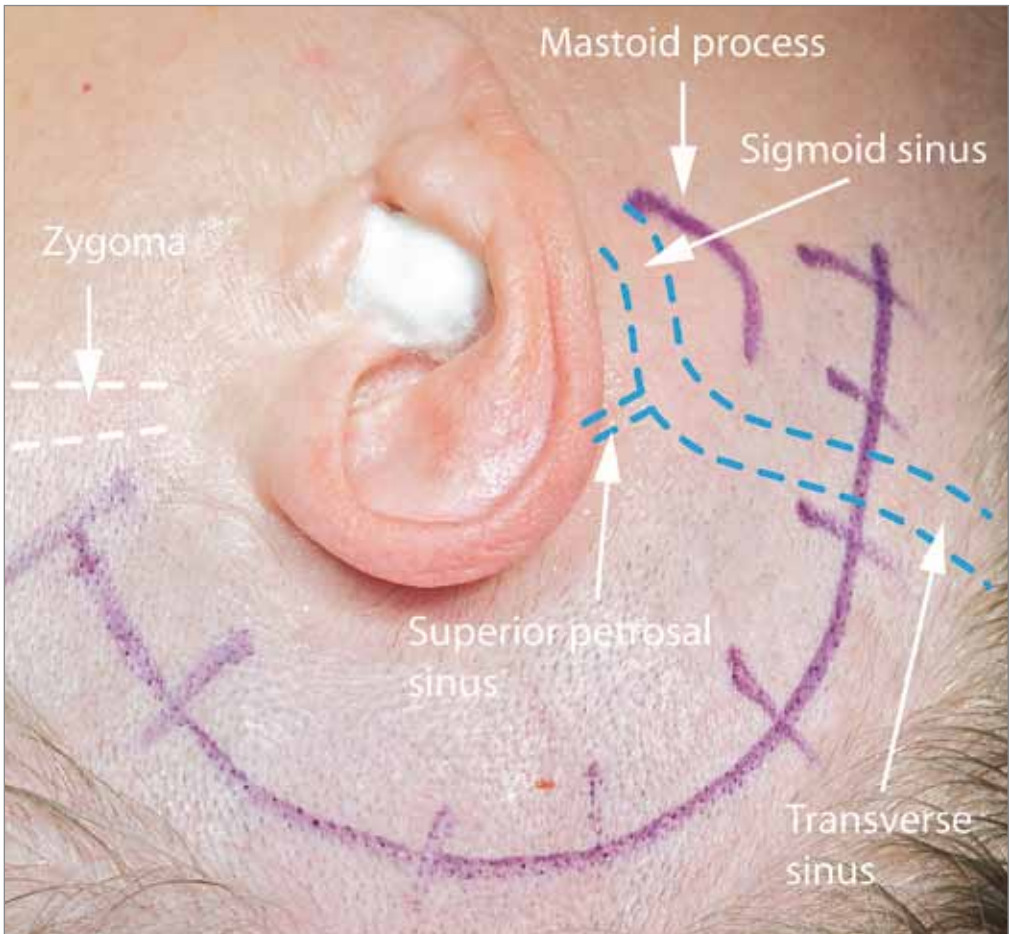


Figure 5-6 (b). Presigmoid approach. See text for details.

### 5.7.2. Positioning

The patient is placed in lateral park bench position like for the subtemporal approach (see section 5.4.2.) (Figure 5-6a). A lumbar drain or ventriculostomy is mandatory in the same way as for the subtemporal approach. It is not possible to execute the presigmoid approach without a well-relaxed brain as the brain retraction would cause inadvertent damage.

### 5.7.3. Skin incision and craniotomy

The skin incision starts in front of the ear curving backwards in the same fashion as for the subtemporal approach (Figure 5-6b). The difference is that the incision then extends caudally about one inch behind the mastoid line as it would do for the retrosigmoid approach. The skin-muscle flap is retracted in one layer fronto-caudally with strong spring hook retraction (Figure 5-6c). The muscles are detached all the way down to the external auditory canal and the whole temporal bone is exposed, including

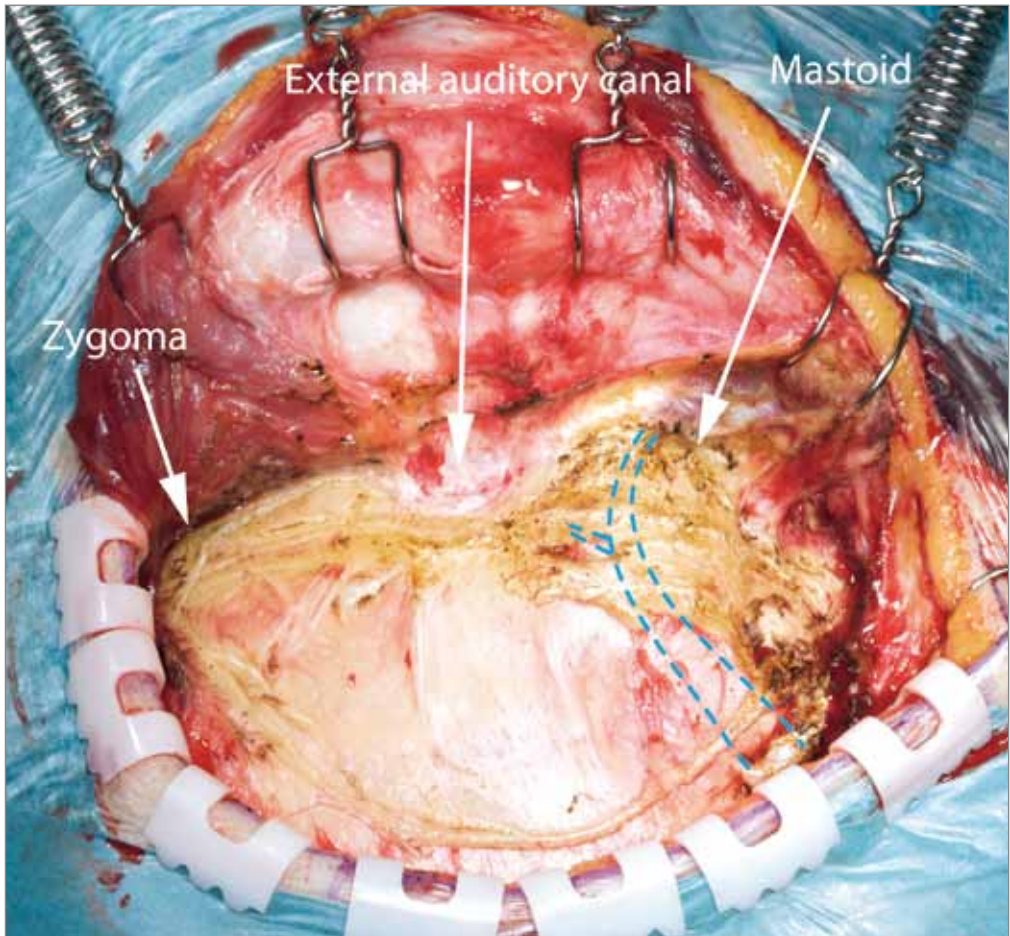


Figure 5-6 (c). Presigmoid approach. See text for details.

the origin of the zygoma and the mastoid process. Care is taken not to accidentally enter or tear the skin near or at the external auditory canal, since the skin is very thin here.

Three to four burr holes are usually used (Figure 5-6d). The first one just at the anterior border of the exposed area of the temporal bone close to the origin of the zygoma. The second one at the most cranial part of the exposed temporal bone. The third one at the posterior border

inferior to the transverse sinus, and optionally a fourth one at the posterior border superior to the expected course of the transverse sinus, especially if dura is very tightly attached to the inner surface of the skull, in which case there is a high risk of injury to the venous sinuses. The dura is carefully detached with a curved dissector and Yaşargil-type flexible dissector. At the level of the posterior fossa the aim is to get close to the sigmoid sinus. Using a craniotome the burr holes are connected (Figure 5-6e). One

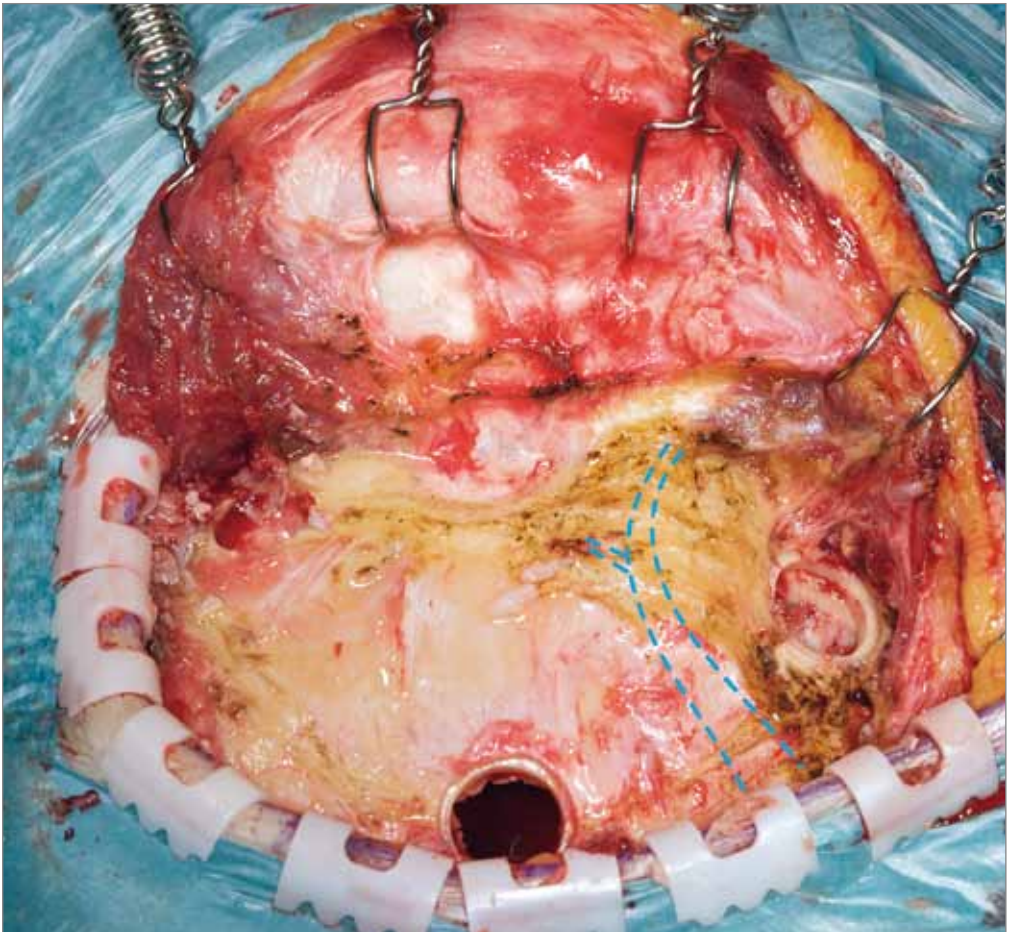


Figure 5-6 (d). Presigmoid approach. See text for details.

additional cut is made from the burr hole closest to the zygoma caudally and slightly posterior towards the anterior aspect of the petrous bone. Then a second cut is made from the posterior fossa burr hole caudally and curving anterior towards the mastoid process. Finally, the remaining bone ridge is thinned down in a curved fashion with craniotome blade or a high-speed drill and the bone flap is cracked and detached. It requires special attention to not accidentally tear the sigmoid sinus. Sometimes, there are emissary veins running inside the bone and connected to the junction of the transverse and sigmoid sinuses that may start

to bleed heavily while removing the bone. Elevating the head, Surgicel tamponation and bipolar coagulation usually solve the problem.

With the bone flap removed, we normally see the transverse sinus, dura of the posterior fossa, and dura of the middle fossa. The junction between the transverse and sigmoid sinuses is at least partially visible. The dura should be slack due to the lumbar drain. It would be very difficult to proceed with the exposure of the presigmoid dura unless the already exposed dura and the sinuses can be slightly compressed. With the help of a blunt, straight dissector or

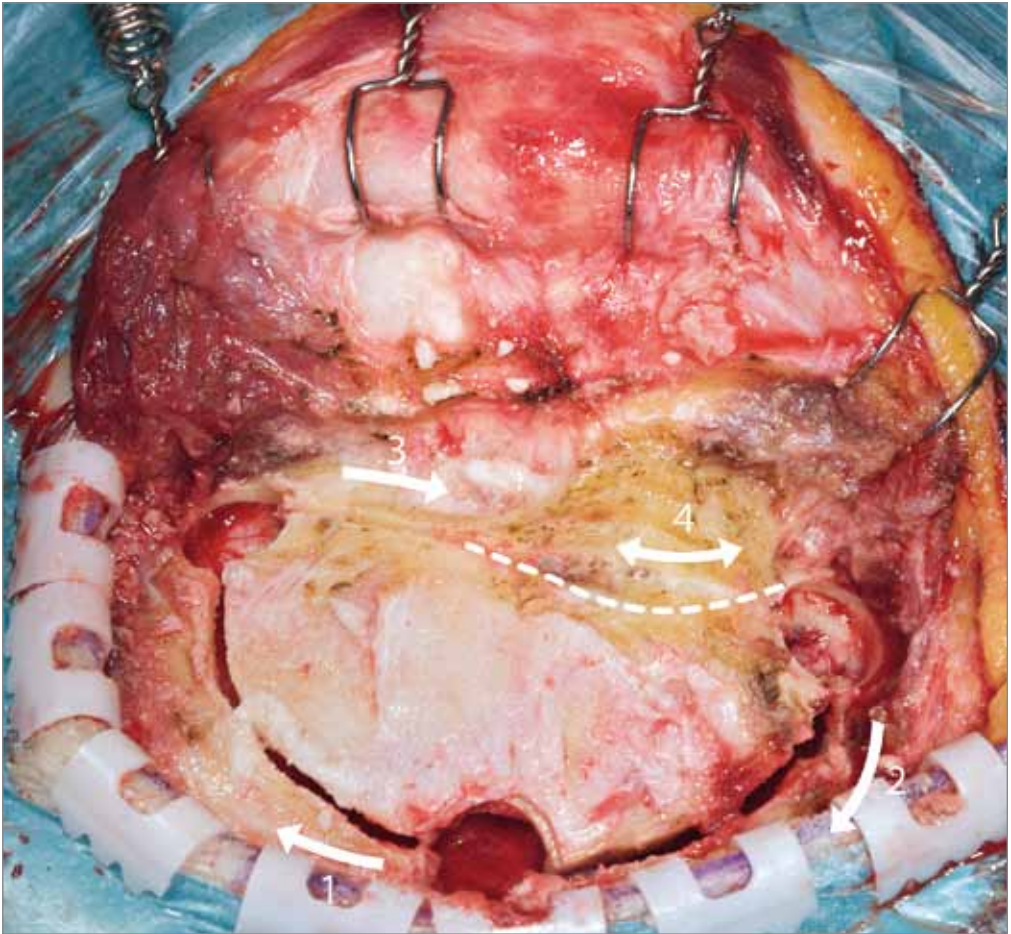


Figure 5-6 (e). Presigmoid approach. See text for details.

elevator the dura is detached from the temporal bone. Special care is taken not to accidentally tear the sigmoid sinus. Detaching the dura has to be performed both from the posterior fossa side as well as from the middle fossa. Retractors are then put in place to compress the dura downwards away from the mastoid and the petrous bone to provide a safe margin for drilling.

Drilling of the mastoid and the petrous bone is often the most time-consuming part of the presigmoid approach (part of the temporal bone removed by drilling is shown schemati-

cally; Figure 5-6f). It is done under the microscope. The high-speed drilling starts with a cutting ball drill head to remove the roughest edges but soon we switch to a large diamond drill. Unlike the classical transmastoid approach, we start drilling from the posterior and superior border of the exposed temporal bone and we proceed deeper in layers. We do not try to perform total mastoidectomy, and neither to approach the semicircular canals. Only as much drilling is performed as is really necessary to expose the dura anterior to the sigmoid sinus, the superior petrous sinus and the dura of the floor of the middle fossa. It is safer to perform

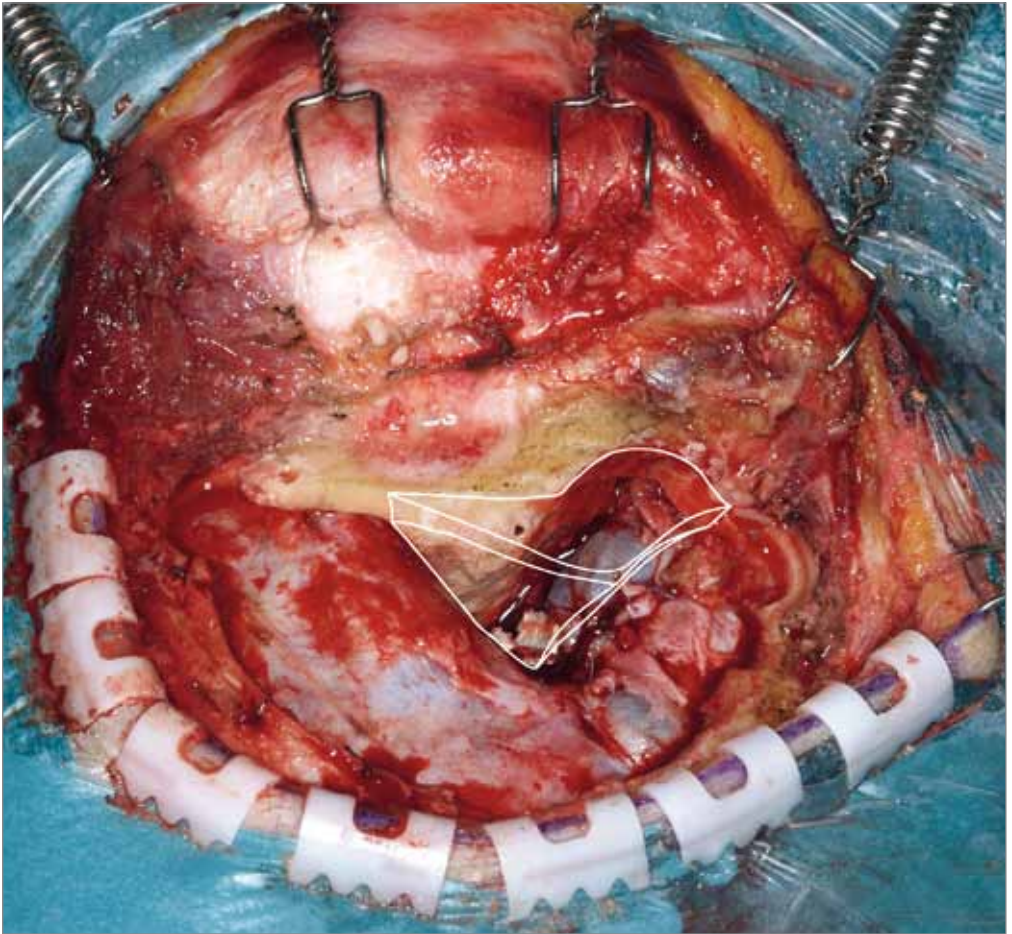


Figure 5-6 (f). Presigmoid approach. See text for details.

drilling in the deeper parts under higher magnification of the microscope. By making the initial craniotomy large enough extending well in the retrosigmoid area, the drilling angle for exposing safely the whole sigmoid sinus is better and requires less bone to be removed from the anterior parts of the mastoid region. There is also less risk for accidentally entering the semicircular canals. The temporal bone is very hard in general, except for the mastoid region containing a lot of air cells. The drilling proceeds stepwise with the dura being detached each time before moving a little deeper. When the drill is not rotating, the ball shaped diamond drill tip can be used for detaching the dura instead of a dissector.

Finally, after partial petrosectomy, the sigmoid sinus with its steep descending S-shape should be fully visualized, the presigmoid dura exposed, the superior petrous sinus visible, and the posterolateral part of the middle fossa accessible (Figure 5-6g). Dural incision of the posterior fossa is made under microscope some millimeters anterior to the sigmoid sinus with the incision extending all the way towards the superior petrous sinus, which is still left intact (Figure 5-6g). If necessary, the cerebellopontine cistern can be carefully entered and additional CSF released from there. Dura of the middle fossa is then opened in a curved fashion and everted basally, the incision again extending towards the superior petrous sinus. The petrous sinus (arrow; Figure 5-6h) is then divided and

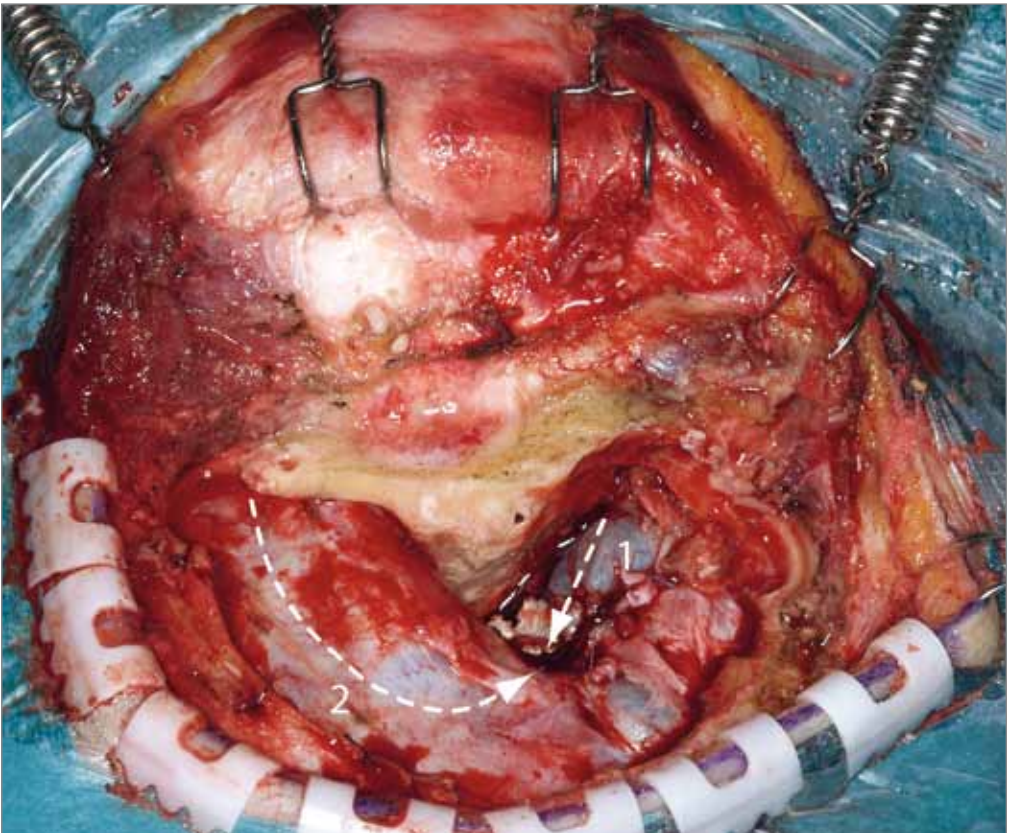


Figure 5-6 (g). Presigmoid approach. See text for details.

the two incisions connected. When dividing the superior petrous sinus, we prefer using sutures since these can be used also to lift the dura. Each suture is placed twice around the sinus through the tentorium and a knot is tied. The sinus is divided in between these two sutures. Hemoclips can slide easily off and cause unwanted bleeding.

With the dura opened (Figure 5-6h), one more step remains: the cutting of the tentorium. Before cutting the tentorium, we enter subtemporally and inspect for the course of the fourth nerve. The tentorium needs to be divided well anterior to the drainage of vein of Labbé and posterior to the tentorial insertion of the fourth nerve. Usually, there are also less venous

sinuses inside the tentorium at this level, which helps the task. We start cutting the tentorium in stepwise manner from the lateral (cortical) direction. Before each cut the tentorium is coagulated with blunt bipolar forceps, it is checked from supra- and infratentorial direction, and a small cut is made. This is continued until the tentorial edge, where the course of the fourth nerve is once again checked infratentorially before making the final cuts. A small cottonoid can be used to protect the fourth nerve. The mobile anterior portion of the tentorium can be folded over and tucked in the anterior direction beneath the temporal lobe. If necessary, retraction of the anterior tentorial portion can be increased by fixing the folded part of the tentorium to the dura of the middle fossa

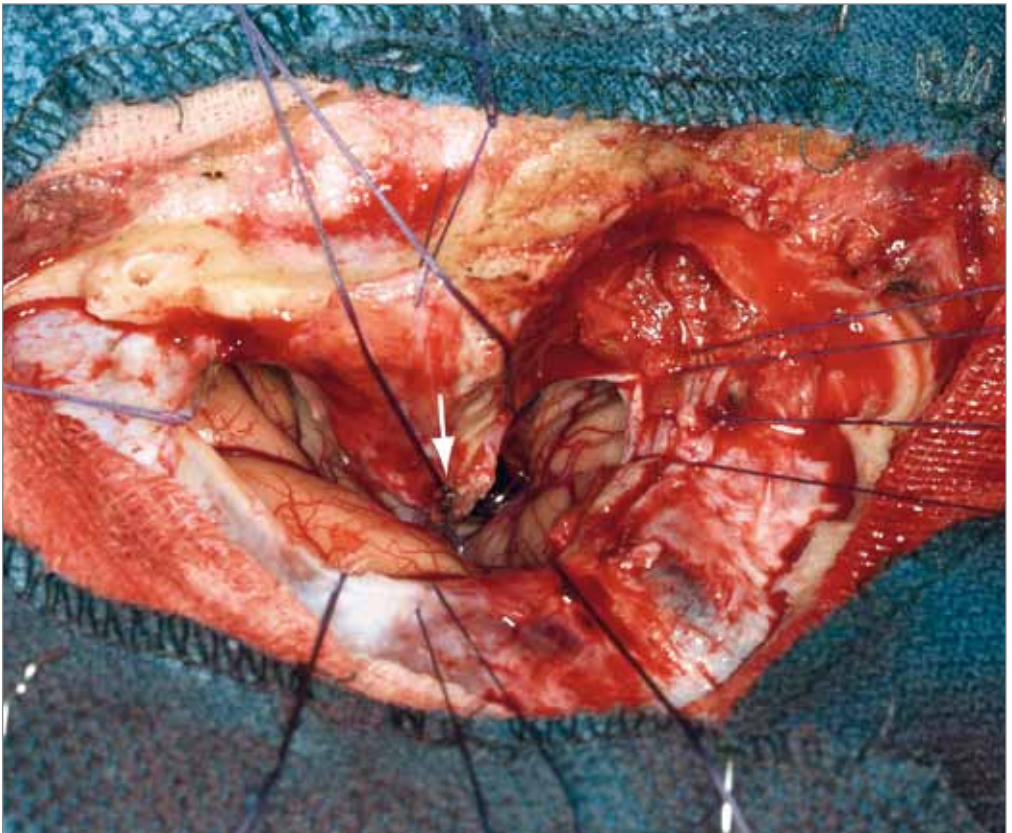


Figure 5-6 (h). Presigmoid approach. See text for details.

with a small aneurysm clip like in the subtemporal approach. During all steps of opening the dura and temporal lobe retraction, special care must be paid not to overstretch or tear the vein of Labbé.

When closing, special care must be taken to prevent postoperative CSF leak. The dura should be closed water tight, and all the mastoid air cells need to be covered. We usually use fat graft, everting of the inner portion of the temporal muscle over the air cells and attaching it to the dura, bone wax, and fibrin glue to seal the dura off. The cut in the tentorium is not repaired, but the tentorium is everted back in its normal anatomical position.

*T&T:*

- *Park bench position, always spinal drainage*
- *Reversed J-shaped flap starting in front of the ear and terminating behind the mastoid*
- *One layer skin-muscle flap with heavy retraction of the flap downwards until the level of the external ear canal*
- *3 to 4 burr holes, and cracking of the basal part after partial drilling above transverse and sigmoid sinuses*
- *Additional bone removal under the microscope until sacculus/internal acoustic canal is reached*
- *Presigmoid dural opening continues temporally and suboccipitally with stitch ligation of the superior petrosal sinus*
- *Preserve the draining veins (vein of Labbé and others)*
- *The tentorium is cut under the microscope behind the trochlear nerve and in front of the vein of Labbé*



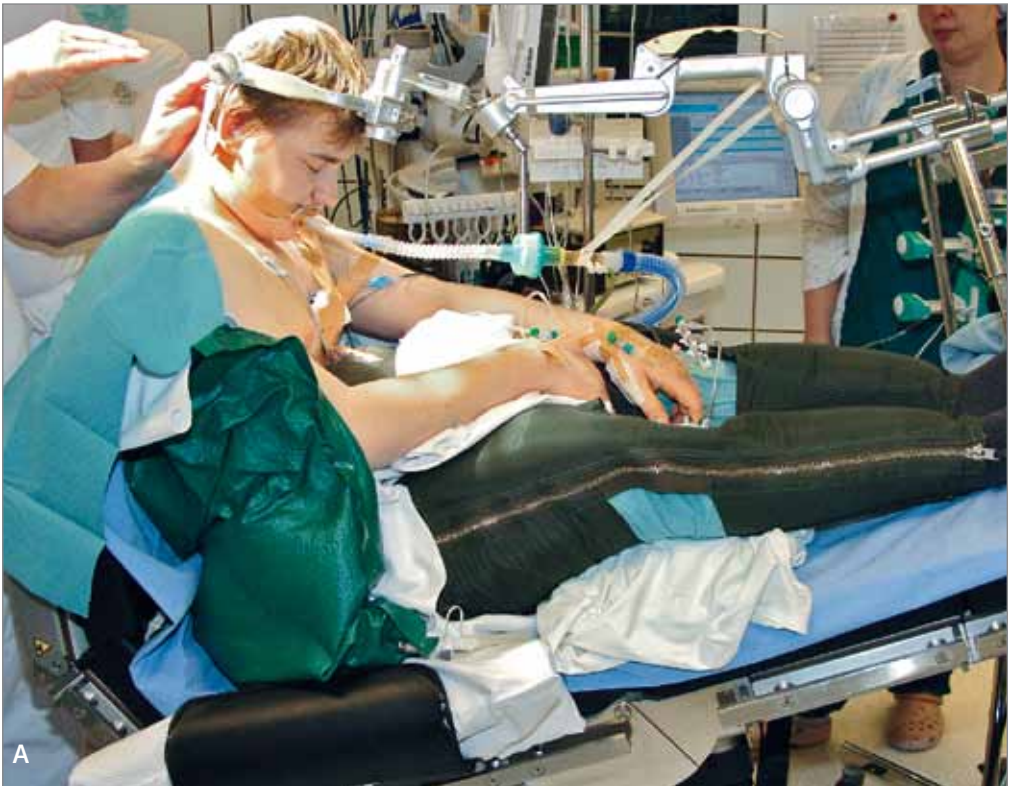

## 5.8. SITTING POSITION – SUPRACEREBELLAR INFRATENTORIAL APPROACH

There are two types of posterior fossa midline approaches that we use in Helsinki: (a) the supracerebellar infratentorial approach; and (b) the posterior midline approach into the fourth ventricle and the foramen magnum region. What both of these approaches have in common is, that the patient is kept in sitting position. The advantages of the sitting position compared to the prone position are that the use of gravity facilitates drainage of any bleeding and CSF, decreasing the venous congestion, and it offers a superior anatomical view for certain pathologies. The disadvantages on the other hand include risks of air embolism, myelopathy of the cervical spine, and hypotension. Risk-benefit decisions have to be made based on patient's age, general condition, and other diseases. Especially older patients with heart

problems are unlikely to tolerate sitting position. Patients with septal defects of the heart, such as patent foramen ovale, and blood flow across this defect have a much higher risk for air embolism and should be considered for a different approach. Also patients with significant cervical spine disease require extra caution to avoid spinal cord compression injury. The anesthesia risks and special measures for sitting position are described in detail in section 3.7.3.

During sitting position, an even closer cooperation between the neurosurgeon and the anesthesiologist is required than usually. If the anesthesiologist detects any signs of possible air embolism, he or she should immediately inform the neurosurgeon, who reacts without



### 5.8.1. Indications

any delay and takes appropriate counteraction measures (Table 5-1). In many institutions the sitting position was earlier used regularly but gradually went out of fashion due to the fear of complications. All we can say is that in Helsinki the sitting position is being used regularly, safely and effectively in all those cases where we see a true benefit offered by the position as compared to other possible approaches. We take only simple practical precautions and minimum of complex preoperative investigations. A skilled and dedicated team together with certain preventive measures are needed to avoid possible complications as much as possible.

The supracerebellar infratentorial approach is used to reach lesions located at the pineal region and the tectum of the midbrain. We use the supracerebellar infratentorial approach most often for pineal region lesions, since this approach evades most of the large draining veins of the pineal region located superior to the direction of this approach. In the sitting position, the gravity pulls on the cerebellum, which falls down and exposes this region. In addition, the supracerebellar infratentorial approach can be also used to gain access to tentorial meningiomas, some AVMs, aneurysms and intrinsic tumors of the superior surface of the cerebellum. Utmost vigilance is required when operating on such a pathology near the transverse sinus and confluence of sinuses. Preparation and caution is required during all stages

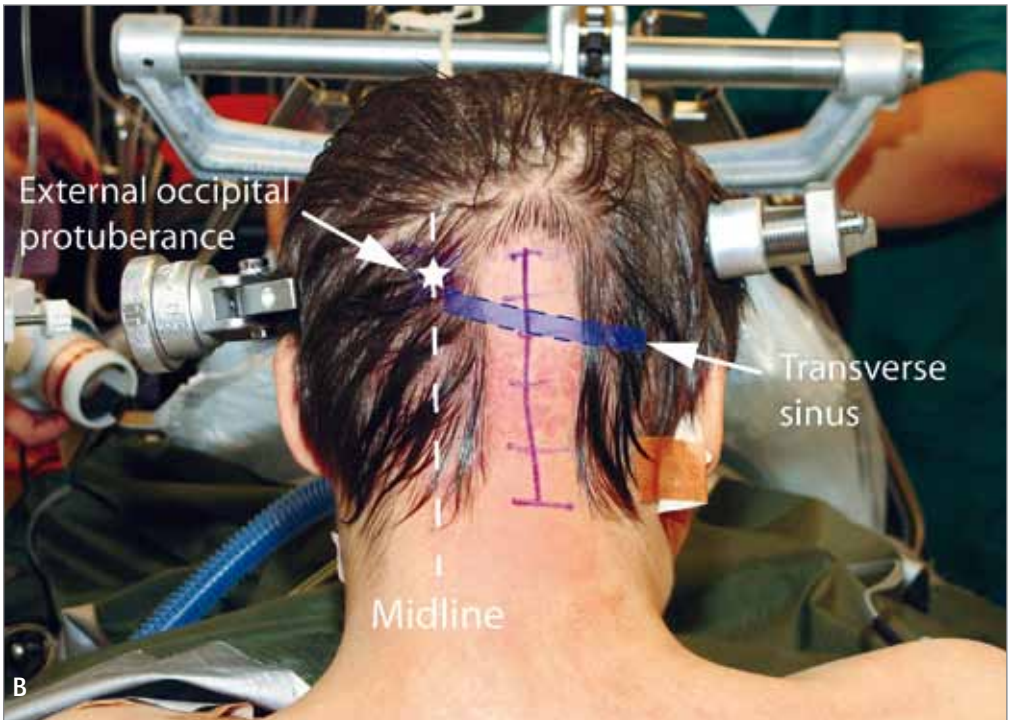


Figure 5-7 (a-b). Supracerebellar infratentorial approach. See text for details.

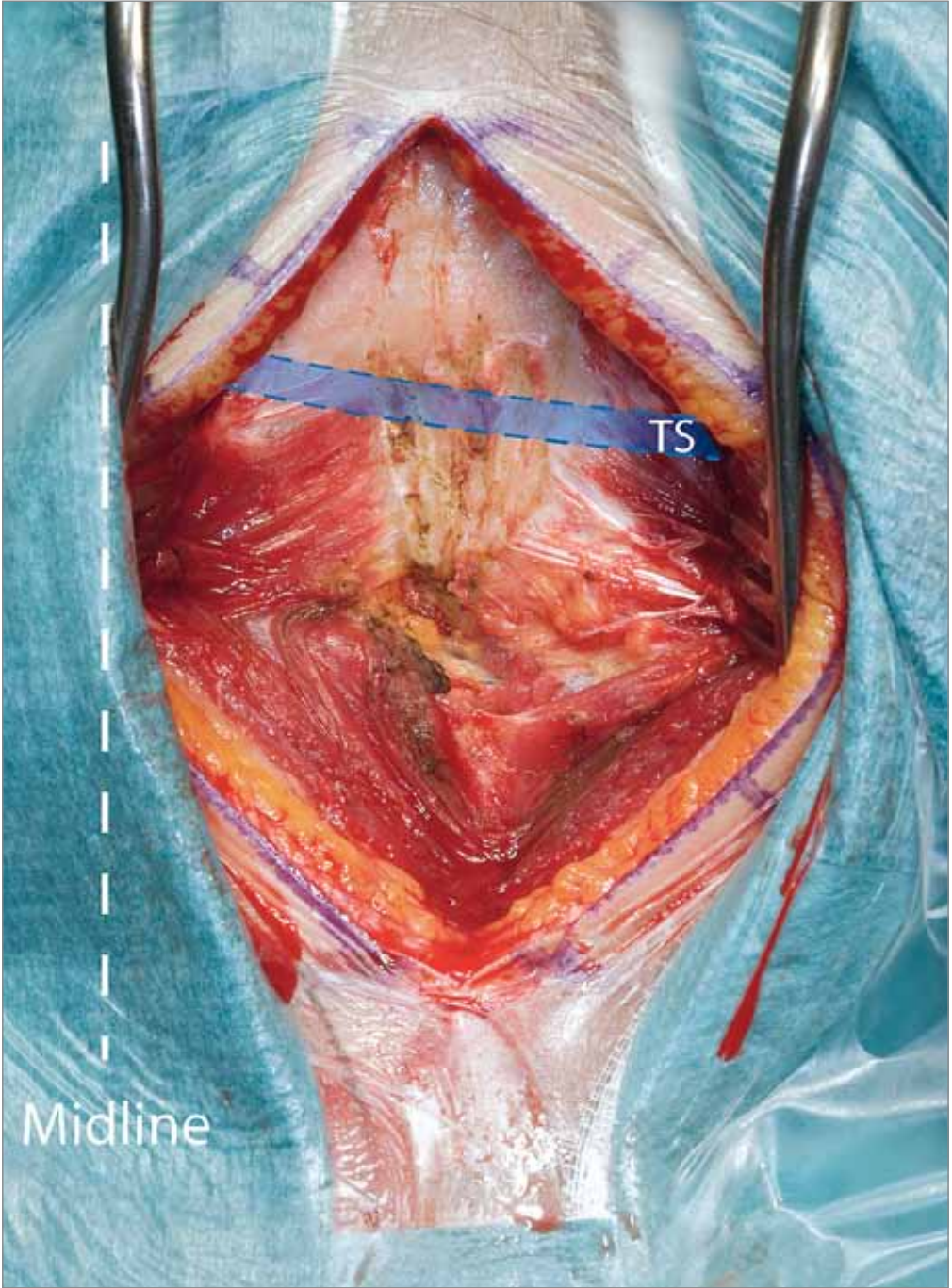


Figure 5-7 (c). Supracerebellar infratentorial approach. See text for details.

of the craniotomy and also when approaching the possible attachment to the tentorium or the region of the venous sinuses. A small opening in the venous sinus can easily occur but is difficult to notice in the sitting position due to low venous pressure.

The supracerebellar infratentorial approach can be carried out either as a direct midline approach or a paramedian approach. Earlier we used the midline approach quite frequently, but nowadays we have switched almost exclusively to the paramedian approach. With the paramedian approach there are several advantages compared to the classical midline supracerebellar approach. Apart from fewer veins in the surgical trajectory, the other advantage is that the tentorium does not rise as steeply upwards lateral from the midline, so less retraction/compression of the cerebellum is needed. In addition, there is no need to extend the craniotomy over the sinus confluens in a paramedian approach, which decreases the risk of possible venous damage and air embolism. The greatest disadvantage of the paramedian approach

is the more difficult orientation and choosing the right trajectory towards the centre of the quadrigeminal cistern and the pineal region.

### 5.8.2. Positioning

Placing the patient in a sitting position is a demanding task and requires an experienced team. There are several key factors that need always to be remembered (Table 5-1). The actual practical tricks may vary from department to department. Here we describe in detail how the sitting position is executed in Helsinki. The sitting position requires special equipment and a mobile operating table.

What we call a sitting position in Helsinki would be probably better described as praying position or forward somersault position, with the upper torso and the head bent forward and downward (Figure 5-7a). During surgery, the operating table is often tilted even further forward to gain optimal view into the posterior fossa along the tentorium. A very important

*Table 5-1. General setup for sitting position in Helsinki*

- Mobile OR table
- Mayfield-Kees head clamp
- Special system for attaching the head frame to the table (trapeze)
- G-suit trousers (inflated to 40 mmHg) or loosely tied elastic bandage
- Urinary catheter, not kinked against the G-suit
- Shoulders left free at least 10 to 15 cm above the cranial edge of the table
- Large suction cushion wrapped around the upper body and arms to prevent movement
- Pillow beneath knees for 30 degree flexion, knees kept in straight line
- Flat board against the feet to prevent sliding caudally
- Large pillow on top of the belly to support both arms
- All the pressure areas protected
- Shoulder taped to the table to prevent falling forward
- Safety belt around the pelvis
- At least two fingers must fit between the chin and the sternum
- The endotracheal intubation tube secured to the clamp system
- Anesthesiologist must have access to the intubation tube and both jugular veins
- Precordial Doppler device above the right atrium

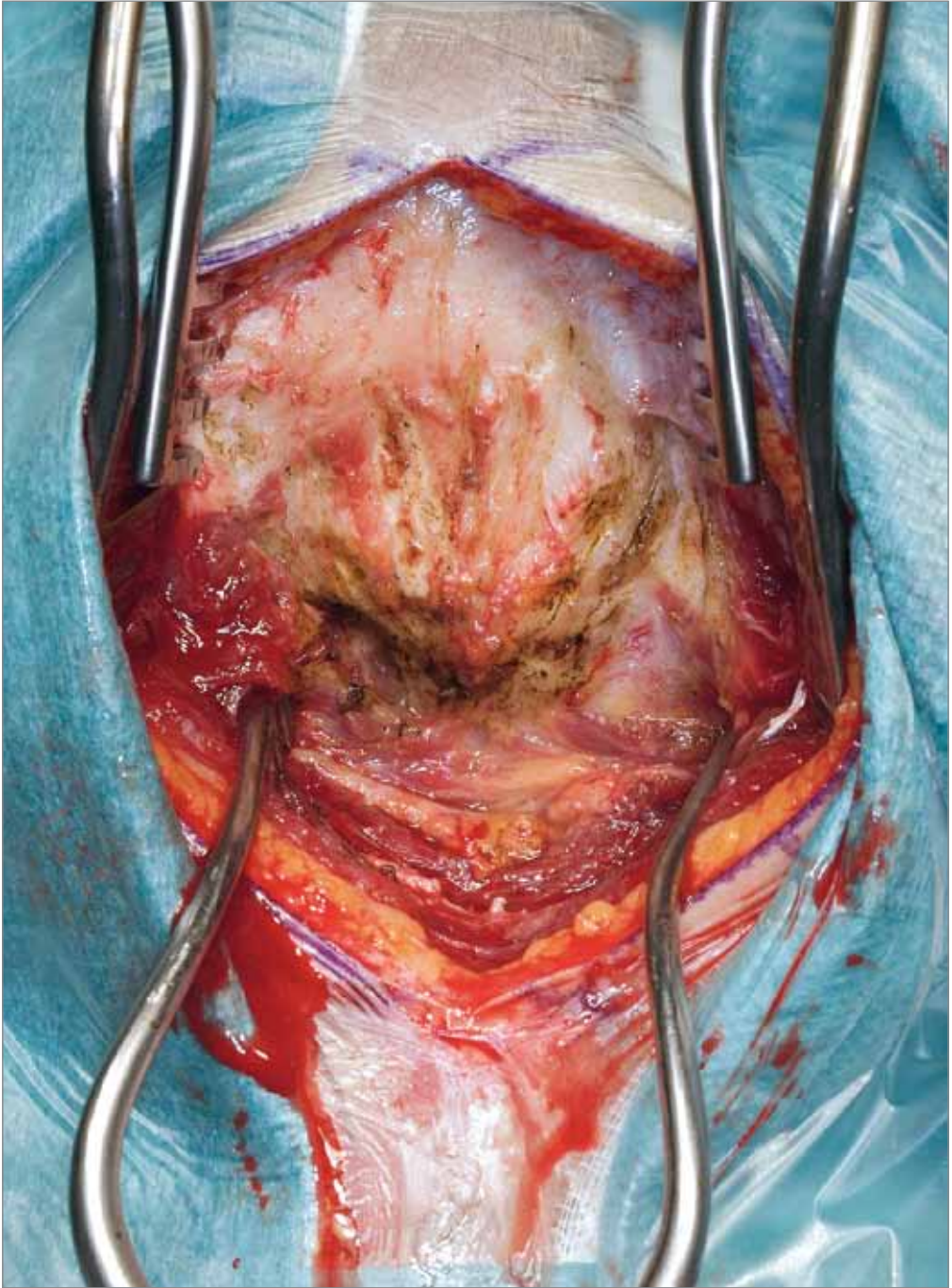


Figure 5-7 (d). Supracerebellar infratentorial approach. See text for details.

factor when planning the supracerebellar infratentorial approach is to remember that the tentorium is actually shaped like a tent, and it rises steeply upwards especially close to the midline. Bending the patient's head forward for about 30° makes the tentorium almost horizontal providing good viewing angle even to the most cranial portions of the posterior fossa. At the same time it allows the neurosurgeon to rest his or her arms on the patient's shoulders and back as a form of arm support. This is less tiring for the neurosurgeon than if the approach angle was more upward.

The patient is placed on the operating table so that there are two table elements supporting the upper body. The pelvis should be at the joint from which the table can be bent into a 90° angle. The whole upper body and pelvis rests on a large suction mattress. In addition the patient is fitted with G-suit trousers that are inflated to the pressure of 40 mmHg. If a G-suit is not available, as well as in small children, both lower limbs must be loosely tied with elastic bandage from the toes all the way up to the groin. The sitting position is the only position where we routinely prefer to use Mayfield head clamp instead of the Sugita head frame. There is one extra joint on the Mayfield clamp that makes head positioning easier for the sitting position. The three pin Mayfield head frame is attached to patient's head before the actual positioning starts. The neurosurgeon then holds the head until the position is finalized and the head frame fixed to the trapeze clamp system.

The positioning starts with bending of the table into anti-Trendelenburg position while simultaneously elevating the upper torso. A 90° angle is usually the most any modern OR table allows at one joint. Once this has been reached, it is necessary to check that the patient is sit-

ting so that the shoulders reach 10–15 cm above the level of the most cranial edge of the table. If not, as is usually the case with children, then one or several extra cushions need to be inserted underneath the buttocks to lift the patient upward. Without this free shoulder margin, the optimal approach angle from caudal direction cannot be achieved later during surgery. With the shoulders at optimal height, the most cranial table section is bent forward, in most tables manually, for about 30–40°. This pushes the upper body and shoulders forward. The Mayfield head frame is then fixed to the trapeze clamp system and all the joints are tightened, and the locking screw on the head frame is locked. A pillow is inserted beneath the knees to provide little flexion of the knees. A flat board, fixed to the table railings, is placed to keep the ankles in neutral position and to prevent the patient from sliding downwards. The arms are rested on a large pillow on top of the belly. Finally, the large suction mattress which was earlier placed beneath the patient's upper torso is wrapped around the upper body and the arms and deflated to form a sort of shell protecting the whole upper body and preventing any undesired slipping or sliding. Additionally, both shoulders can be fixed to the OR table with thick tape to prevent the upper body from falling forward during extreme forward tilting of the table.

The head position varies slightly depending on the planned approach. Irrespective of the approach, the neck is always flexed forward. This should not be overdone to prevent compression of the airways as well as the possible spinal cord injury. At least two fingers should fit between the chin and the sternum. If the plan is to use a midline incision, then the head should not be rotated or tilted lateral at all. It is only flexed with the nose pointing exactly forward. However, for the paramedian approach a slight

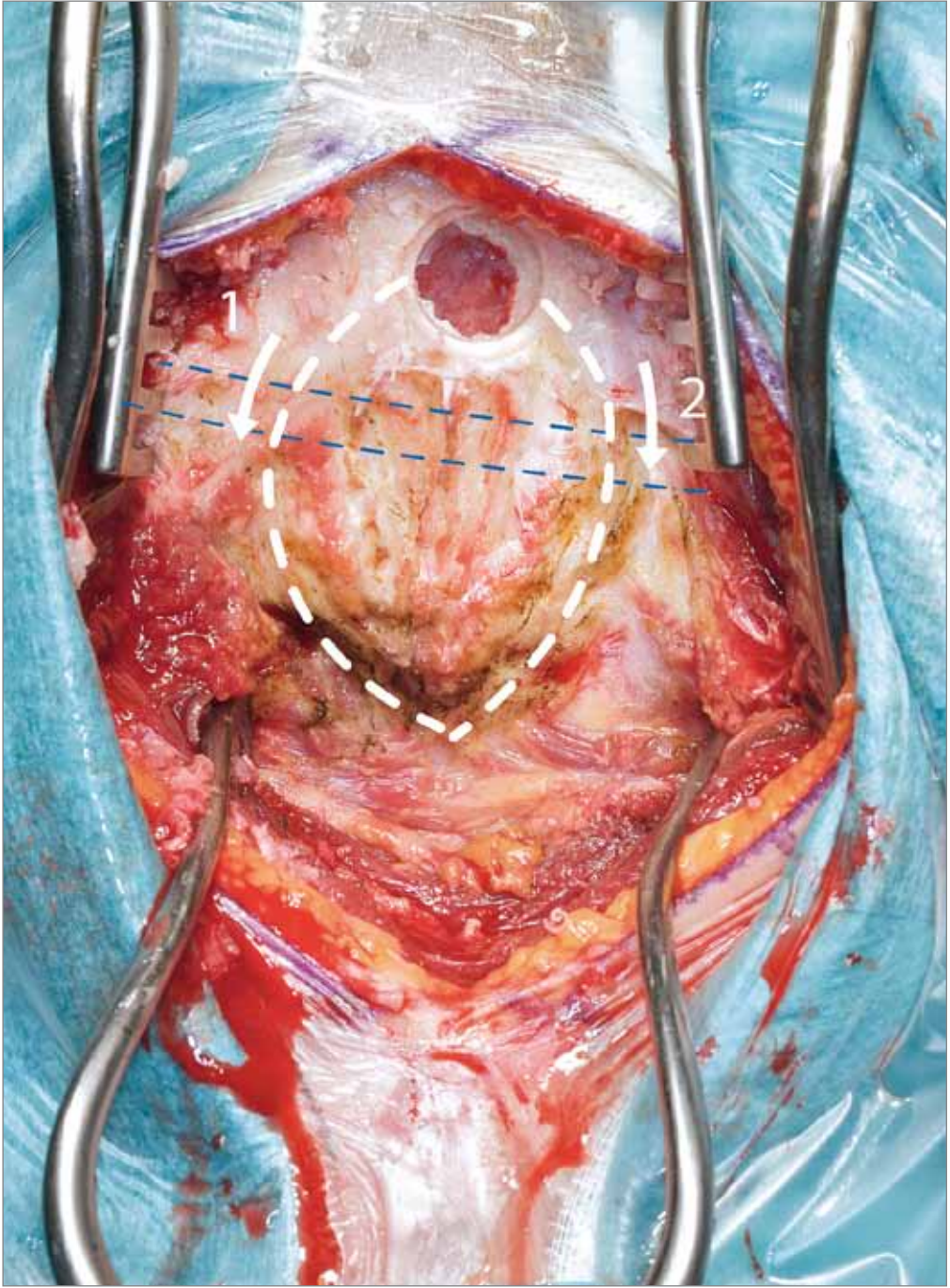


Figure 5-7 (e). Supracerebellar infratentorial approach. See text for details.



head rotation is necessary. The head is rotated 5–10° to the side of the planned approach, without any lateral tilt.

With the patient in the proper position, a precordial Doppler device is attached over the right atrium and all the joints of the clamping system are checked once more to make sure that they are tightened. All the pressure points need to be covered with pillows. Special attention is paid to peroneal nerve at the lateral aspect of the knee which can easily get compressed if the knees fall outward. Safety belt is placed over the pelvic region.

### 5.8.3. Skin incision and craniotomy

A straight skin incision is planned 2–3 cm lateral from the midline (Figure 5-7b). The incision starts about an inch cranial from the external occipital protuberance (the inion) and extends caudally towards the level of the cranio-cervical junction. For a right-handed neurosurgeon a right-sided approach is more convenient if the target is located in the midline or lateralized to the right. The muscles are split in a vertical fashion all the way down to the occipital bone (Figure 5-7c). A curved retractor is used to spread the wound from the cranial direction. The muscle insertions are detached with diathermia and the occipital bone is exposed (Figure 5-7d). The medial border of the exposure is almost at the midline. A second curved retractor can be used to get a better exposure and additionally a third smaller curved retractor can be used caudally. It is enough to expose only about 3–4 cm of bone below the level of the transverse sinus, so that the exposure does not have to extend anywhere near the foramen magnum.

One burr hole is placed about 3 cm lateral from the midline over the occipital lobe superior to the transverse sinus (Figure 5-7e). In older patients with tightly attached dura a second burr hole can be placed inferior to the transverse sinus. The dura is carefully detached with a curved dissector especially along the transverse sinus. Two cuts with a craniotome are made to detach a 3–4 cm diameter bone flap (Figure 5-7e). Both cuts start from the burr hole, they curve sideways and join caudally exposing about 2 cm of the dura below the level of the transverse sinus. It is necessary to have the superior border of the bone flap above the transverse sinus to allow retraction of the transverse sinus upwards. Some drill holes are prepared for the use of tack-up sutures at the end of the procedure.

When detaching the dura and performing the craniotomy, the most critical area is the site of the sinus confluens; its lesion may cause fatal complications, and all efforts should be made to preserve it as well as both transverse sinuses. The medial border of the craniotomy should be left about 10 mm lateral from the midline. There are usually several venous canals running inside the bone close to the sinus confluence. By keeping the craniotomy lateral to this region, there is much less risk of opening the venous canals and subsequent air embolism. Even with these preventive measures, a sudden decrease in end-tidal CO<sub>2</sub> pressure or the sound from the precordial Doppler device is indicative of an air embolism. In such a situation the bone flap should be promptly removed, and the damaged vein sealed. Compression of the jugular veins by the anesthesiologist is extremely helpful in localizing the bleeding site. While sealing one possible bleeding site, the rest of the wound should be covered with a moistened swab. Meticulous waxing of the craniotomy edges closes the venous channels inside the bone, which

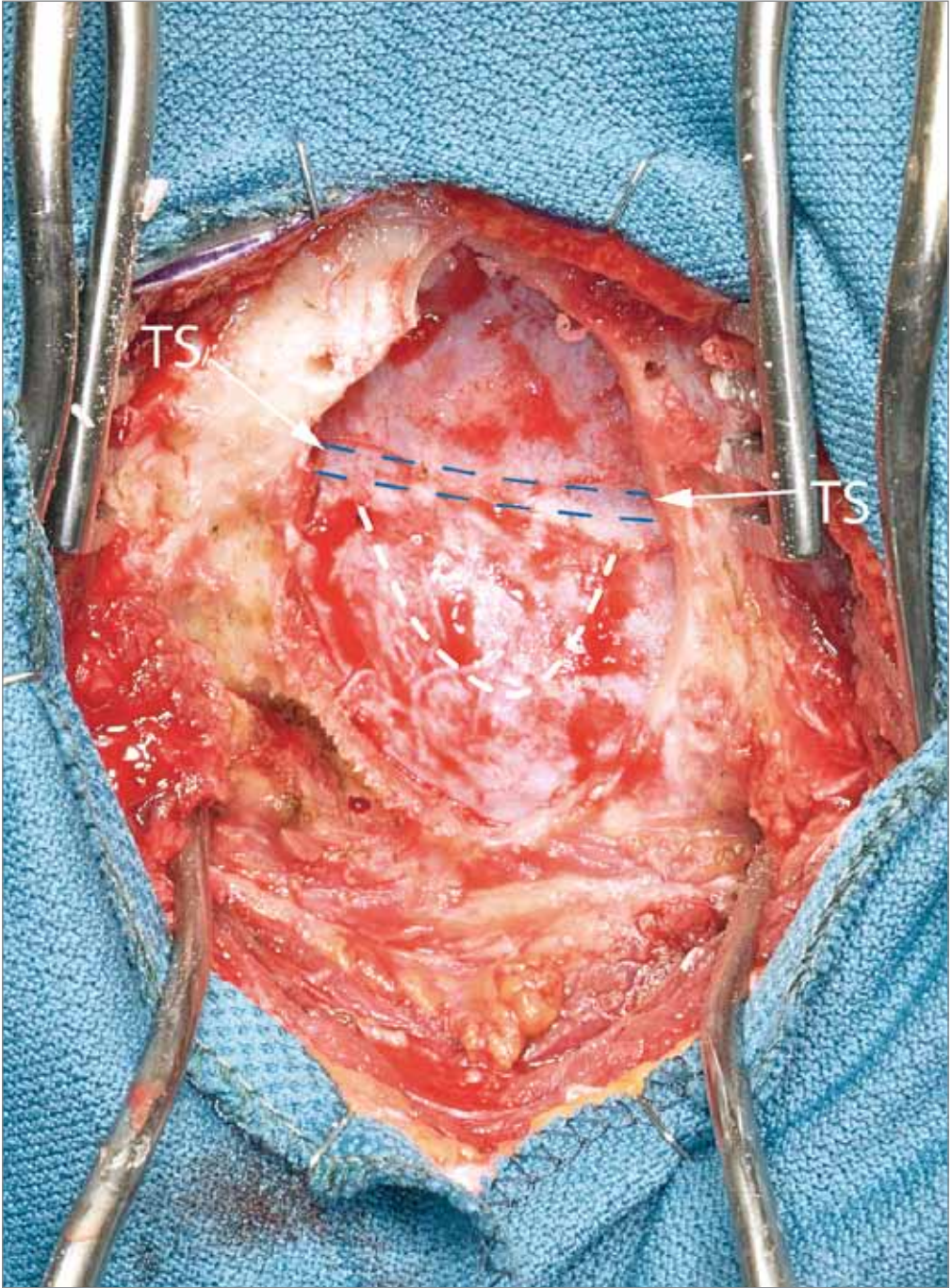


Figure 5-7 (f). Supracerebellar infratentorial approach. See text for details.

cannot be sealed otherwise. In general, the reaction to possible air embolism needs always to be swift and both the neurosurgeon and the anesthesiologist should be well familiar with all the counteraction measures (Table 5-2). In our series, we have had no major complications due to air embolism. With the situation under control, we proceed with the surgery, we do not abandon the procedure.

The dura is usually opened under the microscope to avoid accidental injuries of the sinuses. The dura is opened in a V-shaped fashion with the base towards the transverse sinus (Figure 5-7f). The dural flap is reflected cranially with several lifting sutures. Also the remaining dural edges are lifted with sutures placed over the craniotomy dressings to prevent both oozing from the epidural space as well as compression of the cortical cerebellar veins (Figure 5-7g). The occipital midline sinus can be usually avoided as the dural opening does not have to extend all the way to the midline. If this sinus is accidentally opened, it does not bleed profusely in the sitting position unlike in the prone position. The cut should be sealed immediately with one

or several sutures as sutures do not accidentally slide off like e.g. hemoclips do.

Since the approach is slightly lateral from the midline, there are usually no major bridging veins obstructing the view. The superior cerebellar vein and draining veins coming from the surface of the cerebellum are typically close to the midline and thus avoided in this approach. In case there is a vein obstructing the approach towards the pineal region it may be necessary to coagulate and cut it, preferably closer to the cerebellum than to the tentorium. In some cases, we even cut one or more of these veins early on (prophylactically), as they are much more difficult to treat if severed accidentally later during some of the critical steps of the dissection. It is better to save as many of the draining veins as possible to prevent venous infarction of the cerebellum.

Once the arachnoid adhesions and possible bridging veins between the cerebellum and the tentorium have been coagulated and cut, the cerebellum falls down, allowing a good surgical view without brain retraction. Opening of the

*Table 5-2. Action during air embolism in sitting position*

- Sudden drop in  $p\text{CO}_2$  is the most important clue of air embolism
- Anesthesiologist informs the neurosurgeon immediately
- Anesthesiologist compresses both jugular veins at the neck to increase the venous pressure
- If the bleeding point is seen, it is sealed (in muscle with coagulation, in bone with wax or glue, in dura by suturing or clips)
- If the bleeding point is not evident, the wound edges as well as the muscle is covered with moist surgical swabs and the deeper parts of the operative field are flushed with saline
- In semi-sitting position the head should be lowered
- Bony edges are carefully waxed, it is often a venous bone channel which is the cause of air embolism
- PEEP is added if air embolism continues and the site is not found
- $p\text{O}_2$  is carefully followed, decrease in  $p\text{O}_2$  indicates serious air embolism
- The neurosurgeon must act swiftly and systematically until the situation resolves
- Once the situation is again under control, we proceed with the surgery, we do not abort the procedure

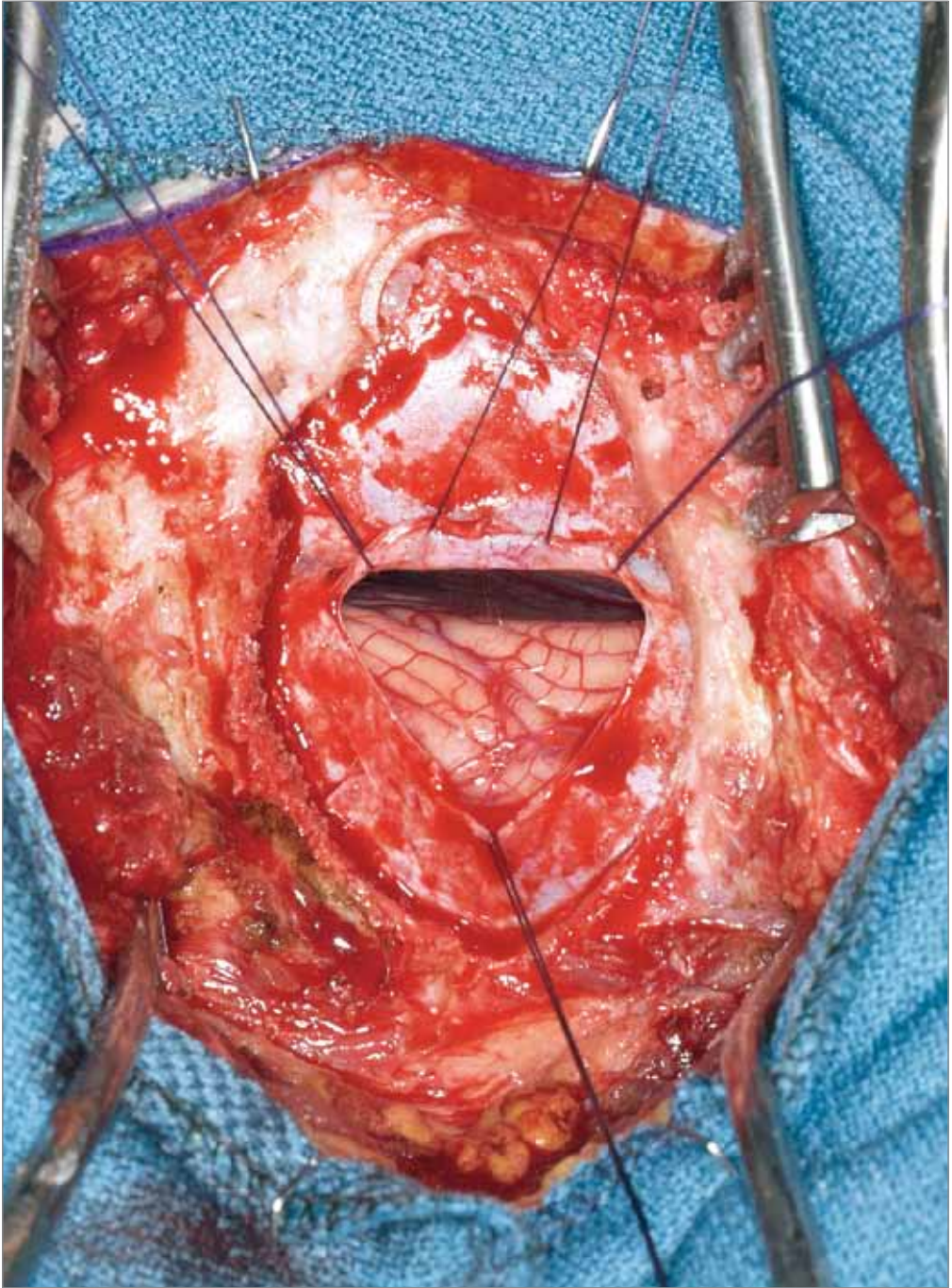


Figure 5-7 (g). Supracerebellar infratentorial approach. See text for details.

dorsal mesencephalic cisterns along the approach and removal of CSF improves the surgical view and provides more space for further dissection. Tilting the table forward provides better visualization of the tentorium.

The arachnoid structures can be thick and opaque complicating identification of anatomical structures. At this point, distinguishing the deeply located veins from the dark blue-colored cisterns is crucial. Exposure of the precentral cerebellar vein, and coagulation and cutting of this vein if needed, clears the view so that the vein of Galen and the anatomy beneath it can be identified. This is the most important part of the operation, and sometimes the thick adhesions associated with chronic irritation of the arachnoid caused by the tumor makes this dissection step very tedious. Generally, we start the dissection laterally. Once we find branches of the posterior choroidal artery and the precentral cerebellar vein the orientation towards other anatomic structures becomes easier. Special care is needed not to damage the posterior choroidal arteries during further dissection. The use of high magnification is crucial as well as the proper length of instruments.

*T&T:*

- *Neurosurgeon fixes the head clamp and is in charge of the positioning all the way*
- *The position should allow the neurosurgeon to rest his or her arms on the patient's shoulders*
- *Exact head positioning according to the 3D location of the lesion*
- *Usually one burr hole is enough*
- *All the bleeding must be stopped even more carefully than in other positions*
- *Utmost care is needed close to venous sinuses due to high risk of air embolism*
- *Dura is better opened under the microscope*
- *Bridging veins should be left intact as much as possible*
- *Close to pineal region the dissection should start laterally*
- *Longer instruments might be necessary*
- *Perfect hemostasis throughout the procedure, no oozing is allowed*

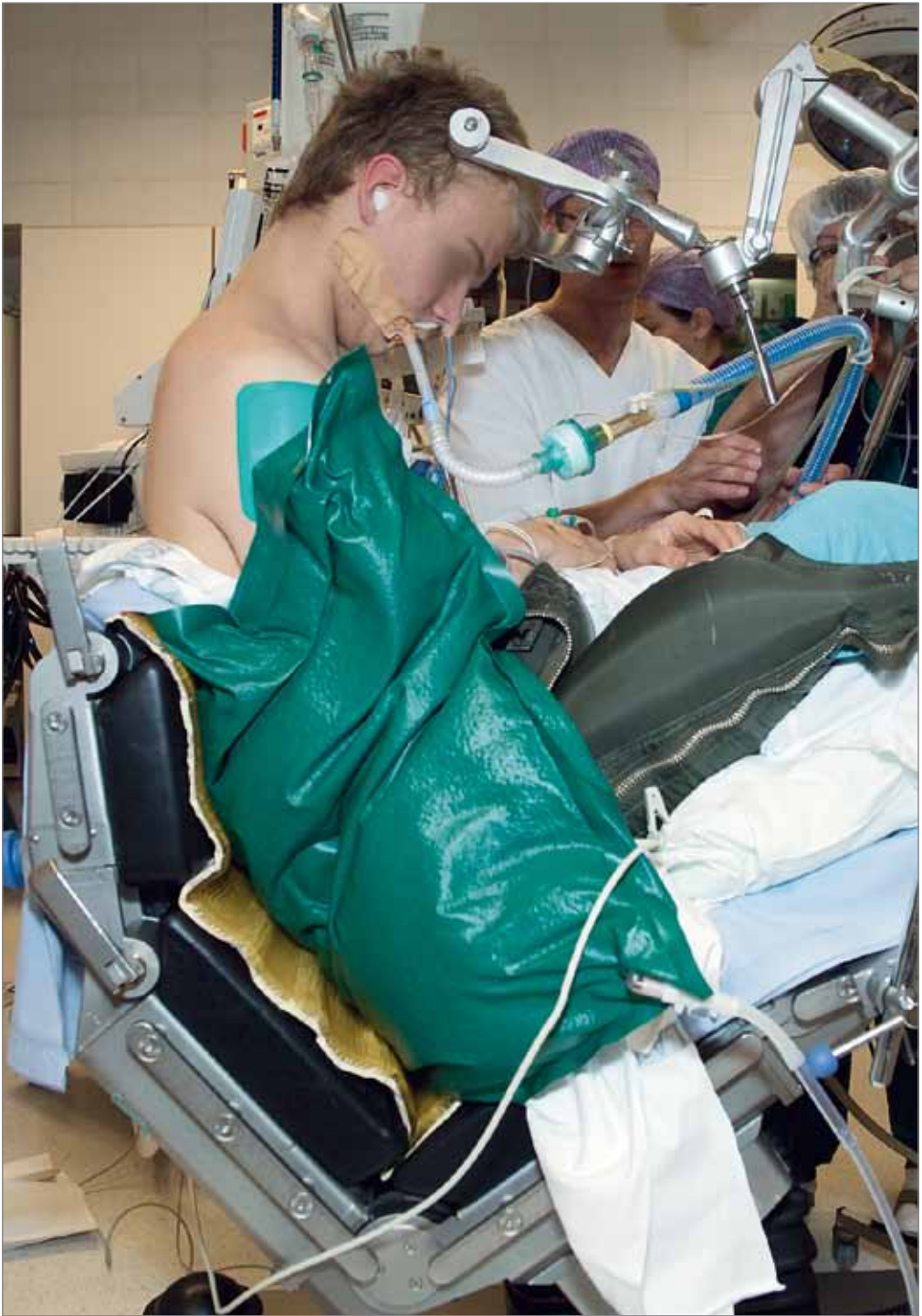

Figure 5-8 (a). Midline approach to fourth ventricle. See text for details.

## 5.9. SITTING POSITION – APPROACH TO THE FOURTH VENTRICLE AND FORAMEN MAGNUM REGION

The other most common use for sitting position in Helsinki is to approach the posterior fossa lesions in the midline, usually located at the level of vermis, fourth ventricle and down to the foramen magnum. All the same rules for sitting position and risks apply as for the supracerebellar infratentorial approach (see section 5.8.). The anesthesiologic principles of the sitting position were reviewed in section 3.7.3. Compared to the supracerebellar infratentorial approach the greatest differences are: (a) no rotation of the head; (b) incision is exactly on the midline; (c) the incision starts lower and extends more caudally; (d) the transverse sinuses are not exposed, the craniotomy is placed below their level; and (e) the craniotomy extends to both sides of the midline.

### 5.9.1. Indications

This approach provides excellent visualization of all the midline structures of the posterior fossa. It allows access to the posterior aspect of the medulla oblongata and the brainstem through the fourth ventricle. With this approach it is possible to enter into the fourth ventricle from the caudal direction in between the cerebellar tonsils without dividing the vermis, and with sufficient forward tilt of the operating table, even the aqueduct can be visualized. Also, both distal PICAs can be accessed. We usually use this low posterior fossa midline approach to access midline tumors of the fourth ventricle, vermis and the cisterna magna region, such as medulloblastomas, pilocytic astrocytomas, ependymomas, or vascular lesions such as midline cavernomas of the fourth ventricle and posterior brainstem and distal PICA aneurysms. For lateral lesions in the posterior fossa we prefer the lateral park bench position. The advan-

tages of the sitting position compared to prone position are mainly related to a more advantageous viewing angle into the fourth ventricle, as the approach is oriented from a more caudal direction, and the possibility of adjusting the view by rotating the table forward even further. To obtain the same kind of approach angle in prone position requires placing the head well below the heart level, which worsens the venous outflow and increases bleeding.

### 5.9.2. Positioning

The positioning is almost identical to that of the supracerebellar infratentorial approach (see section 5.8.2.) (Figure 5-8a). As with the supracerebellar infratentorial approach, our sitting position is more like a forward somersault position with the head bent downwards. The only difference for the low midline approach is that the head is not rotated. The neck is only flexed forward leaving at least two fingers between the chin and the sternum. Again, there is no lateral tilt. All the steps of positioning are carried out in the same way as already described above (see section 5.8.2.).

### 5.9.3. Skin incision and craniotomy

The skin incision is placed exactly on the midline (Figure 5-8b). It starts just below the level of the external occipital protuberance and extends caudally all the way down to the C1–C2 level. Unless the incision is extended caudally enough, it will not be possible later to insert the craniotome in an appropriate angle to reach all the way down to the foramen magnum. It is important to remember that the posterior fossa drops steeply towards the foramen magnum,

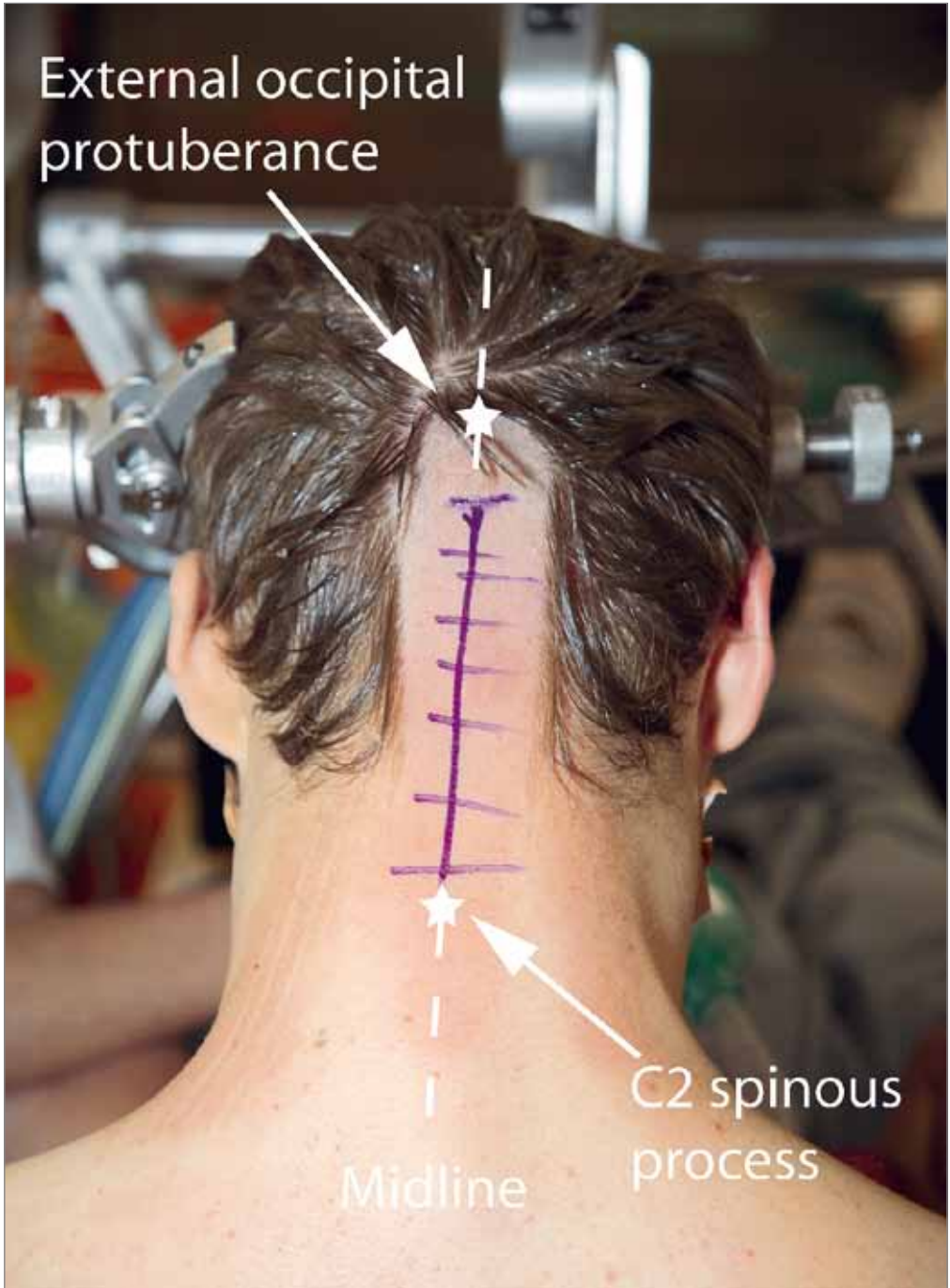


Figure 5-8 (b). Midline approach to fourth ventricle. See text for details.



which is almost horizontal. The muscles are split with diathermia all the way to the occipital bone (Figure 5-8c). One large curved retractor is placed from cranial and the other from caudal direction. The muscle insertions are cut and the occipital bone is exposed. Finger palpation is used to identify the level of the foramen magnum as well as the spinous process of the C1, which is partially exposed with blunt dissection using cottonoid balls. When releasing the muscles and exposing the bone close to the foramen magnum, care is needed not to accidentally cut into the vertebral artery. Up to 1–2 cm from the midline is safe. The other problem may be the large venous epidural sinuses at the foramen magnum. If the posterior atlanto-occipital ligament is cut accidentally, these veins may start to bleed heavily.

At this point the occipital bone should be exposed all the way down to the foramen magnum. One burr hole is placed about 1 cm paramedian to the midline, well below the level of the transverse sinus (Figure 5-8d). In older patients with densely attached dura another burr hole can be placed on the opposite side of the midline. The dura is carefully detached from the underlying bone first with a curved dissector and then with a flexible dissector. The dura should be released all the way towards the foramen magnum. A critical region to release the dura from is next to the burr hole towards and over the midline overlying the occipital sinus and the falx cerebelli. Two cuts are made with the craniotome (Figure 5-8e). The first one curving slightly lateral and down to the foramen magnum. The other cut starts first over the midline to the opposite side and then curves laterally and caudally to the foramen magnum. These two cuts are not joined and 10–20 mm of bone is left between them at the foramen magnum. The bone flap, held from its cranial edge with a large rongeur, is everted

downwards and cracked. The bone is thicker around the foramen magnum and it might be necessary to thin it further down along the craniotome cut before the bone flap can be lifted (Figure 5-8e). There are also dense attachments to the atlanto-occipital ligament, which often need to be cut with scissors. Damage to the epidural venous plexus is most likely to happen during this step, so extra caution is needed. With the bone removed we should be able to distinguish medial aspects of both cerebellar tonsils as well as the medulla oblongata, and the occipital sinus all covered with dura.

A high-speed diamond drill or a small rongeur is used if needed to remove bone in the lateral direction on both sides to expose the foramen magnum a little more. Few drill holes are prepared to be used with tack-up sutures during closure. We do not routinely remove the spinous process or the lamina of C1 vertebra. In our experience, the total removal of C1 arch does not provide any additional benefit regarding the exposure of the lower posterior fossa, but carries significant morbidity. It is performed only when truly necessary in lesions that extend well below the level of C1.

The dura is opened under the operating microscope in X-like fashion. The first reversed V-shaped dural leaf is cut from the midline below the occipital sinus, everted caudally and attached tightly to the muscles with a suture to prevent venous bleeding. Then two additional cuts are made in cranio-lateral direction on both sides over the cerebellar tonsils avoiding the occipital sinus in the midline. All the dural leaves are lifted up with sutures placed over the craniotomy dressings. Recently, we have often been satisfied with a single reversed V-shaped dural opening with the base towards the foramen magnum (Figure 5-8f). Arachnoid membrane of the cisterna magna is often still intact

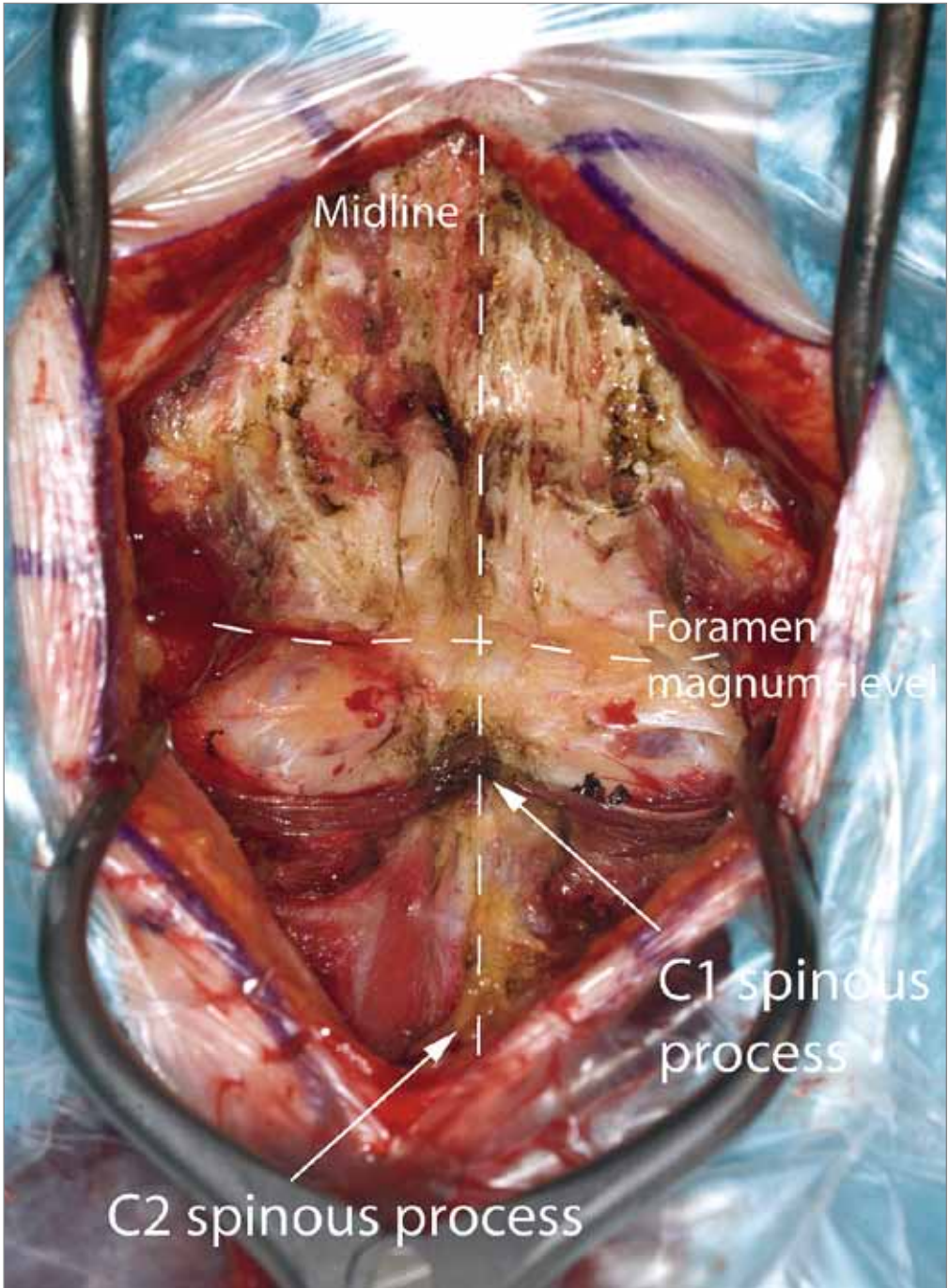


Figure 5-8 (c). Midline approach to fourth ventricle. See text for details.

at this point (Figure 5-8g). With the dura open, also the arachnoid membrane is opened as a flap with the base caudally and it is attached to the caudal dural leaf with a hemoclip(s) (Figure 5-8h). This is to prevent the arachnoid membrane from flapping inside the operation field during the whole procedure. Then, under high magnification of the microscope, the cerebellar tonsils are gently pushed apart and the caudal portion of the fourth ventricle can be entered. By tilting the table forward, good visualization of the upper parts of the fourth ventricle and even the aqueduct can be obtained.

*T&T:*

- *Neurosurgeon fixes the head clamp and is in charge of the positioning all the way*
- *The position should allow the neurosurgeon to rest his or her arms on patient's shoulders*
- *Neck is flexed forward, no rotation or lateral tilt*
- *Usually one burr hole is enough, dura carefully detached*
- *There are large venous plexus at the level of foramen magnum*
- *All the bleeding must be stopped even more carefully than in other positions*
- *Dura is better opened under the microscope*
- *Perfect hemostasis throughout the procedure, no oozing is allowed*
- *Tilting the table forward allows visualization of the cranial portion of the IV ventricle*

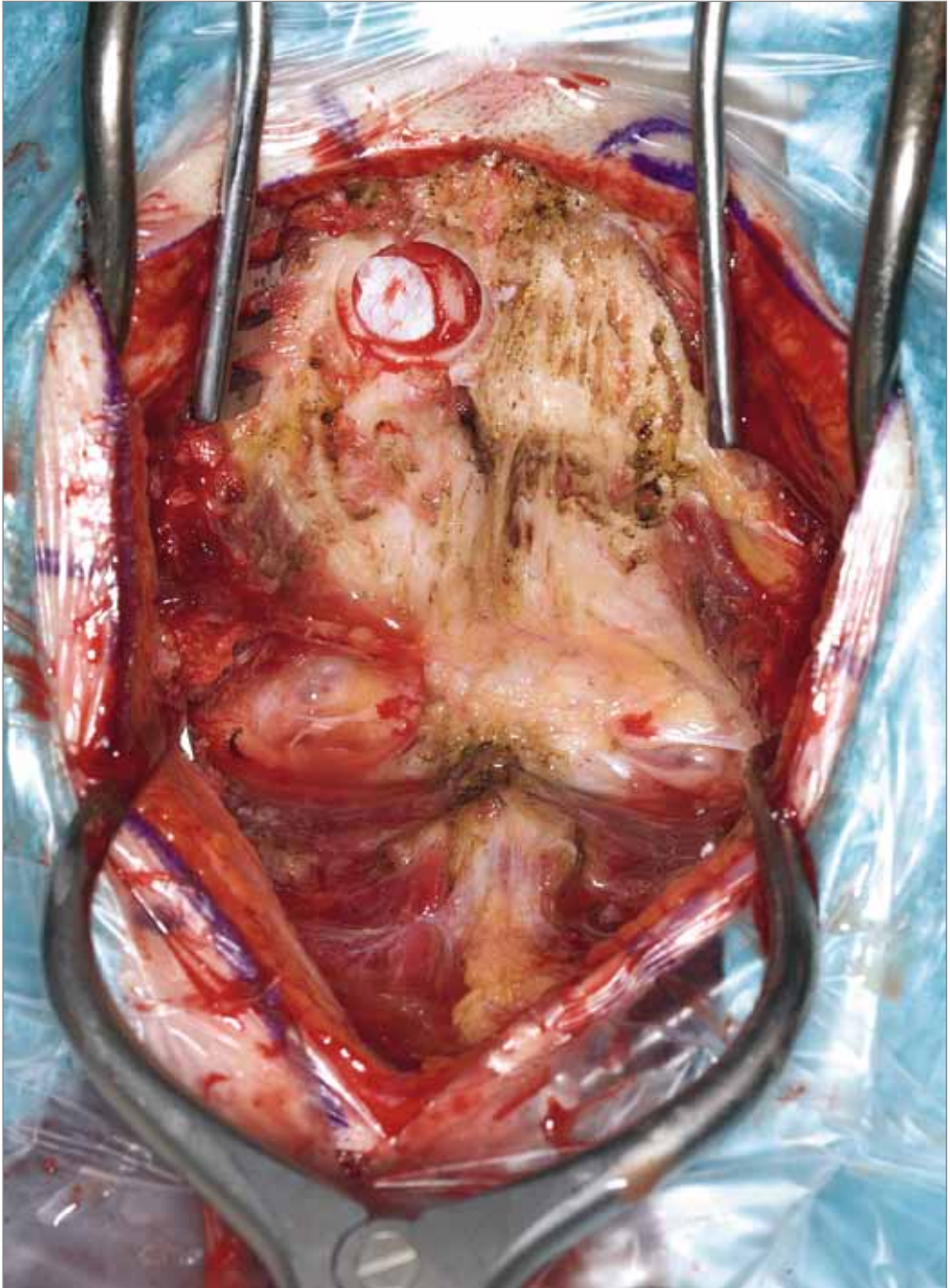


Figure 5-8 (d). Midline approach to fourth ventricle. See text for details.

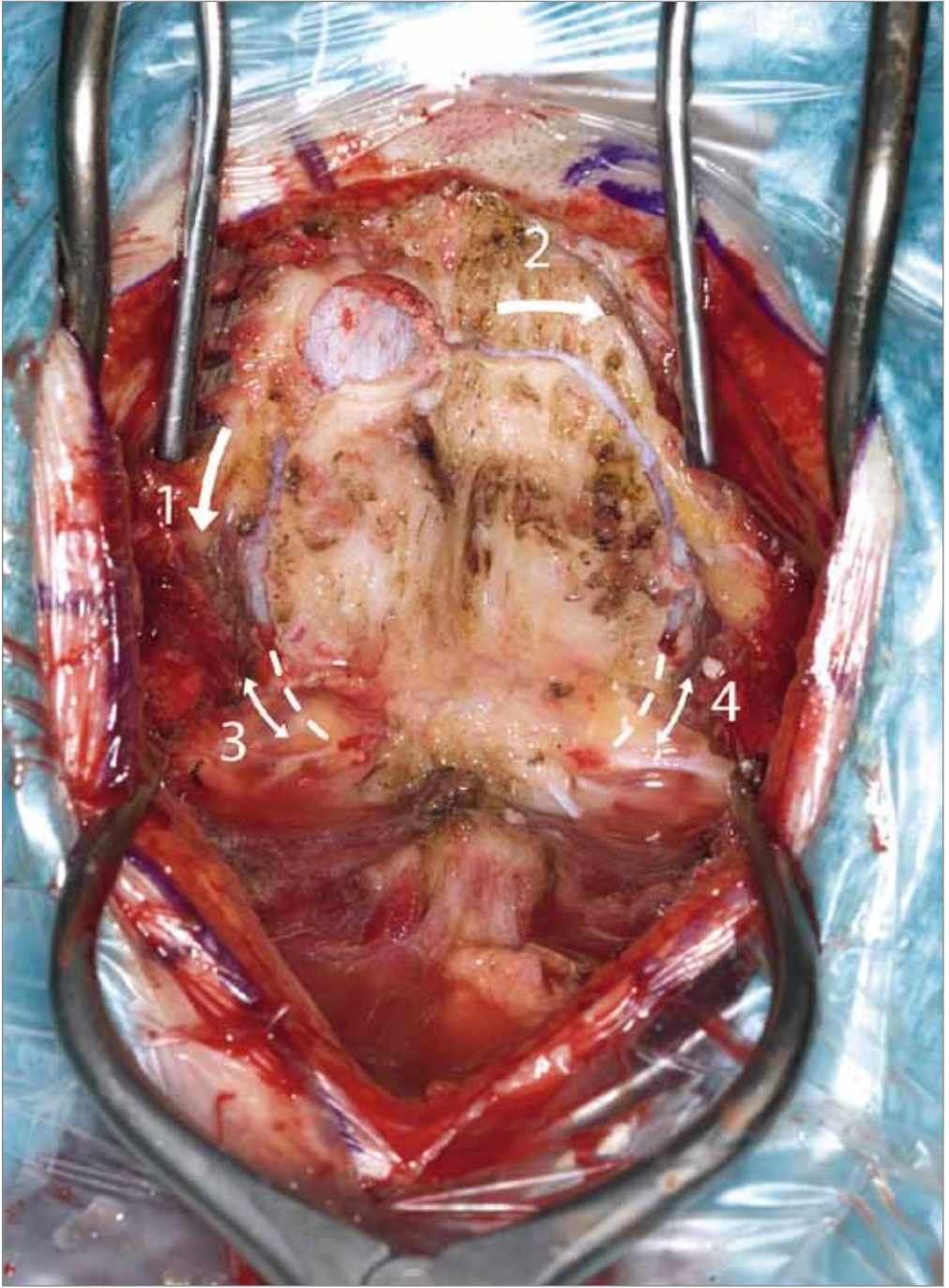


Figure 5-8 (e). Midline approach to fourth ventricle. See text for details.

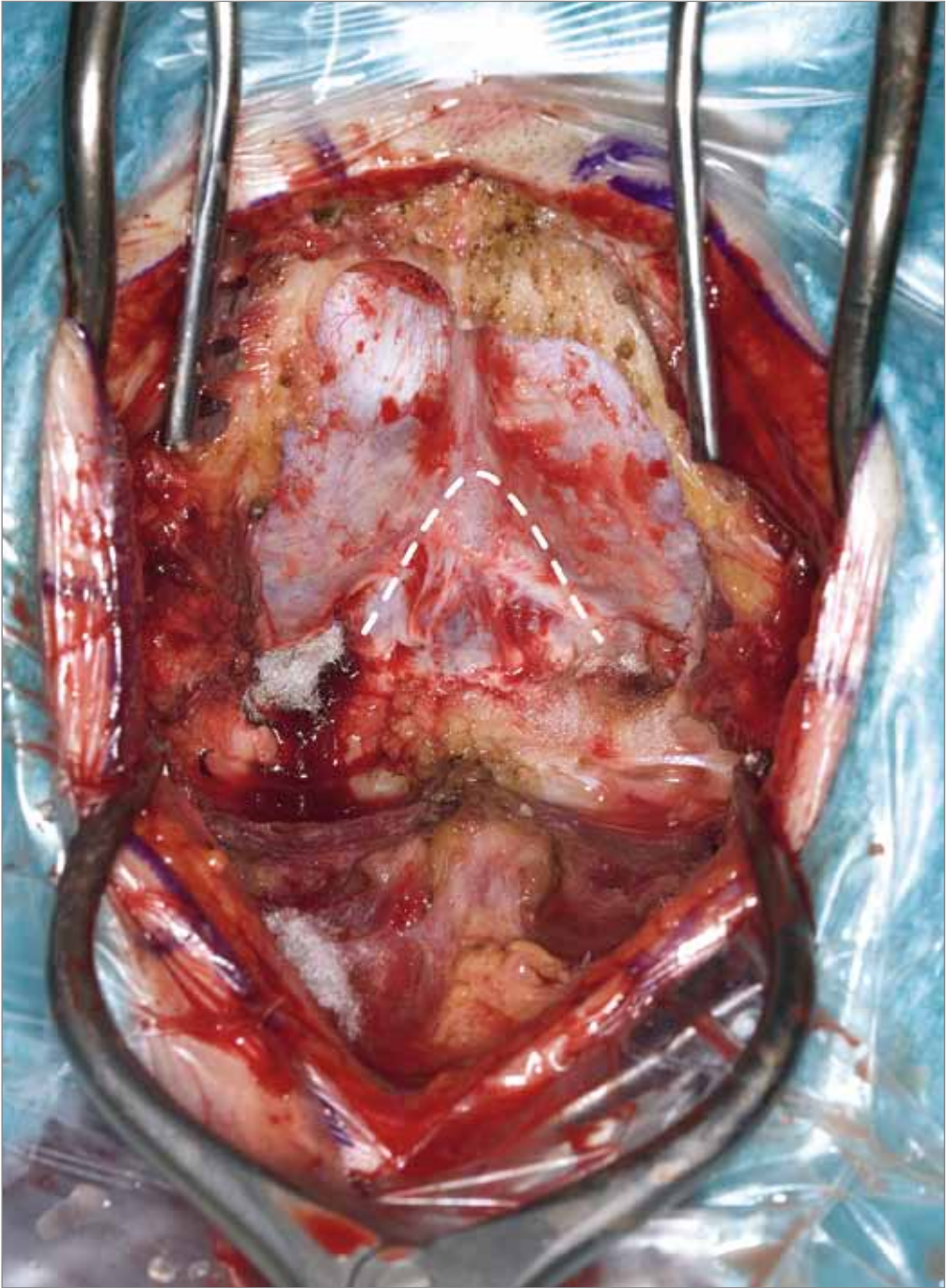


Figure 5-8 (f). Midline approach to fourth ventricle. See text for details.

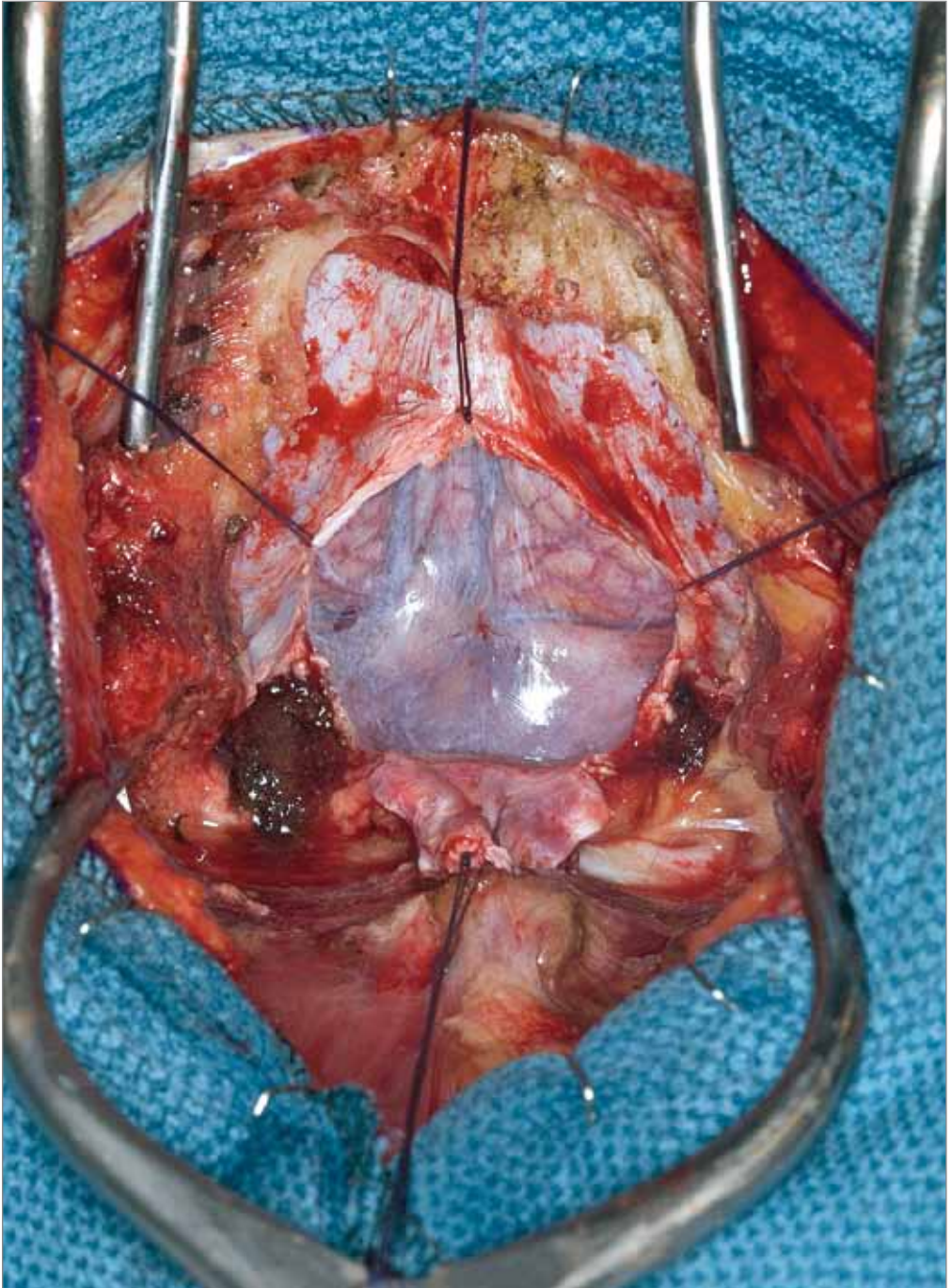


Figure 5-8 (g). Midline approach to fourth ventricle. See text for details.

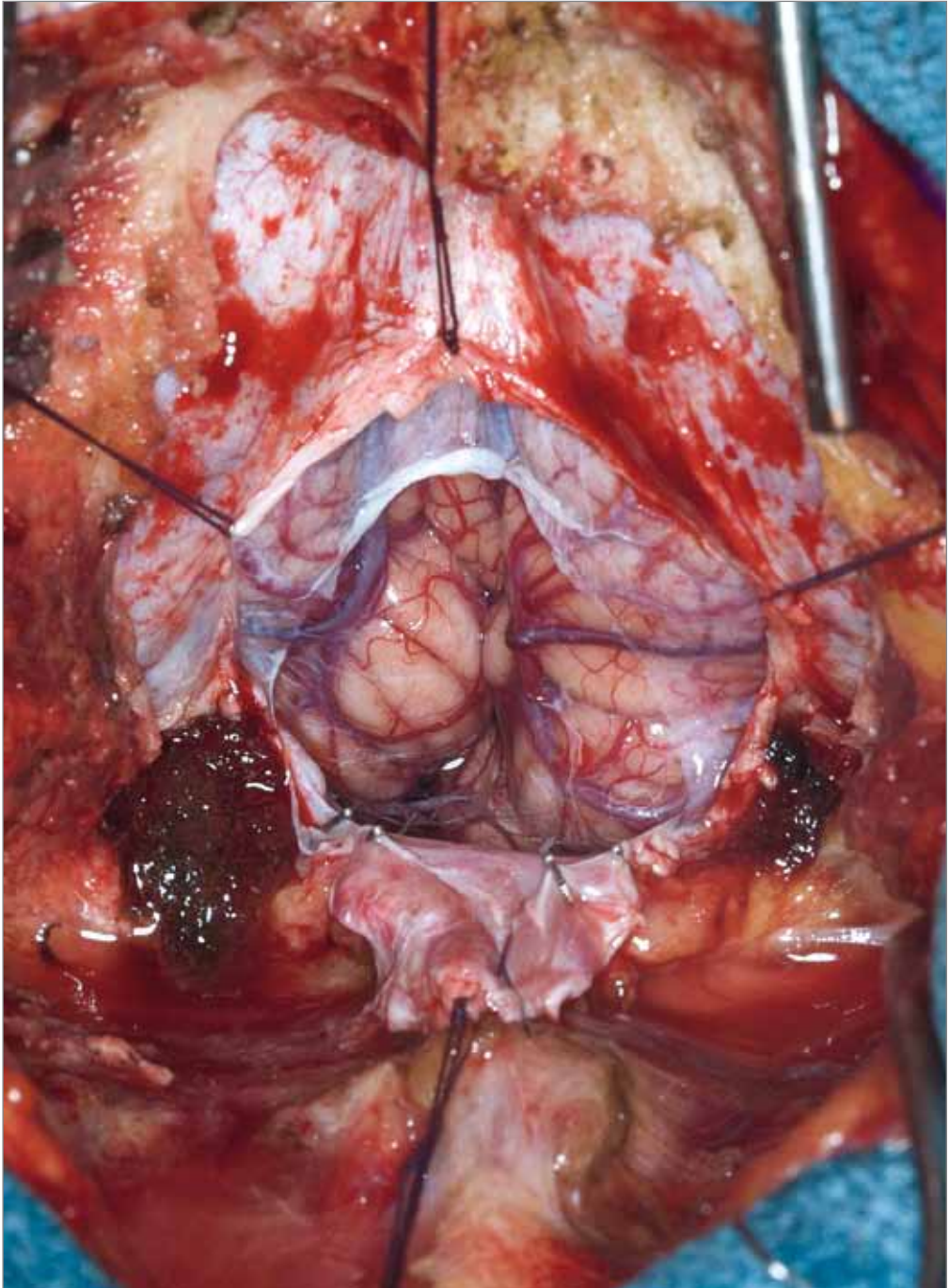



Figure 5-8 (h). Midline approach to fourth ventricle. See text for details.







## 6. SPECIFIC TECHNIQUES AND STRATEGIES FOR DIFFERENT PATHOLOGIES

This chapter introduces general strategies and microneurosurgical techniques that are used in Helsinki. We focus on some of the most common lesions encountered in our practice. We will not go through indications for surgical treatment, instead, we want to present a collection of tricks and techniques that we find useful in the actual execution of these surgical procedures.

### 6.1. ANEURYSMS

For an unknown reason the rupture rate of intracranial aneurysms is almost twice as high in Finland as in other Western populations. In Helsinki we have treated about 8,000 intracranial aneurysms during the microsurgical era starting mid-70's. Nowadays, we annually operate more than 300 patients with intracranial aneurysms, more than half of them with ruptured ones. Over the last 20 years the catchment area of our department has remained very similar, about 2 million people. During this time the number of ruptured aneurysms has remained rather stable, but the number of unruptured aneurysms is steadily increasing. The easy availability of different noninvasive imaging modalities has multiplied the number of incidentally found aneurysms, and also the policy for preventive treatment of these lesions has become much more active over the years.

#### 6.1.1. Approaches for different aneurysms

Nearly all anterior circulation aneurysms are operated using the LSO approach (Figure 6-1). The only exceptions are distal anterior cerebral artery (DACA) aneurysms and distal MCA aneurysms. The DACA aneurysms are approached through a paramedian interhemispheric ap-

proach whereas the distal MCA aneurysms either through a frontotemporal craniotomy in supine or lateral park bench position. In both cases the neuronavigator may be helpful in planning the approach trajectory.

For posterior circulation aneurysms we utilize several different approaches depending on the aneurysm location. The basilar bifurcation aneurysms and those at the origin of the superior cerebellar artery (SCA) are most often approached using the subtemporal approach. In case the basilar bifurcation is located much higher than the posterior clinoid process and the clivus ( $\geq 10$  mm) we use the LSO and the trans-Sylvian route. If on the other hand the basilar bifurcation is much lower than the posterior clinoid process, then the presigmoid approach is needed. Even if one could reach the actual aneurysm with the subtemporal approach, especially after cutting the tentorium, the true problem in basilar bifurcation aneurysms is proximal control. To get good proximal control one often needs to make much more extra work, but it is generally time well spent. Especially in ruptured aneurysms, the risk of aneurysm re-rupture during clipping is very high and should be prevented by all possible means. The basilar trunk and the vertebrobasilar junction aneurysms at the middle third of the clivus, are the most difficult to approach. The presigmoid approach is often the only option and the clipping of the aneurysms is further hampered by the perforators arising from the basilar trunk towards the brain stem. Aneurysms of the vertebrobasilar junction situated at the lower third of the clivus, aneurysms at the origin of the PICA or proximal PICA aneurysms are best reached with a small retrosigmoid approach as long as they are at least 10 mm above the level of foramen magnum. Those closer to the foramen magnum require the lat

eral approach with more bone removal. Finally, distal PICA aneurysms are operated through either the lateral approach or the posterior low midline approach depending on the exact location of the aneurysm.

### 6.1.2. General strategy for ruptured aneurysms

Our general strategy for surgery of ruptured aneurysms is very similar irrespective of the aneurysm location or size. Giant, partially thrombosed, calcified and fusiform aneurysms are special subgroups, which often need a customized strategy with options for bypass procedures, endovascular balloon occlusions and

intraoperative DSA angiography. Fortunately, these cases represent only about 5% of all the aneurysms we see. In the majority of cases we can follow a relatively standardized strategy.

The selection of microsurgical approach is based on the aneurysm location as described above (section 6.1.1.). The actual surgical strategy for aneurysms includes the following steps: (a) craniotomy; (b) brain relaxation by release of CSF and possible partial removal of space occupying ICH; (c) establishing proximal and distal control of the parent arteries; (d) aneurysm neck dissection under temporary clipping of the arteries; (e) insertion of the pilot clip; (f) further dissection of the aneurysm dome from

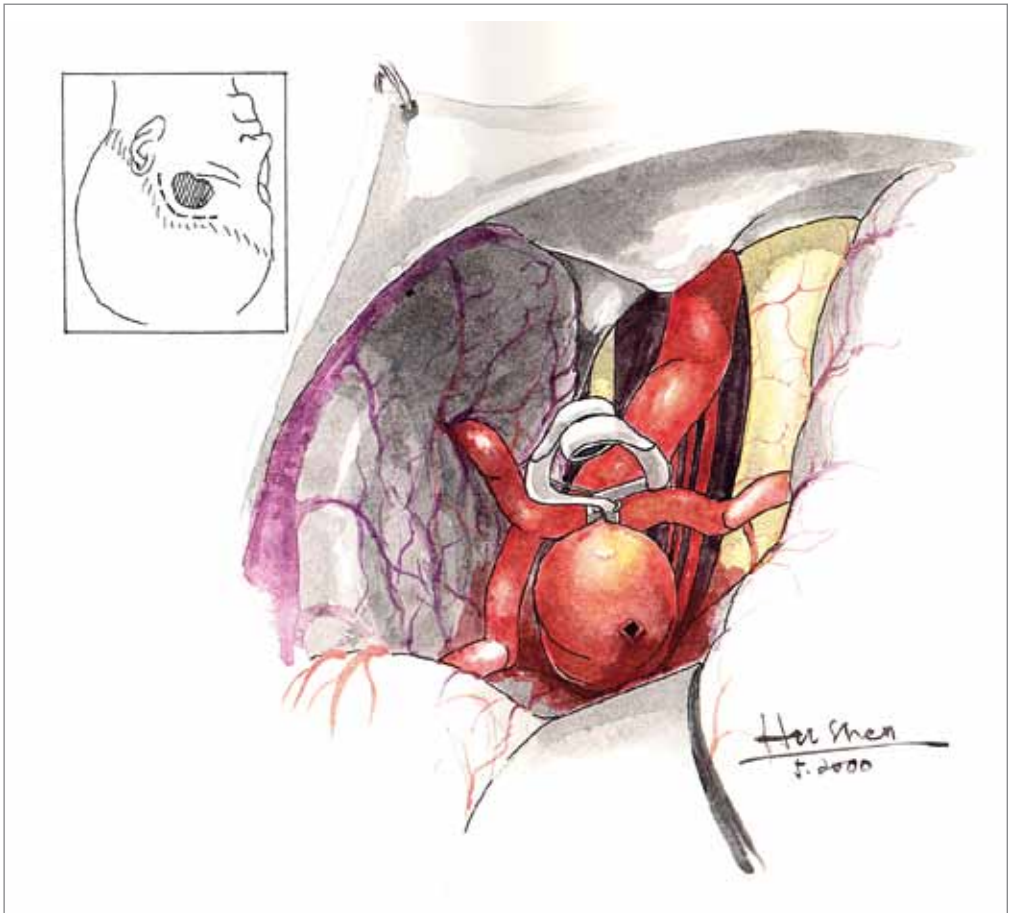


Figure 6-1. Ruptured ICA bifurcation aneurysm clipped through left LSO approach.

the surrounding structures and possible remodeling of the dome; (g) final clipping and checking of the patency of the surrounding arteries; (h) removal of the remaining ICH if present; (i) application of Surgicel with papaverine locally to prevent vasospasm; and (j) wound closure. This whole strategy does not differ much from our strategy for unruptured aneurysms. The greatest differences are the more oedematous brain and the constant fear of aneurysm re-rupture. Thus, in ruptured aneurysms more time is initially spent on obtaining a slack brain and more CSF needs to be released. One needs to open several cisterns to remove sufficient amount of CSF; for anterior circulation aneurysms fenestration of the lamina terminalis and subsequent removal of CSF directly from the third ventricle is usually the action of choice. Once the actual dissection towards the aneurysm starts, proximal control needs to be established as soon as possible, and the actual aneurysm is better left alone before the proximal artery has been identified. The blood in the subarachnoid space obstructs vision, makes identification of structures more demanding, and the actual brain tissue is more prone to oozing. Manipulation of the vascular structures near the aneurysm dome should be performed only after proper proximal control has been established. It is often wiser to leave some blood clot behind than to chase after every small clot piece, which would risk possible damage to the surrounding perforators.

When operating on a ruptured aneurysm in a patient with multiple aneurysms, we do not perform multiple craniotomies. The ruptured aneurysm is treated first. The additional aneurysms that can be easily accessed through this same approach may be clipped during the same session. If there are difficulties during the clipping for the ruptured aneurysm, the unruptured aneurysms are left alone and treated several months later if appropriate. We usually do not use contralateral approaches when operating on an acute SAH patient.

### 6.1.3. General strategy for unruptured aneurysms

Unruptured aneurysms, in general, are easier to approach than their ruptured counterparts (Figure 6-2). Again the complex, giant, partially thrombosed, calcified or fusiform aneurysms are exceptions. The basic steps in aneurysm surgery for unruptured aneurysms are the same as for the ruptured ones (see above). With good neuroanesthesia, the lack of space is not a problem and even the aneurysm can be approached more freely. In unruptured aneurysms it is usually sufficient to release CSF from the actual cistern where the aneurysm is located, i.e. opening of the lamina terminalis is seldom required. All the anatomical structures can be better identified and the dissection plane is easier to maintain. Smaller opening of the arachnoid is often sufficient and less of the surrounding structures need to be exposed. Intraoperative rupture can happen even in unruptured aneurysms, but this is often caused by direct manipulation of the aneurysm dome, its tight attachment to the surrounding brain, or a calcified aneurysm wall. We prefer to use temporary clips even in unruptured aneurysms as they soften the aneurysm dome and facilitate safer dissection and clipping of the neck. In case of multiple aneurysms, we try to clip all the aneurysms, which are accessible through the same craniotomy during the same session. Contralateral approaches can be used.

### 6.1.4. Release of CSF and removal of ICH

Release of CSF is the first and foremost step in obtaining a relaxed brain and sufficient room for further dissection. The whole approach strategy has to be planned so that CSF can be released gradually during the different steps of the approach.

For the LSO approach, opening of the optic and carotid cisterns is the first step. If further CSF needs to be removed to relax the brain properly, the next choice would be to fenestrate the lamina terminalis, unless there is a downward projecting ACoA aneurysm. In cases where the lamina terminalis cannot be approached, the Liljequist's membrane can be opened in between the optic nerve and the ICA, and the interpeduncular cistern entered for more CSF to be released.

During the interhemispheric approach, CSF is first released from the interhemispheric fissure and the pericallosal cistern. This cistern is relatively shallow and only a limited amount of CSF can be released. If the brain remains tight, there are two options: (a) to make a ventricular puncture using a ventriculostomy catheter at the lateral edge of the craniotomy, or (b) dislocate the ipsilateral pericallosal artery laterally 5–10 mm and puncture the corpus callosum with bipolar forceps to enter into the lateral ventricle ("Balkenstich").

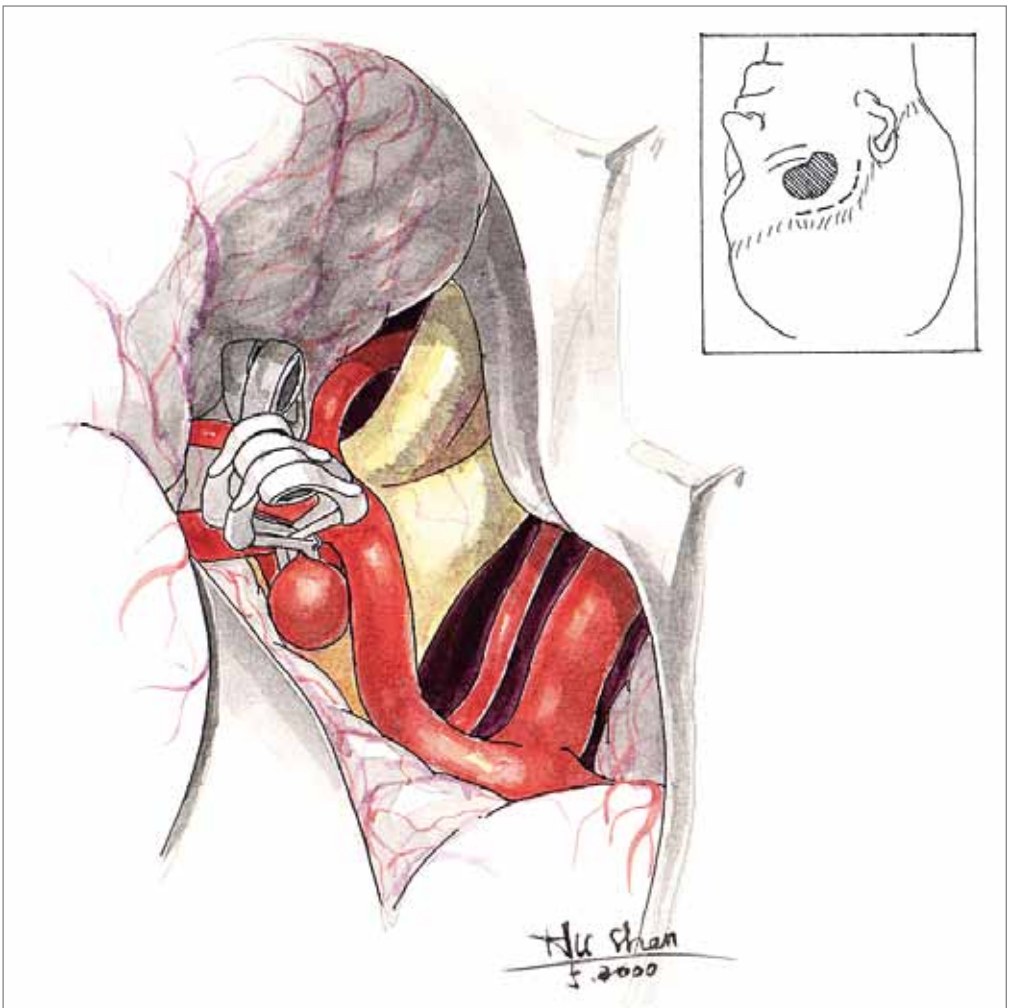


Figure 6-2. Unruptured ACoA aneurysm clipped through right LSO approach.

In the subtemporal approach the initial release of CSF has to be obtained via a lumbar drain, with 50–100 ml removed. Intraoperatively, additional CSF is removed along the floor of the middle fossa, but especially at the tentorial edge from the interpeduncular cistern.

In the retrosigmoid approach the lumbar drain is also implemented, but later additional CSF is removed either from the cisterna magna by tilting the microscope caudally, or from the cerebello-pontine cistern.

The presigmoid approach and the lateral approach to foramen magnum both require lumbar drain and additional CSF release from the cerebellopontine cistern. The prepontine cistern, and the cisterna magna can be also approached.

In case of large ICH and lack of space, a small cortical incision is made accordingly to the location of the hematoma. We try to avoid eloquent areas such as the Broca's area. Some of the ICH is removed via this cortical incision to gain more space but care is taken not to cause inadvertent aneurysm rupture as this would be difficult to control through the ICH cavity. While removing the ICH clot, before or after clipping, only minor force should be applied so as not to sever the perforating arteries. Irrigation with saline helps in releasing the blood clots from the surrounding structures. The remaining major part of the ICH is removed only after the ruptured aneurysm has been secured.

Ruptured MCA bifurcation aneurysms cause most frequently such an ICH that emergency removal is required. In our series, as many as 44% of the ruptured MCA bifurcation aneurysms had bled into the adjacent brain tissue. In our practice, patients with massive ICHs are transferred directly to the operating room from emergency CT/CTA for immediate ICH removal and clipping of the aneurysm(s). Early surgical removal of massive ICH is believed to improve the outcome of ruptured MCA aneurysms. The propensity for ICH may explain the higher than

average management morbidity and mortality in patients with ruptured MCA bifurcation aneurysms compared to other anterior circulation aneurysms.

#### 6.1.5. Dissection towards the aneurysm

With the brain relaxed, we proceed with dissection towards the aneurysm. In nearly all unruptured aneurysms the distal artery is followed in the proximal direction until the aneurysm is identified. For most ruptured aneurysms we utilize this same strategy, but with more emphasis on locating and controlling the proximal parent artery as soon as possible. The dissection starts with identification of certain standard structures such as the cranial nerves or bony structures. From these the arteries are derived. In parallel running arteries such as the pericallosal arteries or M2 and M3 segments of the MCA, careful study of the preoperative images for the branching patterns helps in distinguishing which artery is which. Each aneurysm location has certain specific tricks, which need to be taken into consideration. For these we kindly refer to our numerous publications on microneurosurgery of aneurysms at specific locations.

In general, one should orient the dissection along the arterial surface utilizing the natural dissection planes provided by the cisterns in which the arteries run. The aim is to locate the actual aneurysm, but more importantly the proximal parent artery. All the initial steps of the dissection are oriented towards the goal of obtaining proximal control. Only after proximal control has been established, the dissection can proceed further with mobilization of the aneurysm dome. Depending on the aneurysm location, perforators may be found in close vicinity to the aneurysm, or sometimes even attached to the dome. Preserving the perforators is usually the most tedious part of the operation and may require a lot of high precision work, including multiple trials for optimal clip

position. We use high magnification during the whole dissection along the vessels to prevent accidental damage to all the small arterial and venous structures. Small venous bleedings can be tamponated with Surgicel and cottonoids, but even the tiniest arterial bleedings should be identified under very high magnification and coagulated with sharp bipolar forceps.

#### 6.1.6. Opening of the Sylvian fissure

The Sylvian fissure needs to be opened for all MCA aneurysms, as well as some ICA aneurysms, namely those originating at the ICA bifurcation and some of the aneurysms located at the origin of the anterior choroid artery or the posterior communicating artery. We do not open the entire Sylvian fissure, only the portion which is necessary for the approach, in most cases the proximal part for the length of 10–15 mm. Factors which would require a more extensive and distal opening of the Sylvian fissure for better proximal control of the M1 or even the ICA bifurcation are: (a) ruptured aneurysm, (b) secondary pouch in the aneurysm dome, (c) intertruncal or lateral projection of the dome, and (d) involvement of branches or the MCA bifurcation in the aneurysm. In giant MCA aneurysms, the Sylvian fissure is opened widely, both from the carotid cistern and distal to the aneurysm. In most MCA aneurysms, our strategy is to enter the Sylvian fissure and to go from distal to proximal towards the aneurysm (Figure 6-3). Only in some ruptured or complex aneurysms, where proximal control might be difficult to obtain through this route, we initially dissect the proximal M1 from the carotid cistern side to have control before entering the Sylvian fissure.

The best place to enter the Sylvian fissure is usually where transparent arachnoid is present. The venous anatomy on the surface of the Sylvian fissure is highly variable. Multiple large veins often follow the course of the Sylvian fissure, draining into the sphenoparietal or cav-

ernous sinuses. These veins are generally running on the temporal side of the Sylvian fissure. In principal, we prefer to open the arachnoid covering the Sylvian fissure on the frontal lobe side. However, in the presence of multiple large veins or anatomic variations the dissection plan should be tailored accordingly. Dissection of the Sylvian fissure is more difficult with a swollen brain in acute SAH or with adhesions from previous SAH or operations. Preservation of the dissection plane is mandatory.

The entire opening of the Sylvian fissure should be performed under very high magnification of the microscope. First, we open a small window in the arachnoid with a pair of jeweler forceps or a sharp needle acting as an arachnoid knife. Then we expand the Sylvian fissure by injecting saline using a handheld syringe, i.e., the water dissection technique of Toth (see section 4.9.10). The idea is to get relatively deep into the Sylvian fissure, and to enter the Sylvian cistern from this small arachnoid opening. There are two arachnoid membranes that need to be opened, a superficial one covering the cortex and a deeper one inside the fissure limiting the Sylvian cistern. Once inside the Sylvian cistern, the dissection proceeds proximally by gently spreading the fissure in an inside-out manner. In our experience, this technique allows easier identification of the proper dissection plane. Bipolar forceps and suction act both as dissection instruments and delicate microretractors. Cottonoids applied at the edges of the dissected space act as soft retractors, and pressure applied gently on the both walls of the fissure will stretch the overlying bridging tissues, facilitating their sharp dissection. All arachnoid attachments and strands are cut with microscissors, which can also act as a dissector when the tips are closed. In order to preserve larger veins, some small bridging veins may have to be coagulated and cut. However, most vascular structures can be found to belong to either side of the Sylvian fissure, and can be mobilized without the need of transection.



Inside the Sylvian cistern, the M3 and M2 segments of the MCA are identified and followed proximally. The M2s should be covered by the intermediate Sylvian membrane, another arachnoid membrane, which in some patients can be rather prominent in others hardly even identifiable. By following the M2s proximally, one should arrive at the MCA bifurcation where the most difficult task is to identify the proximal MCA trunk (M1) for proximal control. In the surgical view the M1 is often hidden by the bifurcation and its course is often along the visual axis of the microscope making its identification quite difficult during the initial dissection. The M2 trunk with a medial course is easily confused with the M1 unless one keeps this in mind. The M1 can be often more easily reached from behind and below the bifurcation than in front and above. A more distal opening of the Sylvian fissure provides better angle to visualize and obtain control of the M1 just beneath the bifurcation. If needed, the dissection

continues proximally along the M1 trunk in the deepest and often the narrowest part of the proximal Sylvian fissure. Care is needed not to sever the lateral lenticulostriate arteries during the different stages of the dissection. Numerous arachnoid trabeculations around the proximal M1 trunk make dissection demanding, and we advocate sharp dissection.

#### 6.1.7. Temporary clipping

Usually, it is not advisable to dissect the dome completely free before applying the so-called 'pilot' clip. Instead, the arteries around and adjacent to the base should be dissected free and the base cleared thoroughly (Figure 6-4). Frequent use of temporary clips allows for a safe and sharp dissection of the aneurysm and the adjacent arteries. The duration of each temporary occlusion should be kept as short as possible (max 5 minutes) (Figure 6-5). In elderly

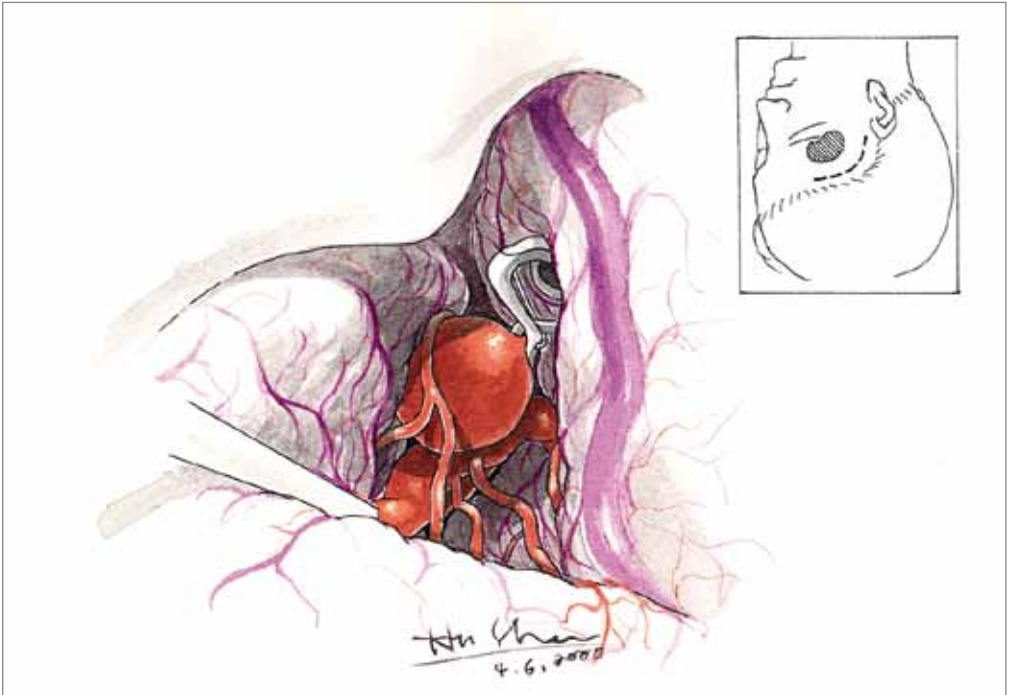


Figure 6-3. MCA bifurcation aneurysm clipped through right LSO approach.

patients and those with very atherosclerotic arteries, temporary clipping should be used more sparingly. Curved temporary clips may be more suitable for proximal control and straight ones for distal control. Dissection and preparation of sites for temporary clips should be performed with bipolar forceps with blunt tips or with a microdissector. The proximal clip can be close to the aneurysm, but the distal ones should be at a distance so as not to interfere with the visualization and permanent clipping of the aneurysm neck. It is practical to gently press the temporary clip down with a small cottonoid to protect it from the dissecting instruments. Temporary clips should be removed

in distal to proximal order. When removing the temporary clips, they are first opened in place to test for unwanted bleeding from the potentially incompletely clipped aneurysm. Removal in rush can be followed by heavy bleeding and great difficulties in placing the clip back. While removing the temporary clips, even the slightest resistance should be noted as possible involvement of a small branch or a perforating artery in the clip or its applier.

We do not use electrophysiologic monitoring during temporary clipping or aneurysm surgery in general. Unlike in tumor surgery, we do not find much benefit provided by the present neu-

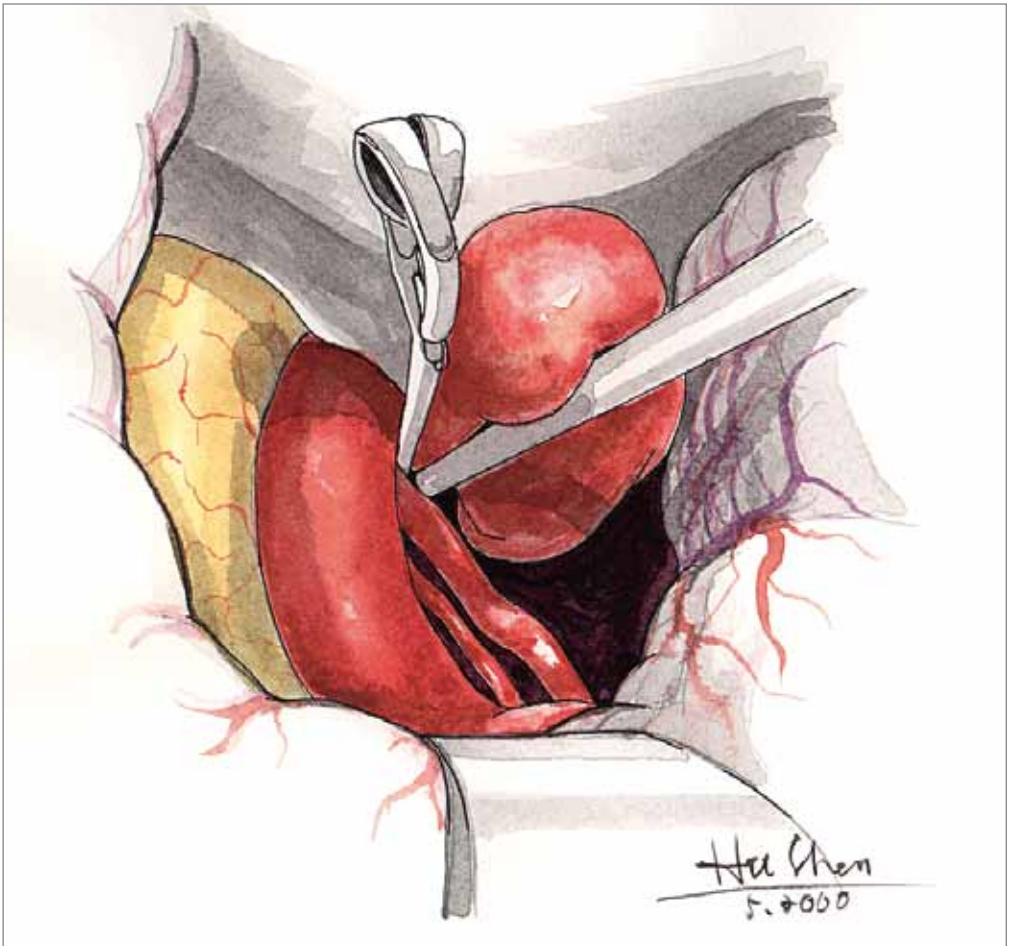


Figure 6-4. With a pilot clip on, the adjacent perforators are dissected free.

rophysiologic monitoring in aneurysm or AVM surgery. The temporary clips are used only when truly required, and they are kept in place out of necessity and for as short time as possible. So even if we had some indication during temporary clipping that certain evoked potentials are dropping, this would not change our action at that moment of time. The aneurysm would still have to be occluded, or the artery repaired, before the temporary clips can be removed.



Figure 6-5. Stop watches are used to time the temporary occlusion, for each clip separately.

### 6.1.8. Final clipping and clip selection

A proper selection of clips with different shapes and lengths of blades, and applicators, suiting the imaged aneurysm anatomy, should be ready for use. The optimal final clip closes the whole base but prevents kinking or occlusion of the adjacent branches (Figure 6-6). Usually the smallest possible clip should be selected. Unless dome re-modeling is used, the blade of a single occluding clip should be 1.5 times the width of the base as suggested by Drake. Frequent short-term application of temporary clips during the placement and replacement of aneurysm clips is routine in our practice. We prefer inserting first a pilot clip over the aneurysm dome, often preferring Sugita clips for their wide opening and blunt tips. The pilot clip is later exchanged for a smaller and lighter final clip. As the clip is slowly closed, the surrounding arteries and perforators are inspected for kinking, twisting and compromised flow. Adequate dissection, proper sizes of clips and careful checking that the clip blades are well placed up to their tips are required to preserve the adjacent branches (Figure 6-7). We use multiple clipping, two or more clips, for wide-based, large and often calcified thick-walled aneurysms (Figure 6-8). In these, one should always leave some base to prevent occlusion of the parent artery by the clip. After the clipping, the dome of the aneurysm may be punctured and collapsed (Figure 6-9). It is important to inspect the tips of the clip on both sides to make sure that they have not caught any branches or any of the

perforators. The clip blades should completely close the base of the aneurysm. Because the arteries may become kinked or occluded after removal of the retractors, the flow should be checked once more and papaverin applied. When appropriate, not risking the surrounding branches, we resect the aneurysm dome for the final check of closure and for research purposes (Figure 6-9). This policy teaches one to dissect aneurysm domes more completely and thereby avoid closure of branching arteries. Opening of the aneurysm facilitates effective clipping by reducing intraluminal pressure and should be used in strong-walled, large, and giant aneurysms.

### 6.1.9. Intraoperative rupture

The aneurysm may rupture during any stage of the dissection or clipping. The risk of rupture is highest for the aneurysms attached to the surrounding brain or especially the dura, where extensive manipulation and retraction of the surrounding structures may stretch the dome and cause intraoperative rupture of the aneurysm. This is why excessive retraction should be avoided during dissection. In case of rupture, control should be first attempted via suction and compression of the bleeding site with cottonoids. One should not try to clip the aneurysm in haste directly as this could easily end up in tearing the aneurysm base or even the

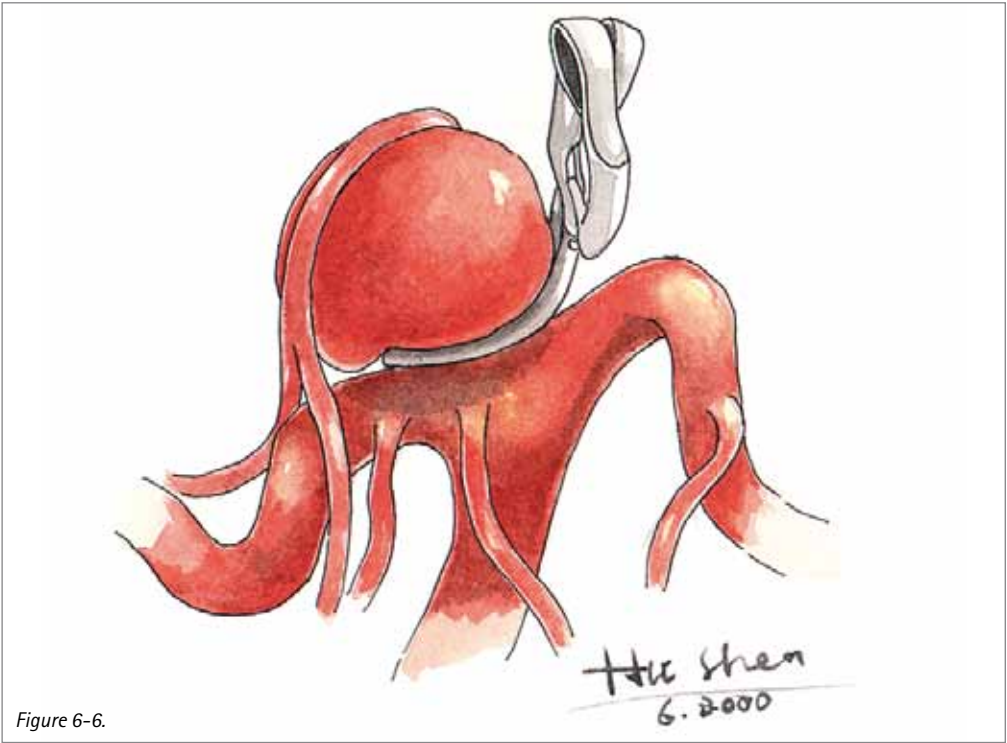


Figure 6-6.

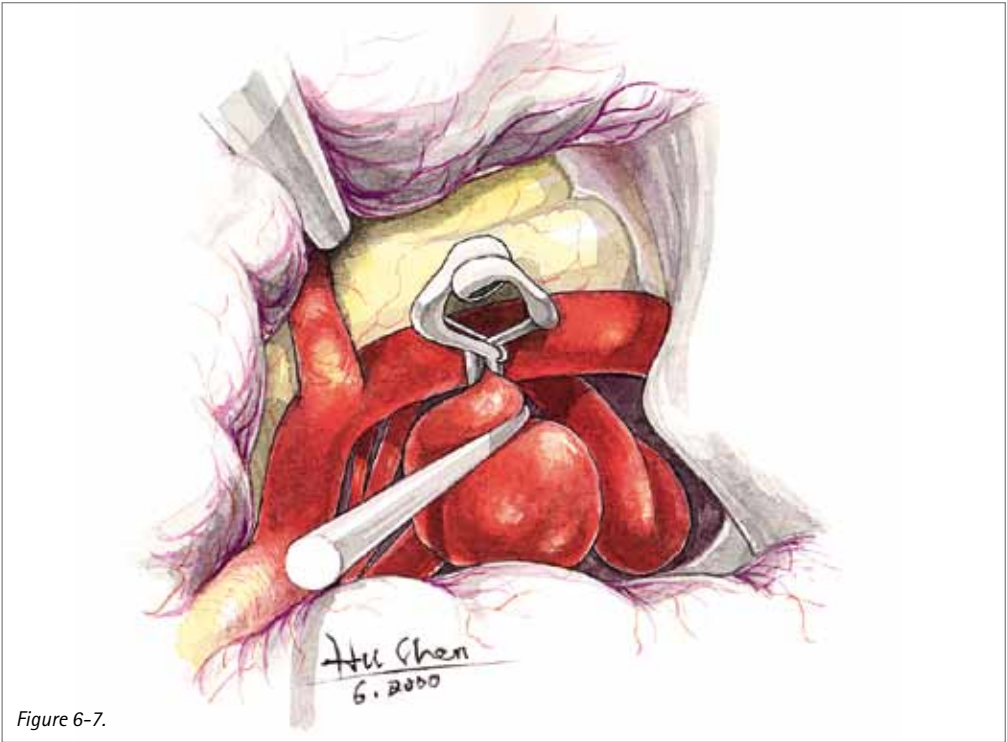

Figure 6-7.

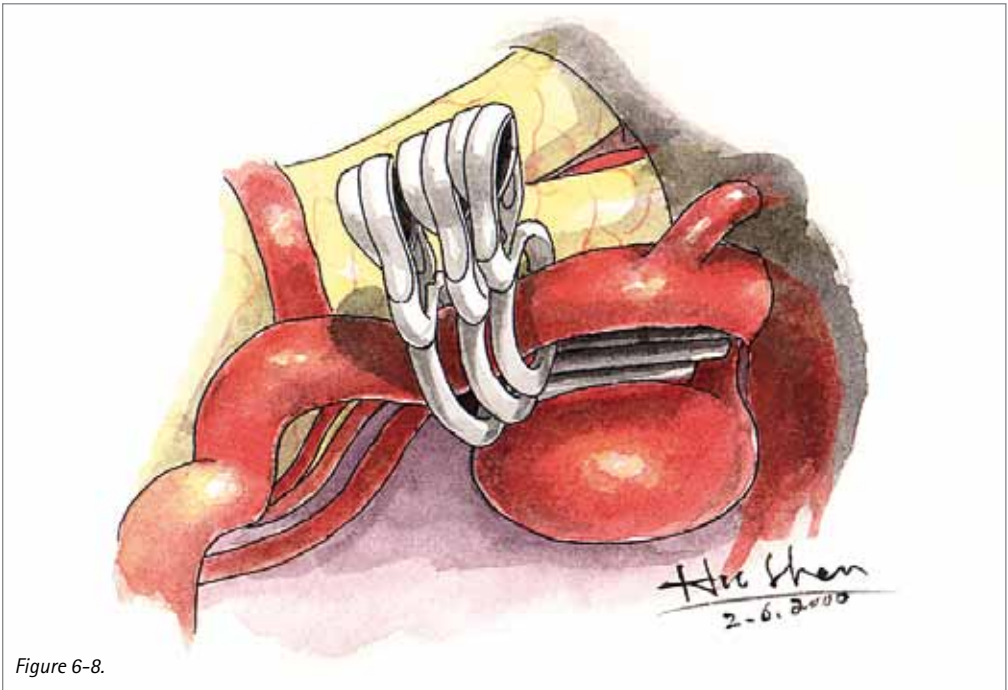


Figure 6-8.

Figure 6-6. Proper size clip prevents kinking or accidental occlusion of perforators.

Figure 6-7. Meticulous checking to make sure that all perforators are outside the clip blades.

Figure 6-8. Multiple clips can be used in thick-walled aneurysms.

Figure 6-9. Collapsing the aneurysm dome enables viewing around the whole aneurysm dome.

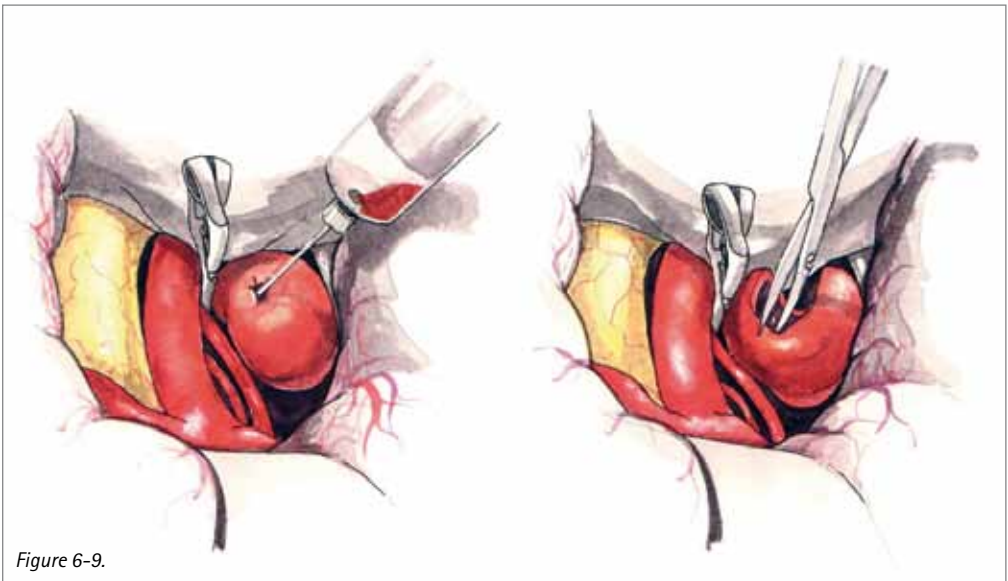


Figure 6-9.

parent artery. Instead, the aneurysm should be isolated with temporary clips applied both proximally and distally. With the bleeding under control, the aneurysm base is dissected free and the pilot clip applied. Short and sudden hypotension by cardiac arrest, induced by intravenous adenosine, can be used to facilitate quick dissection and application of a pilot clip in case of uncontrolled bleeding (see below). A small and thin walled aneurysm may rupture at its neck during dissection. Under temporary clipping of arteries, reconstruction of the base by involving a part of the parent artery in the clip should be attempted. One option, hindered often by the deep location, is to suture the rupture site with 8/0 or 9/0 running sutures or to repair the site using anastoclips, followed by clipping and reinforced with glue.

#### 6.1.10. Adenosine

In recent years we have used intravenous adenosine to achieve a short-lasting cardiac arrest. To induce cardiac arrest, the anesthesiologist injects 20 – 25 mg of adenosine as a rapid bolus into a large vein, preferably into the central venous line, with flush. Injection of adenosine is followed by an approximately 10-second cardiac arrest (see also section 3.9.2). Different patients seem to react differently to the drug and in some patients actual cardiac arrest is not observed. But more important than the cardiac arrest is a short-lasting, significant hypotension, with systolic blood pressure dropping below 50 mmHg. This is observed even in those patients who maintain normal cardiac rhythm throughout the action of the drug. If the use of adenosine is anticipated, then cardiac pads are placed on the chest of the patient in case of need for cardioversion. In our experience of more than 40 cases, they have not been needed so far.

We use adenosine in essentially two different scenarios. The first one is intraoperative rupture, which is difficult to control by other means. The short cardiac arrest and hypotension allows the neurosurgeon to suck all the blood from the operative field and place a pilot clip at the rupture site. With the bleeding under control, the operation continues with the pilot clip being replaced later by a better-planned, final clip. An experienced neurosurgeon can often see from the preoperative images which kind of aneurysm is prone to rupture prematurely and have the adenosine ready beforehand.

The other situation for use of adenosine is in complex aneurysms, where proximal control is difficult or impossible to obtain using the normal means of placing a temporary clip. In such a situation, the short cardiac arrest and hypotension makes the aneurysm dome soft and malleable so that the pilot clip can be introduced over the neck without the risk of tearing the aneurysm. The soft dome allows manipulation and proper visualization of the neck, which can otherwise be completely obstructed by the strong and large pulsating mass of the aneurysm.

Irrespective of the indication, the use of adenosine always requires seamless co-operation between the whole OR team. The neurosurgeon is the one to request its use, but the anesthesiologist should not give the drug until the scrub nurse has all the necessary clips prepared and the neurosurgeon has his or her instruments in position. After the adenosine injection the anesthesiologist starts counting aloud the systolic blood pressure every one or two seconds. When the blood pressure starts to drop, the neurosurgeon and the scrub nurse know that the time has come for them to execute their pre-planned actions.

## 6.2. ARTERIOVENOUS MALFORMATIONS

The microsurgical removal of a complex AVM remains one of the most difficult tasks in present day microneurosurgery. Unlike in tumor surgery, incomplete removal is likely to lead to death or disability. The most challenging aspects of caring for a patient harboring an AVM is to decide rationally upon the management strategy. A rough estimate for the patient is that the risk percentage to have a fatal bleeding from an untreated AVM during the remaining lifetime is  $(90 - \text{age in years})\%$ . The best and most definitive treatment of cerebral AVMs is still the complete microsurgical removal in experienced hands.

### 6.2.1. General strategy in AVM surgery

Every AVM is different, not only due to its location but also to its angioarchitecture. Careful evaluation of preoperative angiograms is in AVM surgery even more important than in aneurysm surgery. Due to the high variability between different AVMs, it is impossible to give general advice on how all of them should be operated on. But there are certain basic concepts that are employed and the final decision on the strategy is made on a case-by-case basis. Our microneurosurgical strategy in AVM surgery consists of the following main components: (a) accurate preoperative embolization; (b) selection of the optimal surgical approach; (c) identification and preservation of the normal passing-through arteries; (d) temporary clipping of feeding arteries; (e) coagulation of the small, deep feeders inside the normal brain surrounding the AVM ("dirty coagulation"); (f) preservation of the draining vein until the last phase; (g) complete removal of the AVM; (h) meticulous hemostasis; (i) intra- and postoperative DSA; and (j) clinical and radiological follow-up. In addition there are several other small details, which have been observed by us

and others over the years. All these steps are explained in more detail below.

There are two very important aspects regarding AVM surgery compared to e.g. tumor surgery: (1) the aim should always be the complete removal of the AVM since partial removal is of no benefit to the patient; and (2) during microsurgical removal the AVM should be removed in one piece, since internal decompression or piecemeal excision is not possible as it would only cause very heavy bleeding from the nidus. We do not recommend staged operations for AVMs as they significantly increase the rupture risk while waiting for the consecutive procedures. In addition, the anatomy becomes disturbed making any further surgical attempts even more difficult than the first one. One should be aware that once started, the AVM surgery must be carried all the way to the end.

#### *T&T:*

- *You can not "try" AVM surgery, you must know you can do it!*
- *You need to have an attitude of a tiger, a samurai, a fighter, or whoever who is 110% sure of winning!*

### 6.2.2. Preoperative embolization

Large AVMs can be often reduced in size with preoperative embolization. The feeders and the actual nidus can be occluded or reduced by endovascular means. The commonly used materials are glue and more recently Onyx. With glue the total obliteration of the nidus was uncommon, but nowadays with the use of Onyx, up to 50% of the selected cases can be occluded completely. Although the complete occlusion is often the aim, even partial occlusion can be

helpful from the surgical point of view. Preoperative Onyx embolization has revolutionized the treatment of AVMs, as many of them, after extensive filling with Onyx, can be removed or isolated from the circulation with much less difficulties than in their native state. However, poorly performed endovascular occlusion can be of more harm to microsurgical removal than of benefit. Each case should be evaluated by both interventionalists and neurosurgeons before the final treatment strategy is decided. Partial embolization alone, according to our follow-up, increases the risk of rebleeding almost threefold, and should be used only when followed by radio- or microsurgery.

Embolization is very useful in obliterating the deep feeders of the AVM, those that are difficult to reach with microsurgery, making surgical removal more feasible. Unfortunately, the deepest, the smallest and the most tortuous vessels can only seldom be reached and embolized to produce any real benefit for the surgery.

There are differences among the different embolic agents from the microsurgical point of view. Precipitated glue is a hard, brittle, and crystal-like substance, which is unmalleable and extremely difficult to cut. Onyx on the other hand is a softer, silicone-like material that can be easily cut with microscissors. There is one problem related to all the embolic substances. If a dilated vascular structure such as an intracranial aneurysm is filled with it, then it cannot be compressed or reduced in size with bipolar coagulation. Also, if there is some bleeding in between the embolic agent and the vessel wall, this cannot be sealed off by coagulation and such bleeding is actually very difficult to handle. But in general, due to the use of Onyx, intraoperative bleeding during AVM surgery has diminished a lot and the surgery resembles more that of extrinsic tumor surgery.

Timing of preoperative embolization is important. With Onyx, a large portion of the AVM is often occluded during one embolization ses-

sion. In our experience this has resulted in several very serious post-embolization bleedings of the AVM. They usually take place several days after the procedure, while the patient is waiting for scheduled surgery. The reason probably is a rapid change of the hemodynamic conditions inside the nidus. For this reason, lately, we have tried to perform both the embolization and the microsurgical removal without unnecessary delays, usually on the same day or on consecutive days.

### 6.2.3. Approaches

Operations for AVMs are performed under moderate hypotension. The head is significantly elevated above the heart level representing almost a semi-sitting position. A true sitting position is seldom used, only when truly required, such as in some midline posterior fossa AVMs. Lateral posterior fossa AVMs are operated in park bench position, as are many of the more posterior temporally, parietally and occipitally located AVMs. A modern, mobile operating microscope is of special importance. In fact, based on our experience, no AVM should be operated on without a microscope. Moving fluently around the AVM using the mouthpiece control of the microscope markedly reduces operating time. In microneurosurgery in general, our trend has been towards rather small bone flaps. However, in AVM surgery, especially in cortical ones, we often use larger craniotomies to obtain better orientation towards the AVM and its surroundings. In deep-located AVMs the keyhole principle, however, is still applied.

### 6.2.4. Dural opening and initial dissection

After the craniotomy, the dura is carefully inspected under the operating microscope because many draining veins, and also the AVM itself, can be firmly adherent to the dura. Adherence is especially common in redo-cases and after severe or several bleedings and/or



embolizations. With the dura opened, we first try to locate the feeding arteries. These can be visualized well in superficial AVMs by using intraoperative ICG videoangiography (Figure 6-10). The dynamic flow of the contrast inside the vessels allows for distinguishing between the arteries and the arterialized veins, which with the nidus still patent, have almost the same color under normal light.

The main draining veins are identified. They should be preserved until the very last steps of the AVM removal. AVMs with only one draining vein are usually more difficult to remove, as this single vein has to be preserved at all costs all the time. Premature occlusion of the sole draining vein can result in uncontrollable intraoperative AVM rupture and catastrophic results, especially in large or medium sized AVMs.

Sometimes the draining vein runs inside the bone and can be accidentally damaged already while removing the bone flap. This leads easily to catastrophic bleeding. One possible trick in such a situation is first to compress the bleeding site in the dura with a cottonoid and then to suture this cottonoid circumferentially to the surrounding dura to seal the bleeding until the final stage of the AVM removal. In situations with damage to the single draining vein and rapid swelling of the AVM, a fast and targeted removal of the lesion is often the only option. The task may become little easier, if there is an experienced assistant at hand to allow four-handed removal of the AVM. Infrequently, in some small AVMs, the draining vein can be cut on purpose during early steps of the removal, and this draining vein can be used as a sort of handle to help the dissection.

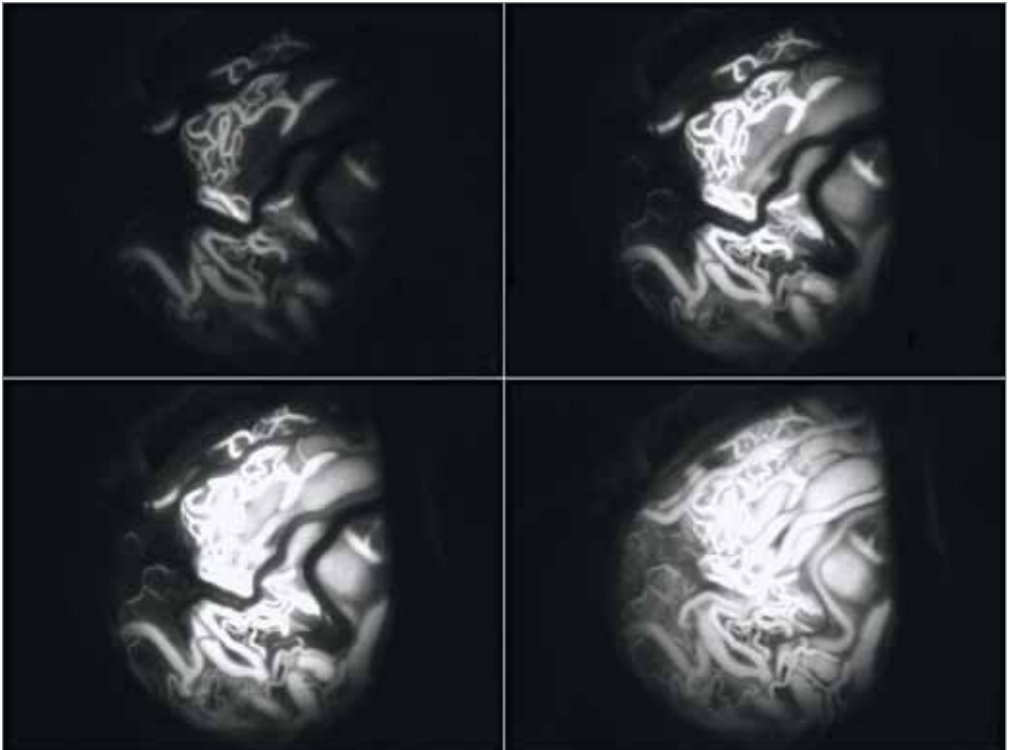


Figure 6-10. ICG videoangiography shows different stages of arterial and venous filling in a superficial AVM.

**T&T:**

- *Careful analysis of the angioarchitecture of the whole AVM should be carried out once the proper visual contact with the AVM has been established.*
- *The draining veins must be respected and preferably left intact until the final step of the removal*
- *In the beginning of the operation, a lot of time should be spent on careful dissection and identification of all the vessels in the vicinity of the AVM. This time pays back, as with clear anatomical understanding of the vascular relationships, the removal of even a complex looking AVM is possible.*

#### 6.2.5. Further dissection and use of temporary clips

The borderline between the AVM and the surrounding brain is generally grayish and has some glial scarring, especially in previously ruptured AVMs. Following embolization, small infarctions often surround the nidus. This soft, macerated tissue can be easily removed with suction for better visualization of the vascular structures. Often, the hematoma has already dissected the nidus from the surrounding brain, so that the AVM is easier to find and remove. Signs of past bleeding are found even in cases without any previous clinical evidence of rupture. In these cases the bleeding may have been misdiagnosed as an epileptic seizure.

Identification of the cleavage plane between the AVM and the brain is very helpful while removing these lesions. Although some authors prefer the technique of removing the AVM together with substantial amount of the surrounding brain tissue - they feel that the procedure is safer in this way as one does not get into contact with the nidus - our technique is to proceed along the cleavage plane delineating the nidus from the surrounding brain. Although initially a more tedious technique, its

greatest advantages are: (a) better orientation towards the different vascular structures, (b) targeted removal of only the AVM nidus, and (c) better identification of the passing-through arteries. This last point is especially important in AVMs located close to eloquent areas. Careful opening of the arachnoid planes with a sharp needle, jeweller's forceps and sharp microscissors, together with water dissection and small cottonoids, allows to delineate the nidus sharply and identify both the feeders as well as the draining veins. It is of utmost importance to understand where the borderline of the nidus is at all times, as accidental entering into the actual nidus is always followed by heavy bleeding. Already Olivecrona, and later many others such as Drake, Peerless and Yaşargil, have described that AVM surgery should proceed circumferentially around the whole AVM, while simultaneously coagulating all the small feeders. In Finnish there is a saying which describes this kind of behaviour as "a cat circling around a hot pot of porridge".

The initial inspection of the AVM is performed under less magnification, as this helps to understand the estimated borders of the nidus and to orientate oneself to the surrounding structures. Once that is done, the actual dissection of the AVM is performed under high magnification to facilitate better identification and handling of all the tiny feeders. The large feeding arteries are identified first. These are usually the easiest to handle both by preoperative embolization but also during surgery. We usually put temporary clips on these large feeders during the initial steps of the dissection. Later on, once the nidus has been delineated more and it is obvious that these particular vessels are terminal feeding branches not passing-through arteries, they are coagulated and cut. The duration of temporary clipping is monitored. Considering how long the temporary clips are usually in place, even up to several hours, surprisingly little or no adverse effects are seen postoperatively. This is probably due to a long-term adaptation of the collateral circu-

lation to the "vascular steal effect" caused by the fistulous nature of the AVM. We usually do not use permanent clips to seal small or larger arteries or veins. Instead, after initial coagulation and division, the vessel ends are sealed once again with bipolar coagulation. It is our long-term experience that with many small bleeding sites the number of clips starts to accumulate and the clips are often accidentally displaced leading to further bleeding. Exceptions of this are situations, where a relatively large feeder or draining vein was accidentally severed during early steps of the dissection. In such a situation, we place a vascular clip onto the distal end of the vessel next to the nidus. This clip helps in intraoperative orientation and it can be also used as a handle to manipulate the nidus. In addition, we can also connect a suture to the clip, which permits careful application of little tension onto the nidus during its excision from the surrounding brain.

#### 6.2.6. Coagulation and dissection of small feeders

The tiniest feeders of the AVM are always the most difficult to handle. As mentioned earlier, preoperative embolization is of great help for microsurgery as it can occlude large portions of the nidus and the large feeders. But it usually does not help in occluding the tiny feeders as these cannot be approached via the endovascular route. Hemostasis of the small and thin-walled fragile feeders close to the deepest portions of the AVM is the most cumbersome part of any AVM operation. The bleeding is difficult to control, as these vessels have virtually no wall for coagulation to be effective. They often burst and retract back into the white matter at which point they have to be chased deeper and deeper with coagulation until the bleeding stops. There is no possibility to tamponade these bleedings, as they are profuse and multiple. They start again immediately once the tamponade has been removed. The bleeding sites are difficult to locate so we strongly rec-

ommend using very high magnification during this step of the operation.

Earlier, as the last resort, we clipped these feeders with special microclips, and, indeed, in some cases after the use of many clips the bleeding stopped. But the accumulation of clips in the operative area became a problem. The clips were often accidentally displaced, resulting in further bleeding. Instead, we started to use the "dirty coagulation" technique. The idea is to surround the bleeding vessel with a little bit of brain tissue and to coagulate the brain tissue together with the vessel instead of coagulating the vessel alone, hence the name dirty coagulation. We use blunt bipolar forceps and relatively low setting on the bipolar (20–25 on our Malis device). The forceps must be clean and cold to prevent sticking. Sharp forceps stick to the brain more easily, which is why dirty coagulation is easier to execute with blunt forceps. Interchanging several forceps speeds up the operation. The whole bleeding area must be meticulously and systematically covered with dirty coagulation for all the bleedings to stop. This a very time consuming part of the operation, but one should be patient, as hurrying usually only aggravates the bleeding.

In case of a more serious bleeding, the whole team is immediately alarmed. The blood pressure is lowered even below 100 mmHg systolic (sometimes as low as 70 mmHg for a short period), the suction is often exchanged to a slightly larger diameter, and the bleeding sites are identified. As an emergency measure each bleeding site is first tamponaded with cottonoid and then followed by dirty coagulation as the permanent solution to the situation. In general, we prefer to take care of the bleeding immediately before proceeding further. Seldom, the bleeding site is packed and tamponated with hemostatic agent and a new working site is sought for, returning to the bleeding site later. The problem with this strategy is accumulation of cottonoids at the tamponation sites. These cottonoids may prevent access to the remain-

ing parts of the AVM and their careless removal provokes the bleeding again. When several bleedings start to occur, the AVM should be excised without further delays. In large AVMs the final stages of the excision are the most difficult ones. In prolonged operations the psychomotor weakness occurs easily, and small errors are made, often resulting in bleeding.

#### 6.2.7. Final stage of AVM removal

The last step before the removal of the whole AVM is coagulation and cutting of the last draining vein. At this stage the draining vein should already be dark or blue-colored as opposed to the red color and filling with arterial blood at the beginning of the operation. If the color has not changed, then it usually means that there is still some part of the AVM left. In such a situation, with good control over most of the AVM nidus, we place a temporary clip on the remaining draining vein. This temporarily increases the intranidal pressure and the remaining portion of the nidus may be identified by swelling. Besides the change in color of the draining vein, the devascularized nidus should be soft and malleable except for the parts filled with embolic material. A hard nidus usually means that some feeders are still left.

ICG can be of help during the final stages of the operation. Unlike at beginning of the surgery, the draining vein should no longer be filling prematurely. Actually, due to the relatively large diameter of the veins, the contrast medium often flows sluggishly and may even stagnate in place. Premature filling of the draining vein indicates AVM residual.

As the total removal of a complex AVM involves many operative steps, we prefer to operate at a brisk pace before fatigue sets in. The only exception is the initial careful and time consuming stage of studying the intraoperative anatomy. Operations of some large AVMs with

myriads of feeders may last up to 8 hours, but with experience ordinary AVMs can be removed in 2 to 4 hours.

#### *T&T:*

*At the beginning of a large AVM operation one often feels like the world's best neurosurgeon. This feeling changes rapidly into being the world's worst neurosurgeon, as soon as the ultra-small feeders of the deepest portion of the AVM start to bleed! This describes well how difficult and frustrating it is to control these deep feeders.*

#### 6.2.8. Final hemostasis

After removal of the AVM we systematically inspect the whole resection cavity by touching the surface gently with bipolar forceps and small cottonoids. If bleeding occurs, it usually means that a small remnant of the AVM has been left behind. The area is inspected and all the bleedings are coagulated until there is no more indication of residual AVM. Finally, the surface of the resection cavity is covered with fibrin glue and Surgicel, which is pressed on the fresh glue all around the cavity.

#### 6.2.9. Postoperative care and imaging

In complex AVMs we frequently use intraoperative DSA. This is both for orientation purposes as well as to localize remaining parts of the filling nidus. The postoperative DSA is usually performed in nearly all AVM patients during the same anesthesia before transportation to the neurosurgical ICU. Patients with straightforward small and medium-sized AVMs are woken up in the ICU over a period several hours following the surgery. They are kept normotensive, and discharged to a neurosurgical bed ward on the next day. Patients with complex or large

AVMs, especially those with myriads of small deep feeders that required heavy use of dirty coagulation intraoperatively, are usually kept in controlled moderate arterial hypotension (systolic 100–120 mmHg) for several days. This may also mean prolonged sedation. In some cases with very complex AVMs, we even use deep hypotension and deep sedation for several days. Despite the initial excellent postoperative CT images, we have seen a large postoperative hematoma occurring as late as one week after the operation. This has happened several times in patients with many tiny deep feeders. After introducing dirty coagulation, postoperative hematomas have been less frequent. In addition to hypotension, prevention of seizures is routine.

### 6.3. CAVERNOMAS

The two most common symptoms of brain cavernomas are seizures or hemorrhages. Recently, with the wide availability of MRI imaging, the number of asymptomatic, incidental cavernomas has been increasing rapidly. Patients with cavernomas fall into two groups, those with a single lesion and those with multiple cavernomas. Deciding on whether to operate in a particular case is not always straightforward. In situations where there is a single, symptomatic lesion the decision is rather simple. These are usually clear-cut cases and microsurgical removal is often beneficial. In patients with multiple cavernomas or asymptomatic ones the decision has to be made on a case-by-case basis after careful consideration of both the pros and cons of the treatment.

#### 6.3.1. General strategy in cavernoma surgery

From the microsurgical point of view, cavernomas are rather easy lesions to remove. They are clearly defined, they can be excised completely from the surrounding tissue and they do not bleed much during removal. However, at the same time, cavernomas are also one of the most demanding lesions to remove, especially if located near or in eloquent areas, brainstem or medulla. The most frustrating part of any cavernoma operation is to locate the lesion. Most cavernomas are small in diameter (less than 2 cm) and they are located somewhere inside the brain tissue. Only seldom the cavernoma is located superficially so that it can be seen directly at the cortical surface.

The greatest challenges in cavernoma surgery are: (a) to localize the lesion, and (b) not to damage the surrounding structures during removal. The whole microsurgical removal of the cavernoma should be planned to maximize the chances of success for finding the lesion. The optimal approach is the key. Without care-

ful planning, one may spend hours and hours searching for this small lesion somewhere inside the white matter with no anatomical landmarks to guide to the target. Meanwhile, some of the important white matter tracts or eloquent areas may be irreversibly harmed. Even few millimeters of brain tissue prevents a cavernoma to be seen from the surface. Once the lesion is located, the rest of the procedure is relatively straightforward, but still requires proper microsurgical technique to minimize unnecessary manipulation of the surrounding tissue. If possible, we try to remove cavernomas in one piece, but unlike AVMs, piecemeal removal is also possible, as cavernomas usually do not bleed profusely. Piecemeal removal is especially recommended in brain stem and other deep-located cavernomas.

#### 6.3.2. Intraoperative localization

There are essentially two main techniques how cavernomas can be localized. One option is to rely on anatomical landmarks, the other is to use the neuronavigator or some other coordinate system device and possibly ultrasound. We usually combine the two techniques. Anatomical landmarks are useful as long as the lesion is located close to some relatively well defined anatomical structure such as a cranial nerve, arterial branching site, or if the lesion is so superficial that it can be seen at the surface of the brain or in the ventricle at a defined area. The cavernoma itself is often darkish and its consistency is somewhat harder than that of the surrounding brain tissue. It may or may not be surrounded by small ICH cavity; large hematomas caused by cavernomas are rare. The brain tissue surrounding the cavernoma is generally yellowish, due to hemosiderin staining. In superficial lesions it is often the discoloration of the brain surface at a certain area, which is indicative of the cavernoma.

Anatomical structures, which are easiest to utilize in localizing cavernomas are arteries and their branching patterns. Cavernomas located close to the medial surface of the frontal lobe or those close to the Sylvian fissure can be often localized based on the course of the ACA or the MCA. Localization of brain stem cavernomas relies more on the origin of cranial nerves than on vascular structures. Location close to one of the ventricles may be of help, but only when this particular region of the ventricle is along some standard approach (e.g. interhemispheric approach and callosotomy into the lateral ventricle) that one has sufficient experience with. Otherwise, it may be difficult to even get into the ventricle, let alone find the cavernoma.

Nowadays, we routinely use neuronavigator in cavernoma surgery. It may be an adjunct to the anatomical landmarks, or, as often is the case, the only method on which to rely while searching for the cavernoma somewhere deep inside the white matter. We always take both T1 and T2 weighted MRI images, the former are used for image registration purposes, the latter show the cavernoma better. With the neuronavigator, one has to be both familiar with the device itself, but more importantly, aware of its limitations. Planning of the approach, checking the appropriate angle of the microscope and even the use of ultrasound to verify the findings should be performed several times before opening the dura. Once the dura has been opened and CSF released, the accuracy of the device becomes much worse due to brain shift. At this point, it is often safer to trust measurements with a ruler than the neuronavigator, which gives only a false feeling of safety.

Intraoperative ultrasound, as nice as it may sound, is often of much less help than expected. For someone unaccustomed to interpreting ultrasound images, it is difficult to navigate

based on this information. In skilled and experienced hands it may be of true value, especially if the device has a small ultrasound probe. But in our experience, ultrasound is of less value than careful preoperative trajectory planning and the use of neuronavigator.

What if everything fails, and despite all the possible precautions one still cannot find the cavernoma? In such a situation, we prefer to leave a small vascular clip as a mark along the approach trajectory and back off. The patient is woken up and MRI images are taken either on the same or the next day. In most cases the clip is found frustratingly close to the cavernoma, usually 5 mm or less. In the re-do surgery, performed within a few days, the cavernoma is then localized with respect to the clip and removed. Although this technique necessitates two surgical sessions, in the end it is safer for the patient than an extensive and possibly harmful search for the lesion during the first session.

### 6.3.3. Approaches

The approach is always selected according to the exact location of the cavernoma. The interhemispheric approach is used for cavernomas close to the interhemispheric fissure, the LSO for those where opening of the Sylvian fissure is needed and the retrosigmoid, subtemporal, lateral foramen magnum or sitting position approaches for brainstem cavernomas. Most of the brainstem cavernomas are very close to the surface somewhere along the brainstem. This is usually the place that we select as the planned point of entry and the actual approach is then planned accordingly to provide maximal exposure of this area. When the approach is based mainly on anatomical landmarks, the craniotomy and dural opening are executed in a similar fashion as for any other type of le-

sion approached in this manner. The exposure should be sufficiently wide to allow unhindered dissection along the natural planes. The brain is relaxed by the release of CSF. The aim is to arrive at the expected site of the cavernoma, hopefully identifiable by the discoloration of the brain tissue, along a natural route. Only once there, the brain parenchyma is entered.

In the vast majority of supratentorial and cerebellar cavernomas the anatomical landmarks cannot be well utilized, and we have to rely on the neuronavigator. The approach is selected to provide the shortest possible route to the cavernoma while avoiding the eloquent areas. We prefer either supine, semi-sitting or lateral park bench position. In prone position the use of the neuronavigator is generally more demanding. Contrary to the strategy applied when using anatomical landmarks, with the neuronavigator we try to minimize CSF release and brain shift. We also enter the brain tissue directly just beneath the dural opening. It is possible to follow natural planes such as a certain sulci, but as the sulci may be curving into a wrong direction, one might end up with a wrong approach trajectory. The craniotomy does not have to be large, 2–3 cm is often enough. Before opening the dura, the exact trajectory towards the lesion is checked several times. It is very helpful, if bipolar forceps, those used for dissection, can be fitted with neuronavigator markers. They are easier to handle than the often long and cumbersome pointer. Only small dural opening suffices, a curved 1 cm incision is often enough. Care is taken to release as little CSF at this point as possible. The cortex is incised and the brain parenchyma is entered along the line suggested by the neuronavigator. The angle of the microscope needs to be along the same trajectory, otherwise one starts to accidentally deviate from the planned trajectory.

#### 6.3.4. Dissection and removal

The approach through the brain parenchyma should be as gentle and short as possible. We use very high magnification during this step. The suction is exchanged for small bore (6 or 8) as there is only little bleeding. Every tiny bleeding should be identified and coagulated. We prefer to use sharp bipolar forceps. The neuronavigator is constantly checked for the correct approach angle, the "autopilot" option can be utilized if available. Close to the cavernoma the resistance of the brain tissue will suddenly increase and the tissue will become yellow and gliotic. This is a good sign, as the cavernoma must be very close by. The yellowish tissue is followed further until the actual cavernoma is recognised by its hard consistency and dark colour. It is usually just before finding the cavernoma, that the frustration from the whole procedure reaches its maximum. With the cavernoma visible and the most tedious part of the surgery behind, one can relax a little. Thin cottonoids can be inserted into the cavity to keep it open.

The cavernoma should be circled around with bipolar and suction. All the tiny feeders are coagulated and the gliotic tissue surrounding the cavernoma is removed. In brainstem cavernomas we often leave the gliotic tissue behind as we do not want to risk the possibility of damaging the surrounding. There are usually no large feeders into the cavernoma, however, there may be a large draining, venous angioma. General experience is, that the venous angioma should be left intact. Coagulating it or removing it may result in postoperative venous infarction of the nearby area. Small cottonoids can be used to dislocate the cavernoma and water dissection is carefully utilized to allow further separation of the cavernoma from the surrounding tissue. Small ring forceps are very helpful to pull gently on the cavernoma while detaching it with suction. If there is hematoma next to the cavernoma, this should be removed



along with the cavernoma. The cavernoma can be shrunk to a certain extent with coagulation, but especially in larger lesions, final piecemeal removal may be necessary.

Once the cavernoma has been removed, the whole resection cavity is carefully inspected for any remnants. The cavity is flushed with saline to detect any bleedings that are coagulated. We cover the surface of the resection cavity with Surgicel, sometimes even with glue. Special care is needed in cavernomas that are found at the surface of the ventricle. In these cases the hemostasis is even more important as there is nearly no counterpressure, and postoperative hematomas can happen much more easily than in cavernomas inside the brain tissue.

#### 6.3.5. Postoperative imaging

Postoperative MRI scans are very difficult to interpret after cavernoma surgery. There is nearly always some hemosiderin ring left even after complete removal. This can be accidentally interpreted as residual cavernoma even if the whole cavernoma has been removed. For this reason, unlike in other lesions, we tend to trust more the neurosurgeons evaluation of the situation at the end of the procedure than the postoperative images. The postoperative images are mainly taken to exclude complications, such as hematomas or infarctions.

## 6.4. MENINGIOMAS

Meningiomas can be roughly divided into four groups when their surgical technique is considered: (1) convexity meningiomas; (2) parasagittal meningiomas; (3) falx and tentorium meningiomas; and (4) skull base meningiomas. In addition there are some infrequent meningioma locations such as e.g. intraventricular meningiomas and spinal meningiomas (see section 6.9). Each of these groups has certain specific features, which require different approach and strategy. The common feature of all the meningiomas is that over 90% of them are benign, they usually can be removed completely, and they have a clearly defined border. The major vascular supply comes from the dural attachment, but especially in larger tumors there can be also feeders from the surrounding arteries. We advocate complete tumor removal in situations where it can be performed safely without excessive morbidity or mortality. In skull base meningiomas with the tumor surrounding the cranial nerves and infiltrating the cavernous sinus, one should be very cautious, and consider also other options besides surgery.

### 6.4.1. General strategy with convexity meningiomas

Convexity meningiomas are excellent targets for microsurgery. The aim is to remove the whole tumor as well as the dural origin. If possible, we try to remove the dural origin with a 1–2 cm margin. This means that the keyhole principle for craniotomy cannot be applied in these lesions. The craniotomy should provide at least a few centimeter margin along the borders of the whole dural attachment. In convexity meningiomas that are located cranial to the insertion of the temporal muscle, we plan a curved skin incision that allows a vascularized, pedicled periosteal flap to be used as a dural substitute. The local anesthetic injected along the wound causes swelling of the subcutaneous tissues

and the periosteum facilitating easier separation of the two layers. It is much easier to prepare the periosteal flap at the beginning of the surgery than when the closure starts. The bone flap is planned to allow for sufficient exposure of the whole tumor and its attachment. Unlike in other approaches, the dura is elevated to the edges of the craniotomy with tack-up sutures already at the beginning of the procedure, before opening the dura. This prevents oozing from the epidural space and even diminishes the bleeding from the tumor itself.

The next step is to remove major portion of the tumor's vascular supply coming through the dural attachment. To do this, the dura is cut circularly around the whole tumor with a few centimeter margin and the dural edges are coagulated. We prefer to use the microscope during this step, especially if the tumor is relatively close to the superior sagittal sinus in the midline. Cutting the dura should be performed carefully as not to sever any adjacent arteries or veins. At the same time this step should be done relatively briskly, because once finished, many of the small bleedings coming from the tumor surface will stop.

With the whole dural margin free, the actual tumor removal may proceed. The tumor should be dissected stepwise along the dissection plane between the tumor and the cortex. Passing-through arteries are identified and saved, feeding arteries are coagulated and cut. The shape of the tumor determines whether it can be removed in one piece or in several pieces. A conical tumor can usually be removed in one piece, whereas a spherical tumor with small dural attachment may require piecemeal removal to prevent excessive manipulation of the surrounding brain tissue. But even with the spherical tumor, as much of the tumor should be devascularized as possible before entering into the tumor itself. Entering into the tumor

is often followed by bleeding and necessity to spend a lot of time performing hemostasis, which slows down the whole operation. So, our strategy in convexity meningiomas is to enter into the tumor only if necessary, for the purpose of debulking it and making some extra room for its further dissection along the borderline. Otherwise we keep strictly to the dissection plane along the borderline and dissect the whole tumor free from its surroundings. Recently, we have been successful in preserving most of the cortical veins between the tumor and cortex. This certainly improves rapid recovery of the patient. The trick here is to use very high magnification of the operating microscope. It is much easier to follow the proper dissection plane and to distinguish between feeders and passing-through vessels under high magnification. Tumor removal is followed by careful hemostasis of the whole resection cavity and dural repair. If the bone is intact or only slightly hyperostotic, we use a high-speed drill to smooth the inner surface and place the original bone flap back. In situations when there is tumor invasion into the bone, we do not put the original bone flap back. Instead, we perform immediate cranioplasty with some artificial material such as titanium mesh, hydroxiapatite or bone cement.

#### 6.4.2. General strategy with parasagittal meningiomas

Parasagittal meningiomas originate from the cortical dura, but they are located next to the midline, sometimes on both sides of the midline. They have a special anatomic relationship with the superior sagittal sinus and the bridging veins, often invading them. The possible involvement of the venous system requires special considerations regarding the strategy for their removal. In general, of all the meningiomas located at the convexity, the parasagittal

ones are the most difficult to remove and they carry the highest risk of postoperative venous infarction.

There are two main problems associated with parasagittal meningiomas: (1) how to remove them without harming the surrounding bridging veins; and (2) what to do with the superior sagittal sinus? Extensive involvement of the superior sagittal sinus, its infiltration or even occlusion due to tumor tissue must be evaluated from preoperative images. Venous phase CTA, MRA or DSA images are used to analyze whether the superior sagittal sinus is still patent. If the superior sagittal sinus is occluded, we may decide to remove the entire tumor together with the dural origin by extending the dural resection to include the occluded sagittal sinus. In these cases, the meningioma is often bilateral. But if the superior sagittal sinus is still patent, we prefer not to touch the sinus. We can leave a small tumor remnant behind, at the lateral wall of the sagittal sinus. This small tumor remnant can be either followed conservatively or treated with stereotactic irradiation later on. The sagittal sinus may occlude completely over a longer period of time, at which point the removal of the tumor remnant can be planned. During the gradual occlusion of the sagittal sinus, venous collaterals have sufficient time to develop, so that venous infarctions develop seldom, unlike in acute occlusion during or immediately after surgery. In bilateral tumors, with the superior sagittal sinus patent, we do not resect the sinus unless it is in the anterior-most third of the sinus. Even at this location the risk of postoperative venous infarction exists and one should weight all the options before carrying out the resection. Irrespective of the faith of the sagittal sinus, all the bridging veins draining the surrounding cortex should be left intact.

The skin incision and bone flap are planned to allow for exposure of the whole tumor with several centimeter margin along its borders. The tumor can be either unilateral or bilateral on both sides of the superior sagittal sinus. Even for the unilateral tumor the bone flap should extend over the midline so that the whole superior sagittal sinus is exposed alongside the tumor. In the same way as with convexity meningiomas, the dura is elevated to the edges of the craniotomy already before the dural incision. In unilateral tumors the medial border towards the sagittal sinus is not elevated because of the risk of damaging a bridging vein. The dura is opened under the microscope. The dural incision starts lateral and proceeds towards the midline in a curvilinear fashion in both anterior and posterior direction. One has to be very careful with the bridging veins, especially close to the midline. Once the dural incision is made, the vascular supply of the tumor has been cut from all directions except the midline. Unfortunately, midline is the direction from which most of the vascular supply of the tumor comes from.

The next step depends on the anatomy of the tumor and its relation with the superior sagittal sinus. If the tumor has its medial edge alongside the sinus, but does not seem to infiltrate it on preoperative images, we proceed with cutting the dura along the midline, just next to the sagittal sinus. This step has to be performed under high magnification, small cut at a time. The superior sagittal sinus opens frequently during this step of the procedure, so to keep the situation under control, we make only a small cut at a time. Whenever the sagittal sinus is accidentally entered, the hole should be closed immediately with a suture. The suture is a more secure way of closing the small hole than hemoclips, which easily slide off. Coagulation with bipolar forceps makes the hole only bigger, so we do not recommend it. Once the dural cut has been completed, the tumor becomes devascularized for most part. The dissection plane between the tumor and the cortex is then expanded with

water dissection and small cottonoids. We usually start the dissection along the lateral border and proceed in the medial direction while cutting the arachnoid and attachments to the vessels. It is important to note that very often the veins draining normal cortical surface may pass below the tumor, but there is often a clear arachnoid plane separating them from the tumor surface. Again the dissection requires patience and high magnification. Once the whole tumor has been mobilized, it is removed, usually in one piece. With the major part of the tumor removed, the edges of the dural opening can be inspected for any tumor remnants. The dural repair can be performed either with the vascularized periosteal flap or with some artificial dural substitute in the same fashion as in convexity meningiomas.

In tumors, which infiltrate into the sagittal sinus, or grow on both sides of the sinus, the strategy is a little different. Once the dural flap has been opened with the base towards the midline, the aim is again to devascularize the tumor as much as possible prior to its removal. One possibility is to start to dissect the tumor away from the cortex starting at the lateral border. With water dissection the proper dissection plane is entered and followed beneath the tumor medially. The tumor can be lifted by gentle traction with a suture attached at its dural edge. With this strategy one is able to get very close to the midline, but the problem of the possible draining veins along or inside the medial border of the tumor remains. It is possible to amputate the lateral portion of the tumor to get more room and then start careful dissection alongside the sagittal sinus working on the intradural attachment of the tumor. In case of an occluded sinus and especially a bilateral tumor, the resection of the sagittal sinus together with part of the falx can be carried out once both tumor portions have been otherwise detached from their surroundings. The other possibility is to devascularize the tumor by coagulating and detaching it from the inner leaf of the dura along the whole dural attachment. This leaves the tumor

in place, while the dural flap is everted over the midline. With the tumor free from the dura, it is removed along its edges with water dissection and cottonoids. With more room and better visualization of the vascular structures the dural attachment can then be removed. Dural repair is again performed either with the vascularized periosteal flap or artificial dural substitute.

It is often difficult to identify the exact dural origin based on the preoperative images. It is not until the actual surgery that we see, whether the dural origin is at the convexity or from the falx. In falx meningiomas the resection of the cortical dura is not always possible, sometimes even unnecessary, and there may be no need for duraplasty. In general, we tend to prepare for the more complicated option while planning the surgery and then modify our strategy based on the actual situation.

#### 6.4.3. General strategy with falx and tentorium meningiomas

Falx and tentorium meningiomas differ from typical convexity meningiomas mainly due to their possible invasion into a venous sinus, typically the superior sagittal sinus or transverse sinus in the same way as parasagittal meningiomas. Preoperative MRA, DSA or CTA with venous phase are helpful in determining whether the sinus is still patent or occluded. In case of a patent sinus, we generally leave the tumor infiltrating the sinus intact and later treat this region with stereotactic irradiation. Chasing the tumor all the way into the sinus often results in damage to the sinus and sinus thrombosis with possible catastrophic venous infarctions. Repairing a damaged sinus intraoperatively is very demanding as it bleeds profusely. Even if the repair is initially successful, sinus thrombosis can still occur several days later. Along the anterior one third of the superior sagittal sinus the risk of venous infarctions is smaller, but we seldom resect the sagittal sinus even at this location. If the sinus is truly occluded, then

partial resection of the sinus together with the falx is possible.

In the similar fashion as for parasagittal meningiomas, the craniotomy should be planned according to the exact tumor location and tumor size, so that the whole tumor can be visualized well. The craniotomy is planned to extend on both sides of the sinus, more on the side where the majority of the tumor is. It is much easier to repair an accidentally severed sinus if one has good access to both sides. Also, with this kind of craniotomy one is able to push the venous sinus together with the falx or tentorium slightly to the opposite side to gain a little extra room for dissection. In planning the dural opening one has to take into consideration the presence of bridging veins running from the cortical surface to the dural sinus. These veins should be left intact during the operation, so the opening needs to be usually a little longer alongside the sinus than what the tumor size itself would require to facilitate tumor dissection in between the bridging veins. The dura is opened as U- or V-shaped flap with the base towards the venous sinus. In bilateral falx meningiomas or tentorial meningiomas with major extension to both the supra- and infratentorial region, the dural opening has to be planned on both sides of the venous sinus. If the tumor is only on one side, unilateral dural opening is sufficient. The same applies for tumors with little extension to the opposite side but with an occluded sinus.

With the dura opened, the first step is to gain more room by releasing CSF. In falx meningiomas this means entering into the interhemispheric fissure, in tentorium meningiomas into the superior cerebellar cistern and the quadrigeminal cistern. Once the brain is relaxed, the whole attachment of the tumor to either the falx or the tentorium must be visualized. Tumor removal starts with coagulation of the whole dural attachment. This removes majority of the tumor's blood supply facilitating cleaner surgery. With the dural attachment disconnected,

part of the tumor may be debulked with suction if necessary to provide more room. Otherwise, the dissection plane along the borderline of the tumor is identified and expanded with water dissection and cottonoids. All the arachnoid attachments, the arterial feeders and veins are coagulated and cut. The whole tumor is encircled until it is freed and can be removed in either a single piece or several pieces depending on the size of the tumor and the room provided in between the bridging veins. All the passing-through arteries and veins should be left intact. The same applies for bridging veins.

Depending on patient's age, other diseases and the patency or occlusion of the venous sinus, the falx or tentorium is then either resected along the area of the original dural attachment or the dural attachment site is just further coagulated. If the sinus is occluded, we usually choose to resect the dura with the occluded sinus. Before cutting the occluded sinus, we ligate it with several sutures proximal and distal to the planned resection segment. In situations with a patent sinus, resection of the dural attachment has to be planned so that it starts just below the lower margin of the sinus. In older patients, or if the dural tail is only very small, instead of resecting the dura, we may only coagulate it thoroughly over a wider area. This is done with blunt bipolar forceps and a higher than usual setting of coagulation power for intracranial work (50 on our Malis device). We resect the tentorium less frequently than the falx, since the tentorium is often more difficult to access and there are more venous channels running inside it.

In bilateral tumors the strategy of tumor removal may be a little different. There are actually two different options. The first option is to handle tumor extensions on both sides in the similar way as described above, followed by resection of the falx or tentorium. The other option is, to start directly with coagulation and cutting of the falx anterior and posterior to the tumor, as this devascularizes both sides at the

same time. The tumor is then detached on both sides along its border and removed as a single piece. This strategy is really feasible only in situations with an occluded venous sinus.

The dural flap can be often sutured directly along the line it was opened, unless, the venous sinus has been partially removed leaving a large dural defect. In such a case, duraplasty is performed either with a periosteal flap or some artificial dural substitute. As with convexity meningiomas, the original bone flap is placed back if intact, but in case of tumor invasion, immediate cranioplasty is performed.

#### 6.4.4. General strategy with skull base meningiomas

The skull base meningiomas are the most complex group of all the meningiomas. They originate from different locations at the base of the skull and due to their central location they are frequently involved with large intracranial arteries as well as the cranial nerves and important basal structures of the brain. It is certainly very different to plan surgery for a small olfactory groove meningioma than for a large petroclival meningioma. Each of the most common locations has its specific anatomic and functional considerations. It is not possible to address all these issues in this relatively limited text, but we try to present some of the general considerations for surgery of these lesions.

In large skull base meningiomas, some neurosurgeons aim to remove the tumor to the last tiny portion through extensive skull base approaches, even if the tumor is extensively involved with vessels and cranial nerves. Others do not want to touch these lesions at all. Our policy has lately shifted in the direction of small approaches and sometimes only partial removal of the tumor. We target only that portion of the tumor, which can be accessed through small and targeted openings, without extensive drilling of the skull base and without tak-

ing extreme risks of postoperative cranial nerve deficits. If there is some tumor left behind, this is either followed, or treated with stereotactic radiosurgery. We are well aware, that with some of the huge skull base approaches it is possible to obtain slightly better tumor removal rate, but the downsides of these approaches are frequent postoperative complications and neurological deficits. Many times, even in the best and most experienced hands, there is still some tumor left behind even after this kind of extensive removal and the patient is left with much worse deficits than what would be the case after a less ambitious approach. Whenever it is possible to remove the whole tumor with reasonable risk, we go for this option. But in large and invading skull base meningiomas, e.g. meningiomas invading into the cavernous sinus, we have learned to be more conservative.

The approaches used with skull base meningiomas depend entirely on the exact location of the tumor. The approach is always selected so that it provides the best possible view towards the dural origin of the tumor as well as to the major vascular structures and cranial nerves. Since most of the tumors are relatively far away from the actual craniotomy site, the keyhole principle can be applied. The only truly extensive approach we use is the presigmoid approach for petroclival meningiomas. For other locations we generally find our normal small approaches sufficient (see Chapter 5). In re-do cases, we try to select a different approach than what was used in previous surgery to evade the tedious process of going through arachnoid scarring.

Intradurally, the first task is always to relax the brain by removal of CSF from the appropriate cisterns. The actual tumor is approached only after a slack brain has been achieved. With more room for dissection, the tumor location is inspected and all the surrounding arteries, veins and cranial nerves are identified. The final strategy for tumor removal is planned based on visual inspection of the surroundings as well as

on how the tumor is involved, possibly encircling or invading all the important neurovascular structures. Any vessels or nerves covering the tumor are carefully dissected free and mobilized if possible.

With the dural origin of the meningioma visible, we start devascularizing the tumor by traveling along the dural attachment, coagulating and cutting it. The aim is to cut off the main blood supply, which comes through the base of the tumor. Sometimes the tumor may be so big, that it prevents identification of the structures covered by it. To obtain some room for better visualization of the surrounding structures, the tumor is usually partially debulked, before the removal continues. For debulking, the tumor is entered with constant blunt bipolar coagulation (higher setting than normally, Malis 50-70), and the macerated and coagulated tumor tissue is removed with suction. An ultrasonic aspirator is seldom used because the combined repetitive movement of suction and bipolar forceps achieves the same result with less bleeding. Once there is sufficient room, the dissection continues along the tumor surface. Water dissection is used to gently expand the plane between the tumor and the brain tissue. Skull base meningiomas have frequently also other feeders than just the dural attachment. These can be often seen already on the preoperative images as originating from one of the major intracranial arteries or one of their branches. Careful identification and disconnection of all these small feeders should be performed under high magnification. Each feeder or vein should be coagulated and cut. If any of these small vessels are torn accidentally, they usually retract backward into the brain tissue and become very difficult to identify and to coagulate. The devascularized tumor is then removed either in a single piece or in several pieces depending on the anatomical situation.

In skull base meningiomas we do not resect the dural attachment routinely. Rather, with the tumor removed, we carefully coagulate the

whole dural origin with bipolar forceps (Malis 50-70). In patients with a long life expectancy and suitable anatomical conditions, the dura near the origin of the tumor is stripped off with either a monopolar or knife, and the hyperostotic bone is drilled away with a diamond drill. The diamond drill can also be used to stop some of the small oozing coming from the bone. Fat and fascia graft together with some artificial dural substitutes and fibrin glue are used to cover dural and bony defects of the skull base to prevent CSF leakage. Seldom, a bone graft taken from the bone flap is added to seal a bony defect at the skull base. Finally, the craniotomy as well as the wound are closed in standard fashion.

#### 6.4.5. Tumor consistency

In essence the consistency of meningioma tissue varies from very soft and almost transparent tissue, which can be easily sucked away, to very hard calcified tissue, which can be removed only in small pieces. So far, it has not been possible to accurately determine the tumor consistency from preoperative MRI images, so one never really knows until the tumor has been exposed. A hard tumor is always more difficult to remove than a soft tumor. A hard meningioma cannot be properly debulked. Even slight manipulation leads easily to compression and possible damage of the surrounding structures, and a hard tumor is more difficult to coagulate. Postoperative complications in the form of cranial nerve deficits are more frequent in patients with a hard tumor. In convexity meningiomas the tumor consistency does not play that much of a role, but especially in skull base tumors it very much determines how much of the tumor can be removed and whether extensive removal should be attempted or not. A hard tumor, which is involved with surrounding structures and possibly invading into the e.g. cavernous sinus is better partially left behind than risking significant postoperative deficits due to extensive manipulation of neurovascu-

lar structures. A soft tumor, where suction can be used to remove tumor remnants from small gaps in between the important structures, can be removed more completely. Furthermore, the tumor consistency does not seem to be indicative of its grade.

#### 6.4.6. Approaches

For convexity meningiomas the patient position and approach is selected so as to provide the best possible visualization and access to the whole tumor. The neuronavigator is often of help in planning the exact location of the craniotomy and the skin incision. We use supine, park bench, semi-sitting or sometimes even prone position for convexity meningiomas. The important thing to remember is to keep the head well above the cardiac level to keep the bleeding at a minimum.

For parasagittal and falx meningiomas the most common positions are supine, semi-sitting and prone combined with the interhemispheric approach. The exact position depends on the location of the tumor in anterior-posterior direction. The aim is to have a relaxed posture for the surgeon but at the same time both anterior and posterior border of the tumor should be visualized.

Tentorium meningiomas are operated on either in lateral park bench position or in sitting position. The lateral park bench position is used in tentorium meningiomas, which have the major part of the tumor mass supratentorially. The sitting position with supracerebellar-infratentorial approach is used for tentorium meningiomas that are mainly infratentorial. Prone position is problematic, because it requires the chin to be flexed considerably downwards and the head to be placed well below the cardiac level to obtain a good visual trajectory infratentorially. This, on the other hand, increases the venous bleeding and makes the surgery more difficult.



All of the anterior fossa, parasellar and sphenoid wing meningiomas are operated through the LSO approach. Medial sphenoid meningiomas with extension into the middle fossa need an LSO approach with temporal extension or pterional approach. The subtemporal approach is used for meningiomas of the lateral wall of the cavernous sinus and those of the anterior and middle parts of the middle fossa. Petroclival meningiomas usually require a presigmoid approach with partial resection of the petrous bone. Meningiomas of the cerebellopontine angle are approached via a retrosigmoid approach. Those at the level of foramen magnum are approached either through the "enough" lateral approach to the foramen magnum or, infrequently, using a sitting position and the low midline approach.

#### 6.4.7. Devascularization

Devascularization of the tumor is the cornerstone of every meningioma surgery. As already described earlier, most of the tumor's blood supply comes from the dural base. Thus, this should be attacked first. For skull base, falx and tentorium meningiomas the best technique is to coagulate with bipolar forceps along the dural surface and detach the whole base in step-by-step fashion. In convexity and parasagittal meningiomas it is possible to detach the tumor from the dura as well, but this process is often more time consuming and does not provide any true benefits if compared with immediate excision of the dura around the whole tumor. We prefer to do this step under the microscope to prevent unnecessary damage to any cortical or passing-through vessels. In general, most of the arteries and veins are found beneath the tumor on surface of the cortex, but especially close to the midline there may be vessels covering the tumor as well.

With the dural attachment cut, the remaining blood supply of the tumor will come from smaller or larger perforators surrounding the

tumor. In convexity meningiomas this is less frequent than in the other meningioma types. Extra feeders are also more often found in large tumors than in small ones. The trick here is to use high magnification and, while dissecting the tumor from its surroundings along the tumor surface, to identify all the feeders and veins, and to coagulate and cut them pre-emptively. Coagulating the vessels is often not enough, since they may overstretch while the tumor is manipulated, and be accidentally torn. These torn, small vessels tend to retract into the brain and continue to bleed from there. In a large resection cavity it may become extremely difficult to reach some of the retracted vessels later on as they may be hidden behind a corner.

We prefer not to enter the tumor itself, unless it is necessary for debulking purposes. Even then it should be done cautiously with bipolar and suction rather than ultrasonic aspirator to keep the bleeding at minimum. Preoperative embolization of the tumor may be beneficial in case the tumor is large and highly vascularized. Even then the attempt should be made to occlude the small perforators and feeders instead of the big ones, which are usually easy to handle during surgery, a situation similar to AVM surgery.

#### 6.4.8. Tumor removal

The crucial part of dissecting a meningioma is to find the proper dissection plane between the tumor and the brain. Sometimes there is a clearly defined arachnoid plane that is easy to follow, but at times the tumor can be densely attached to the cortex. We use water dissection extensively when detaching meningiomas from their surrounding. The small arteries and veins are left intact by the water dissection, so they can be then either coagulated and cut or saved in case of passing-through vessels.

We start the dissection at a location where the borderline between the tumor and the cortex

can be clearly defined. The arachnoid plane is first expanded with water dissection. Saline is injected with a blunt needle along the dissection plane that expands and pushes the tumor away from the cortex. Then under high magnification the tumor is pushed away from the cortex and arachnoid attachments and feeders are coagulated and cut. Small cottonoids are inserted into the already dissected location and the dissection continues in the same stepwise fashion along the whole surface of the tumor. During dissection the tumor should be at all times pulled away from the brain tissue and one should compress the brain as little as possible. One should remember that while pulling the tumor away from the brain on one side, it may be pushed against the brain on the opposite end. This is important in situations when the brain is edematous and there is lack of space. CSF release and partial debulking of the tumor should help under these circumstances.

*T&T:*

*When removing a meningioma, always work away from the normal brain tissue.*

Even if we decide to remove the tumor in pieces, we first devascularize and detach a certain portion of the tumor along its border and only after that we cut and remove this piece with microscissors. We no longer use loop diathermia except in very special cases of a very hard tumor. In our experience, the current from diathermia spreads over a larger area causing easily damage to the surrounding neuronal and vascular structures. In addition, the resection bed may start to bleed after each slice is removed and one has to spend a lot of time on hemostasis before proceeding any further.

Sharp dissection and high magnification are used at sites where the tumor is attached to either nerves or important vascular structures. The aim is to preserve all these structures intact and remove only the direct attachments

to the tumor. Saving a passing-through artery may easily turn the otherwise and straightforward removal of a small convexity meningioma into a tedious and time consuming procedure. But we feel this is time well spent, and with time and experience it also becomes easier.

Once the whole tumor has been removed, the whole resection cavity is inspected for any possible tumor remnants and all the small bleeding points are coagulated once again. The walls of the cavity are covered with Surgicel, sometimes also with fibrin glue.

#### 6.4.9. Dural repair

In skull base and falx meningiomas we always weigh the benefits and potential harm caused by removing the dural origin. In case there is a larger defect in the basal dura, we try to seal it either with fascia or artificial dural graft. In addition, fat graft is used in situations with potential CSF leak. The more extensive the removal of the bone and the larger the dural resection, the greater also is the subsequent risk for postoperative CSF leak.

In patients with convexity meningiomas we often use a vascularized pedicled periosteal flap, which was prepared already during opening. This pedicled flap is sutured to the edges of the dural defect with a running suture along the entire defect. The other possibility is to use an artificial dural graft, which saves the time of detaching the periosteal flap. The problem with the artificial grafts is that they are usually more difficult to seal watertight. Irrespective of the dural closure method, we do experience subcutaneous CSF effusions in some patients. Most of them are easily treated with compress dressings, but some may require a spinal drain for a few days.

## 6.5. GLIOMAS

Gliomas are frequent targets for intracranial microneurosurgery. The aim of the operation is two fold: (1) to remove as much of the tumor as possible without causing new neurological deficits, and (2) to obtain accurate histological diagnosis of the tumor grade. Except for some grade I tumors, gliomas cannot be cured by surgery. On the other hand, with good microsurgical technique it is possible to remove large quantities of the tumor mass without causing damage to the surrounding areas. Since gliomas usually do not have a clearly defined border, one of the most challenging tasks is to decide how far to proceed with the tumor removal and when to stop. This becomes even more important in tumors located close to or in eloquent areas. New neurological deficits caused by the surgery decrease the quality of life and there are even indications that they may shorten the life expectancy. From the microsurgical point of view gliomas can be divided into two main groups: (a) low-grade gliomas (grades I and II), and (b) high-grade gliomas (grades III and IV). The surgical strategy and technique differs slightly between the two groups mainly due to tumor consistency and vascularization. The microsurgical strategy has to take also into account the possible benefits or complications caused by the surgery.

### 6.5.1. General strategy with low-grade gliomas

In low-grade gliomas we aim at more aggressive tumor removal than in high-grade gliomas. The potential benefit of removing the entire visible tumor is greater and the recurrence free survival time can be increased more than in high-grade tumors. This is especially true for some grade I gliomas where total removal may even be curative. The tumor tissue itself is different from high-grade tumors. Its color is usually paler than the surroundings, its con-

sistency can be slightly elastic, and it does not bleed much. It does not contain necrotic parts but there may be cystic components.

The approach and craniotomy is selected so that the tumor can be visualized well. In cortical tumors the exposure should allow for the whole tumor with its borderlines to be visualized. In deeper-seated tumors the access route needs to be such that the whole tumor can be accessed. The aim is to remove the whole tumor as seen on preoperative images. It is inevitable that there will be some tumor cells left behind at the border due to the infiltrative nature of gliomas. In situations where the tumor is located in a relatively safe area such as the anterior portion of the frontal lobe or anterior part of the temporal lobe, it is often possible to remove the tumor with a few centimeter margins. Close to eloquent areas this is not possible and one should stick to the tumor boundaries.

The intracranial part of the operation starts with CSF removal and relaxation of the brain. Especially in large and expansive tumors the approach should be planned so, that it not only provides good visualization of the tumor itself but also gives access to one of the major cisterns to allow CSF to be released. The actual tumor removal starts with identification of the tumor and its borderlines with respect to the surrounding anatomy. Once the extent of the tumor is known, it is possible to start with the actual tumor removal. We plan the resection along the borderline, following natural anatomical planes if possible, such as gyri and sulci. All the passing-through vessels should be saved. The cortex is devascularized at the entry point, incised and entered with bipolar forceps and suction. We follow the borderline while constantly coagulating and suctioning the softened tumor tissue. The ultrasonic aspirator may be helpful in low-grade gliomas

since the tumor tissue is not very vascularized and does not bleed much. But while using the ultrasonic aspirator, one has to be aware of the course of all the major arteries and veins not to accidentally sever them. Initial tumor decompression may be sometimes necessary to obtain better access to the borderline region. The tumor resection along the predefined borderline continues until the major tumor mass can be removed either in one or several pieces. With the major portion removed, the resection cavity is closely inspected and the resection continues with removal of the portions that have been left behind. The aim is to reach relatively normal looking brain tissue at the borderline. All the small bleedings from the resection cavity must be stopped and finally the resection cavity is lined with Surgicel. The dura and the craniotomy are closed in standard fashion.

#### 6.5.2. General strategy with high-grade gliomas

In high-grade gliomas, surgical treatment is only part of the whole treatment process. Our present treatment strategy is to remove as much of the contrast-enhancing tumor as possible, followed by radiotherapy or more frequently by chemo-radiotherapy. Each case is discussed in our neuro-oncology group that consists of neurosurgeons, neuroradiologists, neurologists, neuropathologists and neuro-oncologists.

The surgery itself aims at removal of the tumor mass, but again with minimizing the risk of neurological complications. New postoperative deficits may actually shorten the life expectancy of these patients. However, this does not mean that we would settle only for moderate internal decompression as may be the policy in many departments. If we decide to go for open microsurgical operation, than we try to use all our technical skills to remove as much of the enhancing tumor as possible while preserving all the surrounding structures. Especially in older patients with deep-located tumors, we

may choose only stereotactic biopsy followed by radiotherapy.

The approach is selected so that the tumor can be reached optimally. High-grade gliomas are usually more vascularized than low-grade gliomas, which has to be considered while planning the tumor removal. Slack brain is obtained by release of CSF from various cisterns. Additional room may be achieved by internal tumor decompression, or by releasing fluid from the cysts inside the tumor if present. Entering into the actual tumor results often in bleeding from its numerous pathological feeders. While the outer border of the tumor is highly vascularized, the innermost portion may be almost avascular, necrotic and sometimes cystic. The vascularized tumor tissue is often darker or redder than the surrounding brain, while the necrotic portions are yellowish and may contain thrombosed veins. The high vascularization and tendency to bleed is the reason why in malignant gliomas the use of ultrasonic aspirator is kept at a minimum. Instead, we prefer to remove the tumor with constant coagulation of blunt bipolar forceps in the right hand and small repetitive movement of the suction in the left. This technique provides better hemostasis throughout the procedure.

In superficial tumors the removal should be performed in a very similar way as with AVMs. The tumor should be followed along the borderline, coagulating and making hemostasis all the time. The center of the tumor is not entered unless necessary for decompression purposes. This keeps the bleeding at a minimum. In tumors located either close to eloquent or subcortical areas, we alter this approach strategy. In these cases, we enter into the tumor directly and perform most of the removal from inside out. In this way we try to manipulate as little of the surrounding functional tissue as possible. Constant use of bipolar coagulation is a must to keep the bleeding at minimum. While inside the actual tumor tissue, the risk of causing new neurological deficits is small. The problems arise close to

the borderline of the tumor. Like with low-grade tumors, there will be always tumor tissue left behind due to the infiltrative nature of the gliomas. But the contrast enhancing tissue is usually removed, once the resection surface stops to bleed and the tissue starts to look similar to normal white matter. The use of 5-ALA with a suitable microscope camera system helps in identifying the borderline of the enhancing tumor. All passing-through arteries should be saved in the same way as with low-grade gliomas. Once the tumor has been removed to the best of our knowledge, careful hemostasis is performed along all the walls of the resection cavity and the resection bed is lined with Surgicel.

The closure is performed in a normal fashion in layers. In redo-surgeries of patients with previous radiation therapy the skin tends to be thin and atrophic. In these cases, risk of postoperative subcutaneous CSF collection as well as CSF leakage through the wound is much higher. Both the subcutaneous and the skin layer have to be closed even more carefully than usual and we keep the skin sutures in place for longer, sometimes even several weeks, before the wound has properly healed.

### 6.5.3. Approaches

In glioma surgery, the tumor location determines the exact approach to be used. We use all the different positions (supine, lateral park bench, prone, semi-sitting, and sitting) described earlier in Chapter 5. Our aim is to get to the tumor along the natural anatomical planes while damaging as little of the normal tissue as possible. The craniotomy should provide nice and easy access to not only the tumor, but it should also allow CSF release in situations with lack of space. The head should be well above the heart level to allow for better venous drainage and less swelling. In cortical tumors the craniotomy and dural opening is usually larger so that the borderlines of the whole tumor can be accessed. In deeper-seated

lesions the access route can be small, based on the keyhole principle.

While planning the skin incision one should remember that especially in malignant gliomas, the patient is likely to receive postoperative radiotherapy. Straight or only slightly curved incisions tend to heal better as they have more extensive blood supply, than flaps with only a narrow pedicle.

### 6.5.4. Intracranial orientation and delineation of the tumor

Due to the infiltrative growth of the gliomas, intracranial orientation and delineation of the tumor is one of the most difficult tasks in any glioma surgery. On the cortex, the tumor tissue itself can be often recognized by a darker color, but its borderline is not sharp, so one has to estimate where the tumor ends and normal tissue begins.

Whenever possible, we try to orientate according to anatomical structures. Natural planes or vascular structures can be utilized as orientation marks. One should also plan the operation in steps so that removal of each part of the tumor should end once a certain anatomical structure has been reached. Often there are no clearly defined anatomical structures in the vicinity. Then the only option is to rely on one's 3D imagination, careful inspection of the tissue, using a ruler, and pure intuition. Measuring the tumor dimensions on preoperative images and comparing them with on-site ruler measurements provides usually good estimate of the extent of the tumor resection. Before the tumor removal starts, one needs to have a rough plan about the dimensions of the tumor in different directions as well as the location of all the potentially endangered structures. It is almost impossible to orientate oneself if the surgery is entered midway through. The initial inspection and orientation phase is better performed with less magnification as it helps in understand-

ing the different dimensions. Once the actual tumor removal starts, we go to a higher magnification. If one gets lost midway through the surgery, reducing the zoom and careful measurements with the ruler usually help.

In tumors close to eloquent areas we like to use the neuronavigator. It is helpful while planning the approach and identification of the borderlines of the tumor immediately after the dura has been opened. Once CSF has been released and part of the tumor debulked, the information provided by the neuronavigator becomes less accurate.

#### 6.5.5. Tumor removal

Constant coagulation of the tumor tissue with blunt bipolar forceps and suctioning of the macerated tissue away is the most important technique for removing gliomas. Unlike with the ultrasonic aspirator, the use of bipolar forceps not only dissects the tumor tissue but also coagulates. Whenever there is a bleeding, it is better to spend time to coagulate it completely before proceeding further. Once the resection surface increases, all the small oozing transforms into a pool of blood which is much more difficult to handle. We like to flush the operative area frequently with saline, as this helps in identifying all the small bleeding points.

We often use cottonoids to mark different dissection borders of the tumor. This helps in orientation towards the borderline when approaching the same borderline from a different direction. At the same time the cottonoid tamponades the resection surface and lessens oozing from the resection bed. In larger resection cavities the cottonoids can be used to prevent the cavity from collapsing facilitating easier removal of the remaining tumor.

During glioma surgery, it is essential to take many representative samples of the tumor. We take some samples already from the borderline of the tumor and then continue throughout the procedure, whenever there is some change of consistency in the tumor tissue. Frozen sections are analyzed immediately, but it takes usually about a week before the final grading is obtained.

## 6.6. COLLOID CYSTS OF THE THIRD VENTRICLE

Colloid cysts are small-sized, well-circumscribed and relatively avascular lesions, principally ideal for surgical removal. However, their deep location in the midline poses its challenges. Nowadays, with good illumination, magnification, and improved imaging and surgical techniques, third ventricle colloid cysts can be removed safely. There are several possible approaches and techniques which can be used to operate on colloid cysts including: (a) interhemispheric route and lateral transcallosal approach; (b) interhemispheric route and midline transcallosal route between the fornices; (c) transcortical route directly into the lateral ventricle; (d) stereotactic approach; and recently (e) endoscopic approach. Of the microsurgical approaches we prefer the lateral transcallosal approach via the interhemispheric route. In this approach the risk for damaging either fornix is extremely small as the lateral ventricle is entered way lateral from the midline. Compared to the transcortical approach, the transcallosal approach involves only a small part of the commissural system, whereas the transcortical approach injures several layers of connective systems and other essential components of white matter. The endoscopic approach provides best illumination and visualization of the lesion and its surroundings. Unfortunately, the instruments are still very rudimentary compared to microsurgical instruments and do not provide as good control over the situation as one would wish for.

### 6.6.1. General strategy with colloid cyst surgery

The most important cause of symptoms from the third ventricle colloid cyst is hydrocephalus. The aim of the removal of the colloid cyst is to free both foramina of Monro and to normalize the CSF flow. Simple aspiration of the fluid from inside the colloid cyst seems to result in

more frequent recurrences than if the cyst is removed completely including its outer layer.

We prefer the interhemispheric route with transcallosal opening lateral to the midline to arrive directly at the frontal horn of the lateral ventricle at the level of foramen of Monro. A right-sided approach is usually more convenient for a right-handed neurosurgeon. The potential complications of this approach arise mainly from damage to the bridging veins, damage to the fornix at the level of foramen of Monro (infrequent), and intraventricular bleeding from the small feeders of the colloid cyst. In addition, there is the possibility of entering the lateral ventricle either too anterior or too posterior, which may result in orientation problems and difficulties in accessing the foramen of Monro and the colloid cyst. All the steps of the operation should be planned to minimize these potential problems.

### 6.6.2. Positioning and craniotomy

The patient is placed in a semi-sitting position and fitted with G-suit trousers. The head is slightly flexed, but there is no rotation or lateral tilt. We use the Sugita head frame for semi-sitting position. With the correct head position the approach trajectory is almost vertical. Tilting the head to either side increases the chance that the bone flap is placed too laterally from the midline. This would make the entrance into the interhemispheric fissure and navigation there more difficult. A slightly curved skin incision is planned with its base frontally just behind the coronal suture. The incision extends on both sides of the midline, little more on the side of the planned approach. A one-layer skin flap is reflected with spring hooks frontally and one spring hook is used to spread the wound also in the posterior direction. Without this posterior spring hook the whole bony expo-

sure can migrate too anterior due to the heavy spring hook retraction of the skin. This would then lead to a too anterior intracranial angle of approach. The coronal suture should be about midway through the exposed area. The craniotomy and opening of the dura are performed as described in section 5.2.3.

### 6.6.3. Interhemispheric approach and callosal incision

With the dura open and the cortex exposed, before any brain retraction, it is mandatory to be oriented to the landmarks that lead toward the foramen of Monro. The best guide is an imaginary line drawn from the coronal suture at the midline to the external auditory meatus, the line used in ventriculography to get the catheter inside the third ventricle. It is also important to check the angle of the microscope is in line with the planned approach trajectory.

Upon entering the interhemispheric fissure, bridging veins may obstruct the view, preventing even the slightest retraction of the frontal lobe. The veins are likely to restrict the working area, and one may have to work between them. It may help to dissect some of them for one or two centimeters from the brain surface. Cutting a few small branches may allow safe displacement of the major trunk. One may have to sacrifice a smaller vein, at the risk of venous infarction though. Extensive and long-lasting use of retractors, obstructing the venous flow, may have the same result as severing a bridging vein.

We use water dissection to expose and to expand the interhemispheric fissure for further dissection. Arachnoid membranes and strands are cut sharply by microscissors, which can be also used as a dissector when closed. Use of retractors is kept at a minimum, and they are not routinely used at the beginning of the approach. Instead, bipolar forceps in the right hand and suction in the left, with cottonoids of

different sizes as expanders, are used as micro-retractors. When the interhemispheric fissure is widely opened and the frontal lobe mobilized, the retractor may be used to retain some space but otherwise should be avoided. Rolled cottons, placed inside the interhemispheric fissure at the anterior and the posterior margin of the approach, gently expand the interhemispheric working space and reduce the need for mechanical retractors.

Inside the interhemispheric fissure, after cutting the arachnoid adhesions, dissection is directed along the falx toward the corpus callosum. At the inferior border of the falx, dissection plane is identified between the cingulate gyri attached to each other. The dissection must be continued deeper toward the corpus callosum, identified by its white color and transverse fibers. Mistaking the attached cingulate gyri as the corpus callosum or other paired arteries as the pericallosal arteries lead to serious problems of navigation. After reaching the corpus callosum, the right hemisphere is usually well mobilized and can be gently retracted approximately 15 mm.

Once inside the callosal cistern, both pericallosal arteries are visualized, realizing that they can be on either side of the midline. The right pericallosal artery is dissected and displaced laterally avoiding the damage of the perforating arteries directed laterally to the right hemisphere. Sometimes there can be also crossover branches providing vascular supply to a small area of the medial wall of the contralateral hemisphere. The callosal incision, confined to the anterior third of the body of the corpus callosum, is performed medial to the right sided pericallosal artery but as lateral as possible to preserve the fornix. If hydrocephalus is present, the corpus callosum is thin; otherwise, it can be up to 10 mm thick. With sharp bipolar forceps, an oval callosotomy of less than 10 mm is performed. Its size tends to increase slightly during the later stages of the surgery.



As the callosal transit is completed, formerly, a retractor was placed to prevent collapse of the lateral ventricle. Nowadays, we usually use only bipolar forceps and suction as retractors. Additionally, a thin cottonoid can be inserted into the callosal opening to keep it open, and to protect the pericallosal artery. Inside the lateral ventricle, the foramen of Monro is found by following the choroid plexus and the thalamostriate vein anteriorly and slightly medially towards their convergence point. The antero-medially located septal vein joins the thalamostriate vein at the foramen of Monroe to form the internal cerebral vein, which runs in the roof of the third ventricle. The correct orientation is given by the lateral ventricular veins, which become larger as they approach the foramen of Monro. Opening of a small window in the septum pellucidum is effective to release CSF from the contralateral lateral ventricle. In patients with hydrocephalus, the septum pellucidum is often thin and may have been already perforated by itself.

fill the ventricles with saline and then place a piece of Surgicel followed by fibrin glue into the incision of the corpus callosum.

#### 6.6.4. Colloid cyst removal

First, the part of choroid plexus that is often overlying and eventually even hiding the cyst, is coagulated to expose the cyst. The cyst is then opened with a fine hook or microscissors. The opening is widened with straight microscissors. The contents of the cyst are removed with suction and bipolar forceps. If the cyst consists of more solid material, a small ring forceps can be used for its removal. The remaining contents of the cyst as well as its wall are resected with microscissors. The colloid cyst is usually attached to the roof of the third ventricle and the tela choroidea. This attachment, usually one artery and two veins, has to be coagulated and cut to avoid bleeding from these small vessels. After removal of the cyst, irrigation should be clear, confirming adequate hemostasis. Brain collapse and postoperative subdural hematoma is a potential risk in cases with severe preoperative hydrocephalus. To prevent this, we first

## 6.7. PINEAL REGION LESIONS

Lesions of the pineal region are histopathologically heterogeneous but often accompanied by severe progression of clinical signs. Surgical treatment remains challenging because of the close vicinity of the deep venous system and the mesencephalo-diencephalic structures in this region. Most of the lesions of the pineal region are tumors, either malignant (germinomas, pineoblastomas, anaplastic astrocytomas, ependymomas, teratomas, and ganglioneuroblastomas) or benign (pineocytomas, pineal cysts, and meningiomas). Vascular lesions such as AVMs, cavernomas or Galenic vein malformations comprise only about 10% of the lesions. Unfortunately, MRI is not always reliable in differentiation of malignant pineal region tumors from the benign ones. Some neurosurgeons prefer to take a stereotactic biopsy of a pineal region lesion before deciding to perform a microsurgical operation. In our experience, in most cases, direct surgical treatment can be offered as the first treatment option for pineal tumors. We approach these lesions using the infratentorial supracerebellar route (see section 5.7.), which is safe and effective, associated with low morbidity, a possibility for complete lesion removal, and definitive histopathologic diagnosis. Pineal cysts are operated only if symptomatic, if they increase in size during MRI follow-up, or if neoplastic nature is suspected.

### 6.7.1. General strategy with pineal region surgery

Surgical strategy is planned based on presurgical MRI and CT results. MRI and particularly the study of the deep venous system seem to be the most valuable modality in planning the surgical trajectory and assessing structures in the vicinity of the lesion. In highly vascularized lesions we also use DSA to identify the arterial feeders that need to be handled first during

the approach to keep the bleeding at a minimum. We prefer the paramedian infratentorial supracerebellar approach in sitting position for lesions of the pineal region. The greatest advantages of this approach are: (1) the deep venous system is left intact as the approach trajectory comes from below; (2) the cerebellar veins in the midline are evaded; and (3) gravity creates a gap between the tentorium and the cerebellum without the need for retractors. Our main strategy is to obtain histological diagnosis by open microsurgery, followed by total tumor removal if possible. Some tumors may contain mixed elements so we prefer to take many tumor samples from various parts of the tumor. In benign lesions, complete tumor removal is possible; in malignant lesions, one has to settle for gross total resection. During tumor removal, all the venous structures should be left intact to prevent postoperative venous infarction.

Parinaud's syndrome or diplopia, usually transient, can be seen postoperatively in about 10% of the patients, probably due to manipulation of structures close to the tectum area.

The infratentorial supracerebellar approach can be performed even in situations with obstructive hydrocephalus before the operation. This can be managed either by releasing CSF through the posterior wall of the third ventricle, from the cisterna magna, or through an occipital ventriculostomy. Nowadays, performing endoscopic third ventriculostomy is a good option. However, in our experience, obstructive hydrocephalus can be managed satisfactorily in the same setting as the tumor surgery, in most cases by radical excision of the tumor and opening the posterior third ventricle.

### 6.7.2. Approach and craniotomy

Infratentorial supracerebellar approach in sitting position has been described in detail in section 5.7.

### 6.7.3. Intradural approach

Once the arachnoidal adhesions and possibly some of the bridging veins between the cerebellum and the tentorium have been coagulated and cut, the cerebellum falls down, allowing a good surgical view without brain retraction. Opening of the cisterna magna with removal of CSF improves the surgical view if needed. Along the surgical route are the dorsal mesencephalic cisterns, and their opening releases CSF and provides optimal room for further dissection. At this point, distinguishing the deeply located veins from the dark blue-colored cisterns is crucial. Exposure of the precentral cerebellar vein, and coagulation and cutting of this vein if needed, clears the view; and the vein of Galen and the anatomy below it can be identified. This is the most important part of the operation, but sometimes the thick adhesions associated with chronic irritation of the arachnoid by the tumor makes this dissection step difficult. We usually begin the dissection laterally. After finding the precentral cerebellar vein, we become well oriented towards the anatomy of the pineal region. During further dissection, special care is needed not to damage the posterior choroidal arteries.

### 6.7.4. Lesion removal

The tumor is often covered by a thickened arachnoid and may not be immediately apparent. After careful opening of the arachnoid with microscissors and the bipolar forceps, the tumor is exposed and entered to obtain histological samples. Debulking of the tumor is performed using suction and mechanical action of

the bipolar forceps, which also coagulates the vessels inside the tumor. After debulking, the tumor is dissected free from the surrounding veins, with the help of water dissection. Dissection of the tumor starts from lateral to medial. Eventually, the feeders supplying the tumor from outside are coagulated and cut. The posterior part of the third ventricle is finally opened and CSF removed, giving additional space for better dissection of the rest of the tumor from its surroundings.

The angle below the posterior commissure warrants extreme caution because the slightest bleeding in this area may have fatal consequences. Therefore, even the smallest vessels in this angle should be coagulated and cut, instead of tearing them by manipulating the tumor. Some of the small vessels may be hidden behind the tumor. They may be visualized by mirror or endoscope. A careful hemostasis is of the utmost importance, as even the smallest clot in the third ventricle or the aqueduct may result in acute hydrocephalus.

In malignant and infiltrative tumors, we perform only a subtotal resection. Debulking with suction and bipolar forceps continues until the posterior part of the third ventricle is visualized and entered. The ultrasonic aspirator is seldom used in the pineal region because the working space is small and narrow, and extra-long instruments are needed, especially in the anterior part of the tumor. Recently, new ultrasonic aspirators have been introduced with longer and thinner shafts, which could be also used at the pineal region. If possible, we try to remove the lesion completely.

## 6.8. TUMORS OF THE FOURTH VENTRICLE

Tumors of the fourth ventricle constitute a multitude of different lesions, both benign and malignant. The most common ones are pilocytic astrocytomas, medulloblastomas, ependymomas, hemangioblastomas, and epidermoid tumors. Although these tumors are different from a histopathological point of view and they have different clinical courses, the microsurgical strategy and planning is rather similar. The fourth ventricle tumors nearly always present with posterior fossa mass-syndromes, especially hydrocephalus. Typically, the fourth ventricle is either partially or completely filled with the lesion, and the brainstem is compressed against the clivus. It is not possible to determine accurately whether the lesion is benign or malignant based only on the preoperative MRI images. Therefore the goals of the surgery are twofold: (a) to obtain accurate histological diagnosis of the tumor, and (b) to relieve hydrocephalus and to remove compression on the brainstem. These goals can be usually achieved irrespective of the tumor type.

### 6.8.1. General strategy with fourth ventricle tumors

The presenting symptom for a fourth ventricle tumor is very often hydrocephalus. In patients with decreased level of consciousness, we insert an extraventricular drain (EVD) as an emergency measure to treat the hydrocephalus. The actual tumor surgery is then performed either on the same day or during the next few days. In situations where the patient might need to wait for the surgery for several days, instead of using the EVD, we might opt for a shunt. Unlike with the EVD, with a shunt the patient can wait at an ordinary bed ward. Endoscopic third ventriculostomy may also be considered, but due to the tight posterior fossa, there may be very little room between the clivus and the basilar artery to carry out the procedure safely. In pa-

tients, whose level of consciousness is good, we prefer to operate directly on the tumor without previous CSF diversion procedures. With the tumor removed, normal CSF flow is usually restored. When planning a shunt, it is good to remember that a ventriculo-peritoneal shunt may be a better option in these patients, since ventriculo-atrial shunt is a relative contraindication for surgery in the sitting position, the preferred position for fourth ventricle tumors.

In our experience, the fourth ventricle tumors are best approached using the low posterior fossa midline approach with the patient in sitting position (see section 5.8.). The advantages of this approach are: (1) easy orientation towards the midline; (2) the vermis can be left intact as the fourth ventricle is entered in between the cerebellar tonsils through the foramen of Magendie; (3) by rotating the patient forward, the whole fourth ventricle can be visualized including the opening of the aqueduct; and (4) the risk of manipulating or damaging the anterior wall of the fourth ventricle (i.e. the brain stem) is smaller since one is working mainly tangentially to the fourth ventricle, not perpendicular. Naturally, the advantages have to be weighted against the risks of the sitting position (see section 5.8.).

MRI images give important information for the planning of the resection of a fourth ventricle tumor. The sagittal view is used to determine how high the tumor extends and how much forward tilting will be necessary to reach the most cranial portion of the lesion. The closer the tumor is to the aqueduct the more forward rotation will be necessary. On axial images one should observe how the compressed fourth ventricle is related with respect to the tumor. Is there a CSF plane surrounding the tumor, and if so, from which directions? The other important aspect is the tumor origin or the possible attachment to the surroundings. Sometimes, it

might be possible to pinpoint the actual origin, but in most cases one can only see whether or not the tumor infiltrates cerebellar tissue or the brainstem. Especially in situations with brainstem infiltration, complete removal is unrealistic, carrying a very high risk of extensive neurological deficits with it. In such cases our main aim is to obtain good histological samples and release the mass effect by debulking the tumor. In highly vascularized lesions such as hemangioblastomas, we prefer to do also preoperative CTA or DSA to visualize the course of the main feeders.

The anatomic structures at risk during the approach and the tumor removal are mainly both PICAs and the posterior portion of the brainstem. If the approach is directly in the midline, as planned, the cranial nerves are not encountered. However, careless dissection of the tumor from the brainstem can result in direct damage to the tracts inside the brainstem or the different nuclei. PICAs circle around the brainstem and medulla oblongata to reach its posterior aspect, where cerebellar tonsils often cover them. They turn cranially, pass each other close to the midline and then deviate back laterally. The course of both PICAs should be identified prior to resecting the lateral most portions of the tumor on either side. The PICAs may also provide major feeders to the tumor. The actual PICAs should always be left intact to prevent postoperative cerebellar infarction.

Our general strategy for actual tumor removal goes as follows. With the dural opening at the midline close to the foramen magnum, the cerebellar tonsils are spread and the region of the fourth ventricle is entered. The tumor is partially debulked from inside to provide for more room. The tumor removal then proceeds along its posterior border cranially to reach the tumor free cranial part of the fourth ventricle. Once this has been entered, additional

CSF comes out. The tumor is then dissected free with special attention to the anterior wall of the fourth ventricle, which is kept intact. Whenever possible, we aim for complete tumor removal. Normal CSF flow is generally restored by the tumor removal. Shunts are used only in those patients in whom hydrocephalus remains also postoperatively.

### 6.8.2. Positioning and craniotomy

The positioning and craniotomy for this approach have been described in detail in section 5.8.

### 6.8.3. Intradural dissection towards the fourth ventricle

The dura is opened under the microscope. We use a reversed V-shape flap with the base towards the foramen magnum. Two additional dural cuts can be made in the supero-lateral direction if more room is needed, but the single reversed V-shaped flap is often enough. Several sutures are used to lift the dura and to prevent venous congestion of the superficial veins against the dural edge. The arachnoid is opened as a separate layer and attached by a hemoclip to the dural edge to prevent it from flapping in the operative field. With the arachnoid open, CSF flows out from the cisterna magna. From this point onward, we continue under a high magnification that is maintained throughout the whole tumor removal.

Using water dissection and small cottonoids the cerebellar tonsils are gently spread apart. Arachnoid bands in between the cerebellar tonsils are stretched and cut with microscissors. The aim is to enter into the fourth ventricle through the foramen of Magendie, which in most cases is enlarged and filled with the tumor. Frequently, the tumor can be visualized

already before even spreading the cerebellar tonsils. We do not use retractors routinely in this approach. Instead, to obtain a better view into the fourth ventricle, the entire table is rotated forward. Cottonoid(s) can be placed between the cerebellar tonsils to keep them apart once they have been mobilized. We try to identify both PICAs as soon as possible, so that they can be preserved during the actual tumor removal. The feeders coming from the PICA into the tumor are coagulated and cut under high magnification.

#### 6.8.4. Tumor removal

With the caudal portion of the tumor visualized and before the actual tumor removal starts, we take the first tumor tissue samples for frozen section histological diagnosis. The tissue sample is best taken with a ring forceps. In the same way as with intrinsic tumors in general, we try to take as many samples as possible from different parts of the tumor, since the histology may vary throughout the tumor. After the initial samples, the tumor removal progresses with partial debulking of the tumor. The tumor is entered with blunt bipolar forceps and suction. Under constant and repetitive coagulation, the tumor is reduced from within. Without internal debulking there might be too little room for dissection of the tumor along its edges. It is important to remember that pushing the tumor into the anterior direction compresses also the brainstem, so this should be avoided. Some tumors may contain cystic components, which can be opened to obtain additional room.

Once the tumor has been partially decompressed, the dissection should continue along the borderline of the tumor. A natural dissection plane is identified if present, and this plane is followed utilizing the techniques of water dissection, gentle spreading of the dissection plane with bipolar forceps and sharp dissection of arachnoid and vascular attachments. The

dissection plane is followed as far as possible. It is easiest to start the dissection along the posterior surface of the tumor, since this portion is initially visible. The posterior surface is exposed in the lateral and especially superior direction. The aim is to reach the cranial border of the tumor to gain access towards the superior part of the fourth ventricle and the aqueduct. From here additional CSF can be released. Once the cranial part has been reached, the dissection turns in lateral direction. In case of intrinsic tumors, the tumor often originates from the lateral border on either side. Identification of the imaginary borderline of the tumor may be difficult and one should be very careful not to accidentally enter the brainstem. If possible, we prefer to pull the tumor away from the normal tissue and to resect it along this plane held under tension. Ring forceps may provide better grip on the tumor, since they have larger surface area than bipolar forceps.

In highly vascularized tumors, such as hemangioblastomas, the strategy for tumor removal needs to be a little different. Debulking of the tumor is not a real option as this would only result in serious bleeding. Instead, these tumors should be removed in one piece. The aim is to devascularize them from their major blood supply as soon as possible. This is the reason for the preoperative use of CTA or DSA. With the tumor devascularized, it is then removed either in one or several pieces.

With the majority of the tumor removed, the fourth ventricle can be inspected for tumor remnants. Appropriate table orientation should provide an unobstructed view all the way into the aqueduct. Especially ependymomas can grow also into both foramina of Luschka. They are difficult to visualize from the midline. The tonsils may need to be spread wider and the microscope oriented properly to obtain a sufficient view into the lateral direction. By gently pulling on the tumor, it may be possible to dislocate it into view, even those portions of the tumor that are inside or on the outside of

the foramina of Luschka. In ependymomas one should always try to remove the tumor completely.

Careful hemostasis is carried out along the whole resection cavity, especially at the region of the tumor attachment. With minimal counter pressure, the risk of postoperative bleeding into the ventricle is high. We try to avoid coagulation with bipolar forceps, when the bleeding comes from the anterior surface of the fourth ventricle, and not to damage the brainstem. Instead, hemostatic agent such as TachoSil has proved valuable in this situation. A small piece is placed along the resection bed and gently tamponated with cottonoids. In our experience, it stops the tiny oozing effectively. It also sticks to the wall of the ventricle and does not cause obstruction of the CSF flow.

The dura as well as the other layers are closed in layers in standard fashion. The patient is taken to the ICU. After two to four hours, a control CT scan is performed and if everything looks good, the patient is woken up. In general, there should be no deficits of the lower cranial nerves after this kind of posterior approach. Despite this, we monitor the swallowing function carefully both before and after the extubation.

## 6.9. SPINAL INTRADURAL TUMORS

The most common spinal intradural lesions are schwannomas, meningiomas, neurofibromas, ependymomas, and astrocytomas. In addition, some vascular lesions such as spinal cavernomas, spinal AVMs and spinal dural arteriovenous fistulas (dAVFs) require a very similar microneurosurgical approach. The approach itself as well as the dural incision is almost the same in all of these entities, whereas the actual intradural part of the surgery is tailored according to the pathology. The true challenge of all the intradural spinal lesions is the relatively small size of both the spinal canal as well as the structures inside. There is less room for manipulation and with the narrow approach route, high magnification and high quality microsurgical technique are essential in treating these lesions.

### 6.9.1. General strategy with intradural spinal lesions

Nearly all intradural spinal lesions are approached performing a hemilaminectomy at the appropriate level. Laminectomy is used only in those lesions, where the most important aim of the procedure is decompression of the spinal canal, since the actual pathology cannot be properly removed, e.g. lipomas, or most gliomas. The disadvantage of a hemilaminectomy might be a smaller lateral exposure of the dura on the contralateral side, but with partial resection of the base of the spinous process and appropriate tilting of both the microscope and the table, good visualization of the whole lesion can be obtained.

The most difficult task whenever approaching an intradural spinal lesion is to determine the exact cranio-caudal location of the lesion. Counting the spinous processes by palpation is inaccurate and leads easily to wrong level. Intraoperative fluoroscopy with C-arm is a good

way to determine the appropriate level. Unfortunately, this works only in the cervical and lumbar regions. In the thoracic spine we prefer marking the appropriate level by methylene blue injection before the operation. This is carried out by radiologist in the angio suite. After identification of the targeted spinous process, a needle is placed at the spinous process and a small amount of methylene blue is injected to mark this particular spinous process. The marking should be preferably done on the same day as the planned surgery, since the color has the tendency to spread into the surrounding tissues with time. Intraoperatively, the blue marking on the spinous process is then used for orientation.

In extra-axial tumors (meningiomas, schwannomas or neurofibromas) we aim for complete tumor removal, while leaving the medulla and all the nerve roots intact. In schwannomas the tumor typically originates from one of the dorsal roots, the sensory root. Although we try to save this nerve if possible, in most cases the tumor cannot be dissected free from the nerve and the tumor is removed together with the nerve. Fortunately, this seldom leads to any new deficits. The reason probably is that the affected nerve root has not functioned properly for already some time, and its function has been distributed among the adjacent nerve roots. In spinal meningiomas we aim for complete tumor removal, but we do not remove the dura at the site of the tumor origin. The dural origin is only coagulated with bipolar forceps. In our experience, this policy does not increase the recurrence rate.

In intra-axial spinal tumors the histological nature of the lesion determines our strategy. In ependymomas one might be able to find a borderline, which would allow for the tumor to be separated from the normal tissue. However, most spinal gliomas grow infiltratively without



any proper borderline, so that internal decompression with good histological samples and decompression of the bony spinal canal is all that can be achieved. Lipomas, although clearly defined on preoperative MRI scans, are extremely sticky, almost glue-like when it comes to their removal. They are densely attached to the medulla and the surrounding nerve roots. Some of the nerves may be even embedded inside the tumor tissue. Most lipomas cannot be removed completely without major damage to the surrounding neural tissue. Neurophysiologic monitoring is helpful when operating on intra-axial spinal tumors, sometimes also in extra-axial tumors.

In spinal AVMs and dural AVFs we try to treat the lesion by endovascular means first. If this is unsuccessful, microsurgical removal follows. The aim is similar as for intracranial surgery, to obliterate the pathological vascular structures but to keep the normal vasculature intact. In these lesions we plan for a more cranio-caudal margin of the dural exposure than in tumors. It is important to be able to evaluate the anatomical configuration of the whole lesion already from the beginning. ICG is often helpful when distinguishing the various vessels. The same strategy is applied for all the spinal vascular lesions; we try to remove them completely without disrupting the surrounding neurovascular structures.

### 6.9.2. Positioning

The positioning for spinal intradural lesion varies depending on the level of the lesion. In positioning there are always two aims: (1) to have an optimal working angle; and (2) to keep the operative field well above the heart level with minimal obstruction of the venous flow. The latter point is very important in keeping the intraoperative bleeding at minimum.

For cervical lesions the patient is placed in prone position with the head attached to a head clamp (Figure 3-7 - page 58). The neck is flexed a little forward and the head is elevated above the heart level. The table is placed in anti-Trendelenburg position, and the knees are flexed to prevent the patient from sliding in the caudal direction. Two stiff cushions are placed longitudinally in parallel fashion below the thorax with a 10 cm gap in between. These are meant to decrease the intra-abdominal pressure, help the movement of diaphragm, decrease the ventilation pressure, and increase the venous outflow. The neurosurgeon stands on the side of the patient working from the ipsilateral side of the lesion.

For thoracic and lumbar lesions we prefer to use the kneeling or so-called "praying to Mecca"-position (Figure 3-9 - page 60). The advantage of this position compared to the prone position is, that the operative area can be placed higher than the rest of the body keeping venous pressure lower, resulting in less intraoperative bleeding when compared to the prone position. Old patients with concomitant diseases may not tolerate the kneeling position and normal prone position (without the head clamp) has to be used instead. Also for lesions at the levels of Th I and Th II the prone position may be sufficient. The kneeling positioning starts by placing the patient first in prone position, with the ankles just hanging over the caudal edge of the operating table. Then one person keeps the ankles or knees in place, while two persons lift the upper torso upward and backward. Unless the knees are kept in place during this step, the patient will slide caudally off the table. A specially designed, high, and relatively stiff cushion is placed underneath the sternum to support the whole upper body. The cushion for supporting the upper body should be designed so, that it leaves the belly hanging free, keeping the abdominal pressure low.

In the final position the knees and hips are in line and both are at about 70°–80° angle. A trapeze-like support is placed to hold the buttocks in place. The patient should not be sitting on this support; rather, the body weight should be evenly distributed between the sternum, the knees and the buttocks. Placing the knees in too much flexion prevents venous outflow from the thighs risking venous thrombosis. Side supports are then adjusted to keep the knees from sliding outward. A soft pillow may be placed beneath the ankles to prevent pressure from the table edge. The arms are brought forward and supported with armrests and pillows in such a way that the shoulder blades are neither lifted up, nor hanging. The brachial plexus region should be left without compression. The head can be kept either in a straight neutral position or turned to side. Special head pillows are designed for this purpose, but even a classical doughnut pillow works well. The important thing is to make sure that the neck is not left hanging or over-rotated. An appropriate number of soft pillows is used to achieve optimal head position. With the final head position one needs to confirm that the eyelids are shut and that there is an even pressure distribution on the face. The head is not supposed to carry any extra body weight. Finally, the whole table is tilted in such a way that at the site of the planned approach the back is almost horizontal.

We do not use low molecular weight heparin to prevent venous thrombus during the kneeling position, as seems to be the standard at some other departments. Despite this, the risk of thromboembolic complications has not been any higher in our patients.

### 6.9.3. Approach

With the patient in position, the appropriate level for the approach needs to be identified. For cervical and lumbar spine this can be achieved easily with C-arm fluoroscopy. For thoracic lesions we navigate according to

the previously placed methylene blue mark. A longitudinal incision is planned at the midline. The length of the incision varies depending on the size of the lesion, especially on the cranio-caudal length of the lesion. In small lesions a 2 to 3 cm incision is enough, in larger lesions the length has to be adjusted accordingly. Also the amount of subcutaneous fat affects the approach, in obese patients with a longer distance to the spinal canal, the exposure needs to be somewhat more extensive.

After the skin incision the subcutaneous fat is entered. We prefer to use diathermia for linear and sharp dissection. The wound is spread and kept under tension with a retractor. It is better to carry out a meticulous hemostasis throughout the approach, since this prevents oozing blood from obstructing the operative field. In addition, closing becomes much faster, since less time has to be spent on chasing after all the small bleeding sites. Beneath the subcutaneous fat lie the fascial layer and the spinous processes. Once one or several spinous processes have been identified, the level is again checked with C-arm fluoroscopy, and the approach is adjusted accordingly. In case methylene blue was used, the targeted spinous process is distinguished by the color.

During hemilaminectomy, we open the muscle fascia at the midline on the ipsilateral border of the spinous processes. Then we follow the lateral wall of the spinous process, while stripping the paravertebral muscle attachments with diathermia until the actual vertebral lamina is reached. The lamina is then exposed in the lateral direction to the level of the pedicle. In cranio-caudal direction the exposure is tailored according to the length of the lesion.

One of the challenges in performing a multiple level hemilaminectomy is selecting an optimal retraction system. If the lesion is so small, such that one or two level hemilaminectomy is sufficient, a retractor for microdiscectomy can be used. There are several designs available.

We prefer to use the Caspar microdissection specula retractor set. However, for larger hemilaminectomies we have not yet found an optimal retractor. We use the framed laminectomy retractor, which is very powerful, but unless the retractor blades are placed optimally, the blade at the midline may obstruct the working angle.

Once the appropriate laminae have been exposed, we proceed by performing the bony hemilaminectomy. This is done with a high-speed drill. If the bone is expected to be thin, we start immediately with a diamond tip, otherwise the outer cortex and the cancellous bone can be first removed with round cutting drill before switching to a diamond drill. We leave only a very thin bony shell against the ligamentum flavum. The dura is then exposed by removing the ligament together with the remaining bony shell with a Kerrison rongeur. It is important to extend the exposure also over the midline by drilling away the medio-basal part of the spinous process.

With the dura exposed, the lesion is sometimes already visible through the partially transparent dura. Also in case of DAVFs, one should be able to see the enlarged epidural veins. Before opening the dura, we place Surgicel along the edges of the exposure to prevent venous oozing from the epidural space. The dura is opened in a linear, longitudinal fashion. First, we make a small cut with microscissors to penetrate the dura. Then a blunt microhook is inserted into this opening and pulled both cranially and caudally to open the dura along its longitudinal fibers. The arachnoid is kept intact during this phase. The dura is lifted up with multiple sutures, which are kept under tension. Finally, the arachnoid membrane is opened in the same longitudinal fashion and it can be attached to the dural edge with a hemoclip.

#### 6.9.4. Intradural dissection

The intradural dissection depends entirely on the lesion. A common factor is the use of very high magnification due to the small size of all the structures. Also the suction is usually exchanged for one with a smaller caliber, and sharp bipolar forceps are often used. The lesion removal should be planned so that normal neural structures are manipulated as little as possible. In extra-axial tumors we first devascularize the tumor and then try to separate it from all the surrounding structures before the actual removal. In intra-axial tumors we first debulk the tumor before searching for the possible tumor edge as in ependymomas. All the bleeding points should be taken care of immediately. Even a small amount of blood obscures easily the view down in the deep, and narrow operative field.

#### 6.9.5. Closure

Once the lesion has been removed the dura is closed in one layer. This can be performed either with a running suture (e.g. 6-0 or 7-0 Prolene) or with AnastoClips originally developed for vascular anastomosis. We do not close the arachnoid as a separate layer. The dural closure is further sealed with fibrin glue. Careful hemostasis is carried out in the muscle layer. The muscle fascia is closed in a single layer with dense interrupted sutures. Then subcutaneous layer and skin are closed separately. We do not use drains and there are no restrictions with respect to mobilization.



## 7. NEUROSURGICAL TRAINING, EDUCATION AND RESEARCH IN HELSINKI

### 7.1. NEUROSURGICAL RESIDENCY IN HELSINKI

#### 7.1.1. Residency program

The Neurosurgery Department in Helsinki is the largest unit for training neurosurgeons in Finland, where there are altogether five neurosurgical departments in the whole country, each department associated with university hospitals in different cities. One professor, several associate professors and one assistant professor together with staff neurosurgeons are responsible for training of the residents in a 6-year program. EU recommendations concerning the number of required procedures are followed. All residents have a dedicated mentor representing different fields of neurosurgery changing every 6 months. In addition to 4.5 years of neurosurgery, the residents have to do 3 months of neurology, 3 months of surgery, 9 months of general practice and the remaining 3 months neuroanesthesiology or research. To become a board-certified neurosurgeon one has to pass the national examination making one automatically EU eligible. The so-called EANS-examination at the end of the 4-year EANS training course program is recommended to all residents or young neurosurgeons, but is not compulsory as of now.

List of residents trained during Prof. Hernesniemi's time:

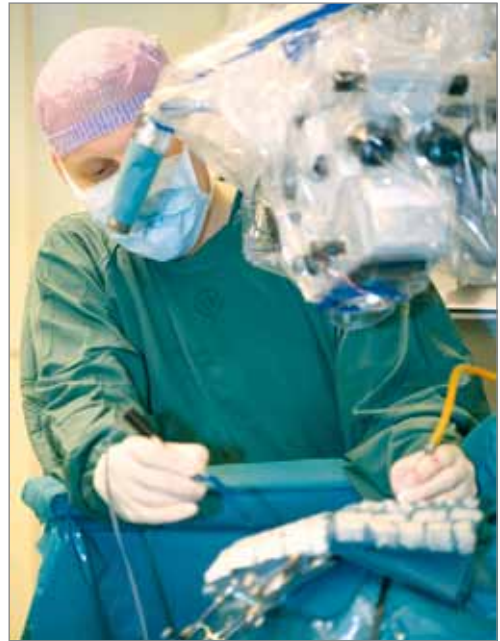Jussi Antinheimo, MD PhD  
 Jari Siironen, MD PhD  
 Atte Karppinen, MD  
 Joona Varis, MD  
 Nzau Munyao, MD  
 Matti Wäänänen, MD  
 Kristjan Väärt, MD  
 Esa-Pekka Pälvimäki, MD PhD  
 Johanna Kuhmonen, MD PhD  
 Minna Oinas, MD PhD  
 Martin Lehecka, MD PhD  
 Riku Kivisaari, MD PhD  
 Aki Laakso, MD PhD  
 Emmanouil Chavredakis, MD  
 Miikka Korja, MD PhD

*Academic dissertation of Dr. Martin Lehecka (right), with Prof. Robert F. Spetzler, as the opponent (left), and Prof. Juha Hernesniemi, as the supervisor (center).*

### 7.1.2. How to become a neurosurgeon in Helsinki – the resident years

by *Aki Laakso*

It is actually quite hard to tell why anybody would want to be a neurosurgeon. Almost every day you put yourself willingly, even eagerly, into situations where your performance may dictate the quality of life – or even the difference between life and no life – for another human being. When I look at my colleagues here in Helsinki, I see an extremely wide variety of different human personalities – everything from a quiet, unassuming philosophical type to extroverted, flashy connoisseurs of extreme sports. What is common, however, is that everybody seems to love what he or she is doing.



*Dr. Aki Laakso*

My path leading to a neurosurgical residency was probably not a typical one. I was rather old, 32 years, when I started my training, and had spent years doing research after medical school. The field of my research was always neuroscience, but it was still something that seemed light-years away from drilling holes into other people's heads. I have the greatest admiration for science and scientists, and should a thing or two in my life have happened differently, I might still get my daily dose of playing with neurons in the lab instead of in the operating room. In 2003, I nevertheless made the decision to put my medical school education into use and become a physician again.

So, why neurosurgery? I sometimes like to answer with a story of a poll in which a large number of American women were asked to vote for the sexiest profession a man can have. Racecar drivers turned out to be the hottest guys, while brain surgeons came second on the

list. Since I am too tall to fit in a Formula one car, I had no choice but... (Although heard by many, the story itself must be an urban legend, since nobody in the States gives a hoot about Formula One races, and I find it very hard to believe that many American girls would consider NASCAR drivers that desirable...) The real answer for me, however, is twofold: the human brain and the consciousness arising within it being the greatest mysteries of the modern-day biology (and the brain is pretty much the only organ I find interesting enough to devote my career to – who would call a kidney or a gut as "great mysteries of nature", even if they indeed are small miracles of evolution?); and my desire to train myself in a profession where I can accomplish something meaningful using manual skills and knowledge that only few people in the society have.

When I begun my residency, my previous experience in clinical medicine came from two disciplines that are very different from neuro-

surgery: psychiatry and neurology. What unites all three, however, is that they all are about treating people's brains. For my generation, the 6-year neurosurgical residency in Finland consisted of 4.5 years of neurosurgery, a total of one year of neurology and some other surgical discipline than neurosurgery combined, and six months of general practice in a municipal health care center (the reason for that one having everything to do with social politics and nothing with the training itself). Many people asked me in the beginning how I dare to start a neurosurgical residency without any previous surgical experience, and did not hide their skepticism when I told them that I do not share their concerns, and feel that some knowledge on clinical neurology will probably be way more important and useful than a know-how to remove appendices. Today, after completing my residency, which also included three months of plastic surgery (which, for the record, was a quite useful period), I still feel the same way. The neurosurgical procedures, especially the ones you perform early during your training, are so different from anything you would learn in any other surgical specialty, that I still do not consider it mandatory in any way to try and get a lot of experience in some other surgical discipline before starting the neurosurgical residency. However, the basic knowledge and understanding of neurological signs, symptoms and diseases was a tremendous help, at least for me.

A typical day of a resident in the department starts around 7.45 AM with ward rounds with a senior staff neurosurgeon and nurses. Since the current number of doctors usually allows for two to three seniors and residents in each ward, the resident rarely has to be responsible for more than a dozen of patients. The paperwork is usually the residents' chore, but its volume is easily manageable (which may be difficult to believe if you look at the piles of unfinished patient files some of us have been able to create at some point of our junior careers!). Rounds are quick and efficient (compared to 3-4 hour

rounds many of us has suffered at neurological departments), and there's usually time for the morning's first cup of coffee between them and the radiology meeting which starts at 8.30 AM. The radiology meetings, where all imaging studies done during the previous day are reviewed together, are incredibly educational and even entertaining occasions. Looking at the results of your own operation with the audience of your colleagues can lead to an emotional state of deep satisfaction and reward - or bitter self-torture and humiliation; both of these extremes serve to make you a better surgeon. Sometimes the debate about a certain case may get heated, and especially younger residents do wisely when they remember Dr. Pentti Kotilainen's words: "A good resident has big ears and a small mouth"!

Around nine o'clock or so, people start to dissipate to their daily activities. Many go to the operating room, but maybe twice a month a poor resident has to face the most feared assignment of them all: the outpatient clinic. If it happens to be the "resident outpatient clinic", consisting of mostly trauma and shunt patient follow-up visits with no first-time patients coming for consultation, one can congratulate him- or herself, since the day will likely be short and rather pleasant. All too often, however, the unlucky resident finds himself substituting for a senior staff member, facing a horde of patients with bilateral acoustic schwannomas, diffusely growing low-grade gliomas, brain stem cavernomas, malfunctioning deep brain stimulators, failed lumbar spine fusions and spinal arteriovenous fistulas. I guess this will remain a problem as long as the waiting list for the outpatient clinic will be two to three months like it is now, and the absence of a senior neurosurgeon cannot always be taken into account when the patients are given the appointments. Naturally, the seniors will help and consult with difficult patients, but many times the situation is frustrating for both the resident and the patient.

Luckily, even after two or three days of outpatients, the resident still has twenty days of good and happy stuff each month: operations. Each resident who has been chosen for training will have a senior mentor, changing in six-month cycles. The resident may and should assist his mentor in all operations, which usually means a great front-row seat to see all the action: all of our microscopes are equipped with high-quality assistant eyepieces, enabling the neurosurgeon and the assistant to share the same magnified view. The sense of depth is not comparable to what you get through the primary eyepieces, but the views are still superb. Following 7-8 different seniors during your residency gives you a great armament of tricks and tips to build your own surgical technique and style upon. The mentor will also be the first one to consult with your own cases, and, if necessary, will back you up in the OR should you need guidance or help.

Yes, I mentioned own cases. No law in Finland forbids a surgical resident to operate independently. Once you have learned a certain procedure well enough, taught by seniors or more experienced residents, it is common for residents to operate on their own – even during the night when the resident on call may be alone in the hospital. I personally liked this a lot, and I believe others have liked it as well. It teaches you responsibility, ability to make decisions independently, and builds stamina, or "sisu", when you cannot immediately hand over the instruments to someone more experienced at each small obstacle. This is not to say that the department's policy is to put patients at unnecessary risk or to let inexperienced residents to do whatever silly thing they think might be "a great idea". There is a strong spirit that favors an extremely low threshold for consulting someone more experienced, day or night. If you end up doing a stupid mistake without consulting anybody, you can rely on receiving prompt feedback for that. If you feel that the senior is not giving you a straight answer, or refuses to

scrub in to help you in the operation, it is probably because he or she knows your limits, trusts you in that given situation (even if yourself do not), and wants to encourage you to think and act independently. A great deal of hands-on teaching of surgical tricks, especially during early phase of residency, comes also from the experienced scrub nurses. Our OR nurses are dedicated professionals assisting only in neurosurgical operations, some of them with decades of experience, and having closely watched thousands of operations. A smart resident should display utmost respect for them, and listen closely to valuable tips they have to offer. The same truth applies also to our experienced nurses in neurosurgical ICU and bed wards – their "clinical eye" often easily outperforms that of a young resident: please listen to what they have to say and learn!

The number and diversity of operations one can perform during the resident years depends obviously a lot on the resident him- or herself, but the total number of operations will easily reach several hundreds. During the first half of residency, you will probably learn shunt operations, traumatic brain injury cases, and some simpler spine and tumor operations. During the second half, your repertoire probably extends to more difficult gliomas, small meningiomas, a few posterior fossa craniotomies, more sophisticated spinal surgery (though most likely not extensive instrumentations), maybe some spinal tumors. And of course you gain generally more experience, more cases, all leading to better results, more elegant surgical technique, faster operations, improved self-confidence... until you encounter your first really bad complication, and immediately feel miserable and rewound back to the starting point. Luckily, if – or, rather, when – that happens, the colleagues are very supportive, and from their own experience understand that there is no room for accusations and cynicism, but constructive re-evaluation of the case and circumstances is probably desirable.



A significant proportion of operative experience during one's residency comes during on-call shifts, which usually take place two or three times a month (the on-calls are shared by eight residents and three or four youngest specialists). On-calls may be really quiet, or you may end up answering dozens of phone calls, doing seven operations and struggling to find a two-minute break for taking a leak. The on-calls are not really scary, though, even for less experienced young residents. You will always have a senior backing you up, just a phone call away, an anesthesiologist will be on-call with you just for neurosurgical patients, and the nursing staff is usually experienced and helpful as well. You have probably also been "the daytime on-call resident" for a few times before doing nighttime on-calls, which gives you the opportunity to train being on-call safely, with all your colleagues around you to help.

tinuous presence of visitors from abroad and other Finnish university departments ensures that the "household ways of doing things" are all the time susceptible to fresh influence, critical observation and different points of view. And, if you are inclined to doing research, you will get a lot of support for that, too.

You cannot become a good neurosurgeon just by operating without building a strong theoretical background knowledge as well. All residents trained in Helsinki will attend the four-year cycle of EANS (European Association of Neurosurgical Societies) training courses, and many younger residents not yet eligible for EANS courses go to Beitostølen courses organized by the Scandinavian Neurosurgical Society. The Finnish Neurosurgical Society will also organize an annual two-day course for all Finnish residents. The department has a weekly meeting schedule, and more likely than not, you will give a talk there yourself a few times if you enter the residency program. And of course you have to read. And, finally, when you will take the final exam to get your board certification, you will have to read *a lot*.

All in all, I think I can honestly say that Helsinki has been a great place to spend my resident years. The atmosphere in the department is really friendly and supportive, and the large catchment area for patients ensures a steady flow of rare cases, as well as vast numbers of patients with more common pathologies. Con-

## 7.2. ACADEMIC AND RESEARCH TRAINING

### 7.2.1. PhD program

In Helsinki and Finland, there is a long tradition of completing a PhD thesis before, during or after a residency program. Nowadays, it consists of 3–4 papers in international peer-reviewed journals, some 200 hours of classes passed, together with writing and defending a PhD thesis summary. The topic can be of basic or clinical research or both combined. Of the 16 neurosurgeons in Helsinki, 13 have an MD PhD degree. One fourth of the Finnish physicians are MD PhDs. Typically, a post-doctoral period is spent in research or clinical practice in some recognized lab or department of neurosurgery outside Finland to broaden the horizons and obtain special skills to be brought back home.



*Dr. Johan Marjamaa*

### 7.2.2. Making of a PhD thesis in Helsinki, my experience

*by Johan Marjamaa*

In Finland it is common for a medical doctor to make a PhD thesis; at Helsinki University 65% of all MDs do it. In order to be able to aspire for a good position at the university hospital, I also felt that it was necessary to make one. As a fourth year medical student I was not yet quite sure about my field of interest, but I immediately got very excited when I heard that the Neurosurgery Research Group was recruiting new members. Without hesitation, I updated my CV, wrote a detailed application and sent it to Professor Juha Jääskeläinen, who was the group leader at that time (before becoming the Chairman of Neurosurgery Department in Kuopio). To this date I don't know by which

criterion I was chosen, but later I have heard that there were several other applicants. Also a younger medical student, Riikka Tulamo, was recruited. At that time the group consisted of Professors Juha Jääskeläinen and Juha Hernesniemi, Doctors Mika Niemelä and Marko Kangasniemi and PhD students Juhana Frösen and Anna Piippo.

After six months we were assigned our own projects. Riikka was helping Juhana in studying inflammation in aneurysm wall samples collected by Prof. Hernesniemi at surgery. Riikka's special interest became complement activation in the aneurysm wall. My project became to

further develop endovascular treatment methods in our newly established aneurysm model in rats and to improve MR-imaging methods of experimental aneurysms. I was thrilled at the project, since it gave me the chance to start to learn microsurgical skills in addition to learning scientific approach and thinking as well as manuscript writing, statistics and other scientific methods.

The title of my thesis was to become "*Microsurgical aneurysm model in Rats and Mice: Development of endovascular treatment and optimization of magnetic resonance imaging*". During the years I made more than one hundred microanastomoses and performed coiling of the experimental aneurysms which were then followed up with a 4.7 Tesla MR-scanner for lab animals.

Technically speaking, for the PhD, one needs to complete three to four manuscripts about the subject. The thesis book consists of a literature review, a presentation and discussion of one's own results, as well as reprints of the manuscripts. Moreover one needs to participate in courses on research methods and attend meetings as well as present own results. The project usually equals five years of fulltime work. The thesis book is finally reviewed and commented on by two reviewers, who are professors specialized in the topic. In the end there is a public defense where the PhD student defends his thesis against the opponent, a respected professor who more often than not comes from abroad. The celebration party after the defense, in honour of the opponent, is called "Karonkka". This important and often anticipated part of the project is seldom cancelled since very few doctoral dissertations are any longer rejected at the time of the defense.

Since I was simultaneously studying and working in the clinic for most of the time, it took me six years to complete my PhD thesis. During the first two years I was still a medical student, so at that time I could do research only during

evenings and weekends. But, since the medical faculty highly appreciates research among students, also Wednesday afternoons were always dedicated for this purpose. The work did not delay my studies, although it is quite common that students take time off from medical school if they are doing research simultaneously.

The facilities in the lab at Biomedicum Helsinki are excellent, the lab is in the hospital campus area and it was always possible to drop in even for a shorter time. Collaboration with other groups is easy because of good connections and an open-minded atmosphere, but also since the facilities are designed in an unenclosed way with open lab spaces and plentiful meeting rooms and social areas. Since it was common that the days were long and the experiments were finished late in the night, good accommodation is necessary. Affordable, rather new apartments (with saunas!) for PhD students were conveniently located at walking distance from the campus area and Biomedicum.

After my graduation I worked full time for one year in the lab. The funding in the Neurosurgery Research Group was exceptionally well arranged. Most PhD students in other groups did not receive any salary from the group, but had to rely on small personal scholarships. In January 2006 I started as a resident at the Helsinki Neurosurgery Department. As a member of the research group I had also already become familiar with most of the staff at the department. During the next three years I worked in the department but was at the same time doing research. The department encourages research and made it possible for me to take 1-2 months off every year for my project.

Finally after six years, in May 2009, came the day I had anxiously been waiting for, the day of the dissertation and Karonkka. After finishing the actual scientific work, I could never imagine how much there still was to do during the last months before the dissertation. All the administrative work, the printing of the book,

the reprinting of the book, the organizing of the Karonkka party and, of course, the preparation of my talk and the defense. The evening before was scheduled for minor preparations, but I ended up decorating the Karonkka-party venue until late in the night. The dissertation itself remains in my mind as a rather pleasant experience. My opponent Professor Fady Charbel did an excellent work in commenting my results and discussing the subject as well as future goals with me. I am honoured by how relevantly he was prepared. The dissertation was attended by my family, friends as well as hospital staff and collaborators from the lab. The Karonkka party was held in a nice atmosphere and great weather, and only one guest was taken to the emergency room, only to make good recovery.

I have been privileged to work in the Helsinki Neurosurgery Department and Research Group in many ways. The international atmosphere with hundreds of visitors every year is very inspiring and at a very early stage I was given the opportunity to travel to international meetings to present my results. In those meetings I did not need to be nervous since I had already been discussing my work with many influential professors visiting the department back home. In addition to reputable professors, Helsinki was and is also visited by many young promising neurosurgeons from all over the world. I believe it is a valuable asset to meet and discuss with colleagues who are more or less in the same stage of training as yourself.

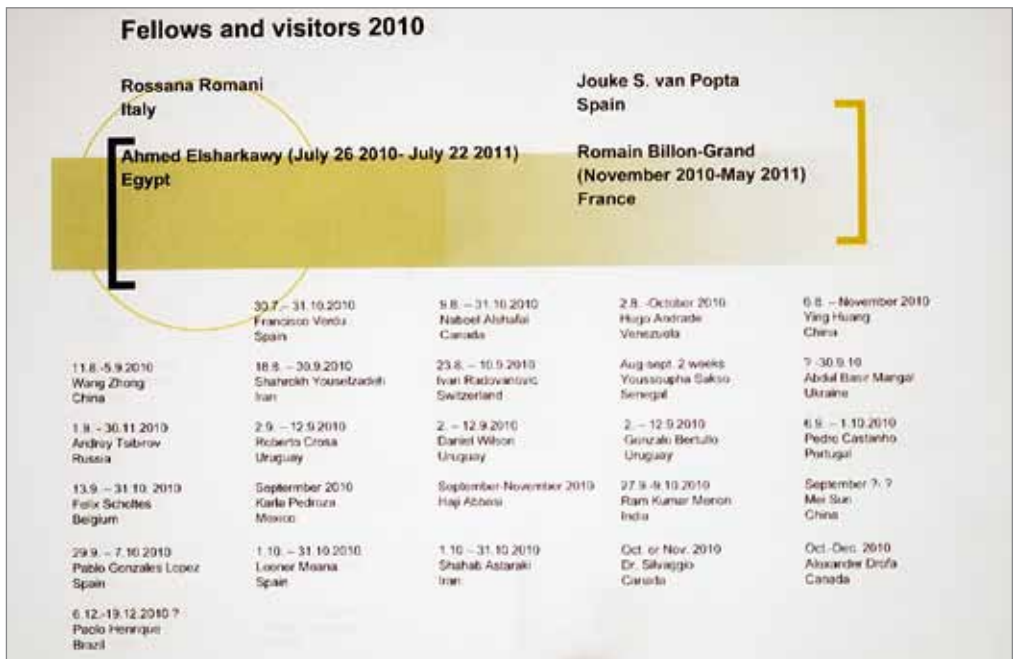

Figure 7-3. List of international fellows and visitors from August 2010.

### 7.3. MICRONEUROSURGICAL FELLOWSHIP WITH PROFESSOR HERNESNIEMI

Fellowships are available with Prof. Hernesniemi to learn microneurosurgical techniques and/or to do scientific work. It is recommended to make a short one-week visit to be introduced and see the department before being accepted as a fellow. From 2010 on, an Aesculap Hernesniemi Fellowship of 6 months was founded and will be announced twice a year in *Acta Neurochirurgica* and *Neurosurgery*. Also shorter visits (one week to three months) are possible, and in fact they are the most usual ones. Funding for shorter visits should be arranged from the home country. Around 150 neurosurgeons from all over the world visit the Department of Neurosurgery annually. Most neurosurgeons trained in Helsinki during Prof. Hernesniemi's time have also spent a year as his fellow after completing their residency.

List of Prof. Hernesniemi's fellows:

Romain Billon-Grand 2010-  
 Ahmed Elsharkawy 2010-  
 Miikka Korja 2010-  
 Bernhard Thome Sabbak 2010  
 Hideki Oka 2010  
 Aki Laakso 2009-2010  
 Jouke van Popta 2009-  
 Mansoor Foroughi 2009  
 Martin Lehečka 2008-2009  
 Puchong Isarakul 2008  
 Riku Kivisaari 2007-2008  
 Stefano Toninelli 2007-2008  
 Özgür Celik 2007- 2008  
 Ondrej Navratil 2007- 2008  
 Rossana Romani 2007-  
 Christian N. Ramsey III 2007  
 Esa-Pekka Pälvimäki 2006-2007  
 Ana Maria Millan Corada 2007  
 Baki Albayrak 2006-2007  
 Kraisri Chantra 2005 and 2006  
 Rafael Sillero 2006  
 Reza Dashti 2005-2007  
 José Peláez 2005-2006  
 Ayse Karatas 2004-2005  
 Keisuke Ishii 2003-2004  
 Minoru Fujiki 2002-2003  
 Joonas Varis 2002  
 Jari Siironen 2001  
 Mika Niemelä 2000 and 2003  
 Hu Shen 1998-2000  
 Avula Chakrawarthy 1999  
 Munyao Nzau 1999  
 Leena Kivipelto 1998

#### 7.4. MEDICAL STUDENTS

Each fall 120 new medical students begin their studies at Helsinki University (founded in 1640 as The Royal Academy of Turku and moved to the new capital Helsinki in 1828 after the city of Turku was destroyed in The Great Fire). During their fourth year of studies they come to the Department of Neurosurgery, divided into smaller groups, for one week of training in basics of neurosurgery. Each student attends 20 hours of teaching by senior neurosurgeons at the wards, ICU and ORs. In addition, several medical students each year write a thesis for their MD degree on a neurosurgical topic. These students are supervised by senior neurosurgeons of the Department.

#### 7.5. INTERNATIONAL VISITORS

Helsinki Neurosurgery is a very international training unit, having had altogether 1500 visitors from all over the world for shorter or longer (fellows) periods since 1997 from all over the world. At the same time, most neurosurgeons from Helsinki have visited, done scientific or clinical work at top units abroad.

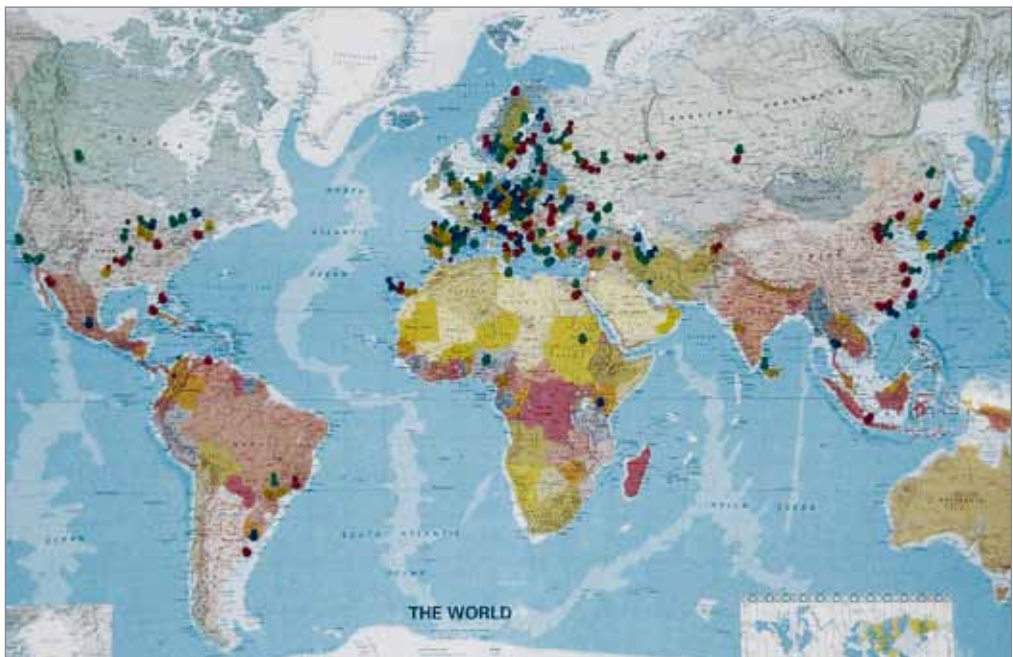

Figure 7-4. World map in the OR lobby with pins showing hometowns of many visitors to the Department.

## Some prestigious visitors:

M. Gazi Yaşargil, Zürich, Switzerland, and Little Rock, AR, USA  
 Dianne Yaşargil, Zürich, Switzerland, and Little Rock, AR, USA  
 Ossama Al-Mefty, Little Rock, AR, USA  
 Toomas Asser, Tartu, Estonia  
 James I. Ausman, Los Angeles, CA, USA  
 Peter M. Black, Boston, MA, USA  
 Fady Charbel, Chicago, IL, USA  
 Vinko Dolenc, Ljubljana, Slovenia  
 Shalva S. Eliava, Moscow, Russia  
 Ling Feng, Beijing, China  
 Robert Friedlander, Boston, MA, USA  
 Askin Gorgulu, Isparta, Turkey  
 Guido Guglielmi, Rome, Italy  
 Murat Gunel, New Haven, CT, USA  
 Jan Hillmann, Linköping, Sweden  
 Akihiko Hino, Shiga, Japan  
 Egidijus Jarzemskaš, Vilnius, Lithuania  
 Yasuhiko Kaku, Gifu, Japan  
 Mehmet Y. Kaynar, Istanbul, Turkey  
 Farid Kazemi, Teheran, Iran  
 Günther Kleinpeter, Vienna, Austria  
 Hidenori Kobayashi, Oita, Japan  
 Thomas Kretschmer, Oldenburg, Germany  
 Alexander N. Konovalov, Moscow, Russia  
 Ali F. Krisht, Little Rock, AR, USA  
 David J. Langer, New York, NY, USA  
 Jacques Morcos, Miami, FL, USA  
 Jacques Moret, Paris, France  
 Michael K. Morgan, Sydney, Australia  
 Evandro de Oliveira, São Paulo, Brazil  
 David Pitskhelauri, Moscow, Russia  
 Ion A. Poeta, Iasi, Romania  
 Luca Regli, Utrecht, The Netherlands  
 Duke S. Samson, Dallas, TX, USA  
 Hirotooshi Sano, Toyooka, Japan  
 Peter Schmiedek, Mannheim, Germany  
 Renato Scienza, Padova, Italy  
 R.P. Sengupta, Newcastle, UK, and Kolkata, India  
 Robert F. Spetzler, Phoenix, AZ, USA  
 Juraj Steno, Bratislava, Slovakia  
 Mikael Svensson, Stockholm, Sweden  
 Rokuya Tanikawa, Abashiri, Japan  
 Claudius Thomé, Mannheim, Germany  
 Nicolas de Tribolet, Geneva, Switzerland  
 Cornelius A.F. Tulleken, Utrecht, The Netherlands  
 Uğur Türe, Istanbul, Turkey  
 Dmitry Usachev, Moscow, Russia  
 Peter Vajkoczy, Berlin, Germany  
 Anton Valavanis, Zürich, Switzerland  
 Bryce Weir, Chicago, IL, USA  
 Manfred Westphal, Hamburg, Germany  
 Peter Winkler, Munich, Germany  
 Sergey Yakovlev, Moscow, Russia  
 Yasuhiro Yonekawa, Zürich, Switzerland  
 Grigore Zapuhlii, Chisinau, Moldova

## 7.6. INTERNATIONAL LIVE SURGERY COURSES

### 7.6.1. Helsinki Live Course

The annual Helsinki Live Demonstration Course in Live Microneurosurgery, or shortly just the Helsinki Live Course, has become the signature course of Helsinki Neurosurgery over the past decade. The course was held for the first time in 2001 and has been continuing on yearly basis ever since. The infrastructure, logistics and program content have been evolving all the time, but the original idea still remains; to demonstrate complex neurosurgical live operations performed by true masters. The participants have the privilege to observe not only the actual procedure, but also all the preparation, discussion, planning, as well as the postoperative treatment, while interacting with the whole team treating the patient. The neurosurgeons are ready to share their opinions and thought process behind realization of even the most complex surgeries. At the same time the course offers laid-back interaction between neurosurgeons coming to Helsinki from all around the world.

Each year, during the first week(s) of June about 50–70 neurosurgeons come to Helsinki for the Live Course. They travel here to see Pro-

fessor Hernesniemi along with his staff and the international faculty to tackle 20–30 complex neurosurgical cases such as aneurysms, AVMs, cavernomas, intrinsic and extrinsic brain tumors, bypasses or spinal tumors. During the first three years (2001–2003) the course participants were fortunate to observe the seamless co-operation between Prof. Yaşargil and Ms. Diane Yaşargil while performing excellent microneurosurgical operations. During the later courses the international faculty has included such prominent neurosurgeons as Vinko Dolenc (Slovenia), Ugur Türe (Turkey), Ali Krisht (USA), Fady Charbell (USA), Rokuya Tanikawa (Japan) and others, all of them performing state of the art neurosurgical operations and discussing about their surgeries with the participants.

The earlier versions of the Helsinki Live Course lasted for two weeks; nowadays, due to better infrastructure and organization the course has been shortened to 6 days. The first day consists of lectures on topics related to microneurosurgery and different intracranial and intraspinal pathologies. During the subsequent five days there are 6–8 live neurosurgical cases operated each day simultaneously in three ORs. Each of the cases is presented with all the appropriate imaging studies and after that some of the participants watch the surgery directly inside the OR while others follow live image on screen in the lobby of the OR together with commenting and explanations from the faculty members. In addition, there are short lectures or videos between the live cases. The operative schedule runs every day from 8 AM to approximately 6 PM.

In 2010 the Helsinki Live course celebrated its 10th anniversary. The course has been organized in collaboration with Aesculap Academy since 2003. Further information on the upcoming courses can be found at [www.aesculap-academy.fi](http://www.aesculap-academy.fi).

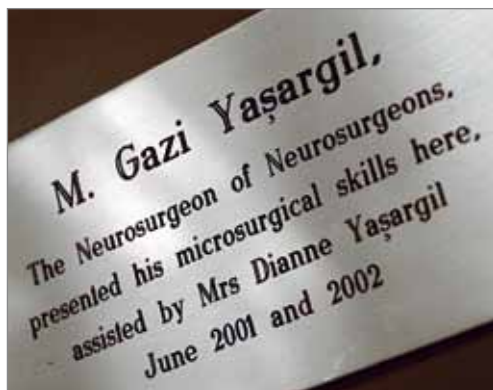


Figure 7-5. Prof. Yaşargil operated on the Helsinki Live Course during the years 2001–2003.



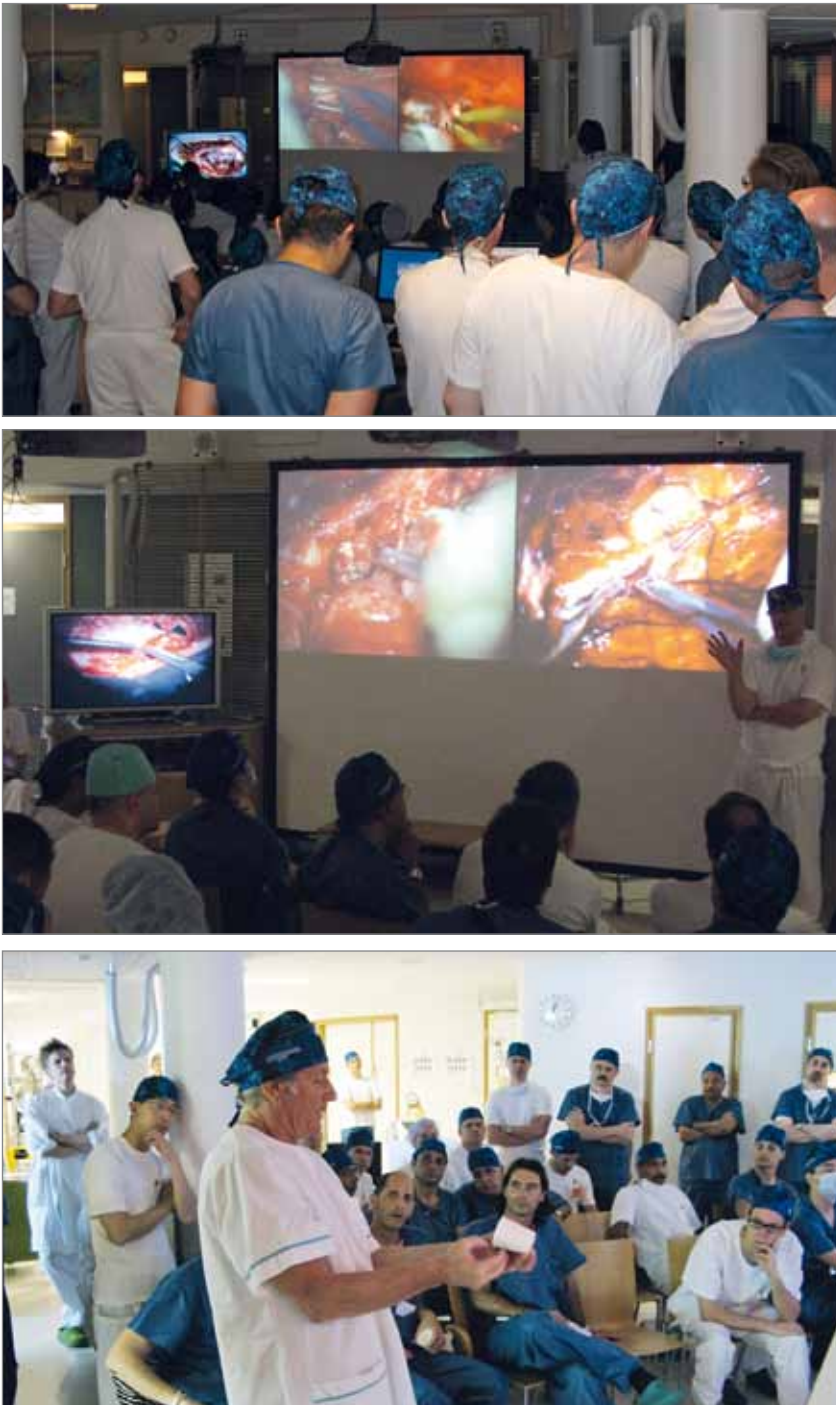

Figure 7-6. (a) Participants of the Helsinki Live Course are observing three simultaneous procedures in the OR lobby. (b) Prof. Juha Hernesniemi commenting on surgery he just finished. (c) Prof. Vinko Dolenc is explaining his approach for the next case.

### 7.6.2. LINNC-ACINR course (Organized by J. Moret and C. Islak)

The first Live Interventional Neuroradiology and Neurosurgery Course (LINNC) was held in 2007. It evolved from the earlier Live Interventional Neuroradiology Course (LINC) held every second year in Paris, when the chairman of the organizing committee, Prof. Jaques Moret, came up with the idea of involving both endovascular surgeons and neurosurgeons in the same live demonstration course. Thus LINNC 2007 was formed, combining live neuroradiological intervention from Paris and live surgeries from Helsinki, all being viewed by nearly 800 participants at the Carrousel du Louvre in Paris, France. Over the years the LINNC course has become the benchmark in live demonstration neurovascular courses in the world. Every year at the end of May nearly 900 participants, both neurosurgeons and neurointerventionalists gather together for three days of lectures and, more importantly, observation and discussion of neurovascular cases treated live in front of their eyes by experts from Helsinki, Paris and lately also Istanbul and Ankara. Since 2009 LINNC has become a joined meeting with the Anatolian Course in Interventional Neuroradiology (ACINR).

During the three course days the OR in Helsinki is transformed into a TV studio with cameras, monitors and cables filling all the empty space. Each day three to four live surgeries are performed in two ORs and broadcasted via satellite to the lecture hall in Paris. The surgeries are different vascular cases such as aneurysms, AVMs, cavernomas and bypasses. Each operation is presented with live commentary on the strategy, microanatomy and various techniques employed during the surgery by faculty members both in Helsinki and at the course venue.

The ambience in the OR during the course days resembles that of a World Cup game with a lot of anticipation, hectic time schedule and joy out of good results. Success comes only through involvement of the whole department where, apart from the direct work in the OR, there has to be seamless co-operation also with ICU and the wards to carry out all the tasks in a very tight time frame.

The LINNC-ACINR course is organized by Europa Organisation. More information on the upcoming courses can be found at [www.linnc-acinr.com](http://www.linnc-acinr.com).

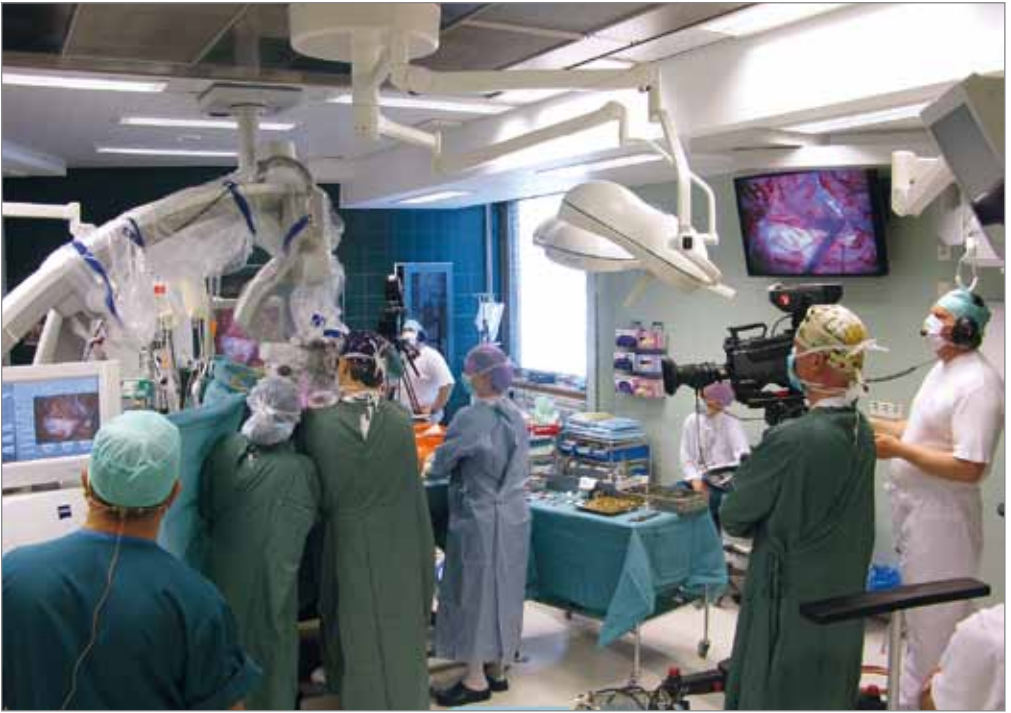

Figure 7-7. (a) Camera setup inside the OR during the LINNC course 2009. (b) Dr. Martin Lehecka (left) directing the satellite broadcast to Paris in a temporary TV control room built in one of the storage rooms of the OR.

## 7.7. PUBLICATION ACTIVITY

Over the last few years about 35 scientific papers have come out every year from the department focusing on molecular biology and operative techniques on aneurysms and natural history of AVMs. Earlier, clinical series of hemangioblastomas, schwannomas and meningiomas were published in collaboration with pathologists and molecular geneticists. The WHO classification of meningiomas is based on Helsinki series. Also, risk factors for SAH and natural course of unruptured aneurysms have been studied with many classical papers published. There is also an increasing activity on basic and clinical research on functional neurosurgery as well as some research on spine surgery, as well as on cavernomas and dural AV fistulas.

During the past few years, the annual number of articles from the Department published in international peer-reviewed journals has doubled:

2010: 32	2004: 17	1998: 14
2009: 30	2002: 13	1997: 13
2008: 28	2001: 19	2003: 12
2007: 31	2000: 21	
2005: 16	1999: 18	

In the Appendix 1 of this book, we have collected a reference list of recent articles focusing on microneurosurgical and neuroanesthesiological techniques and principles.

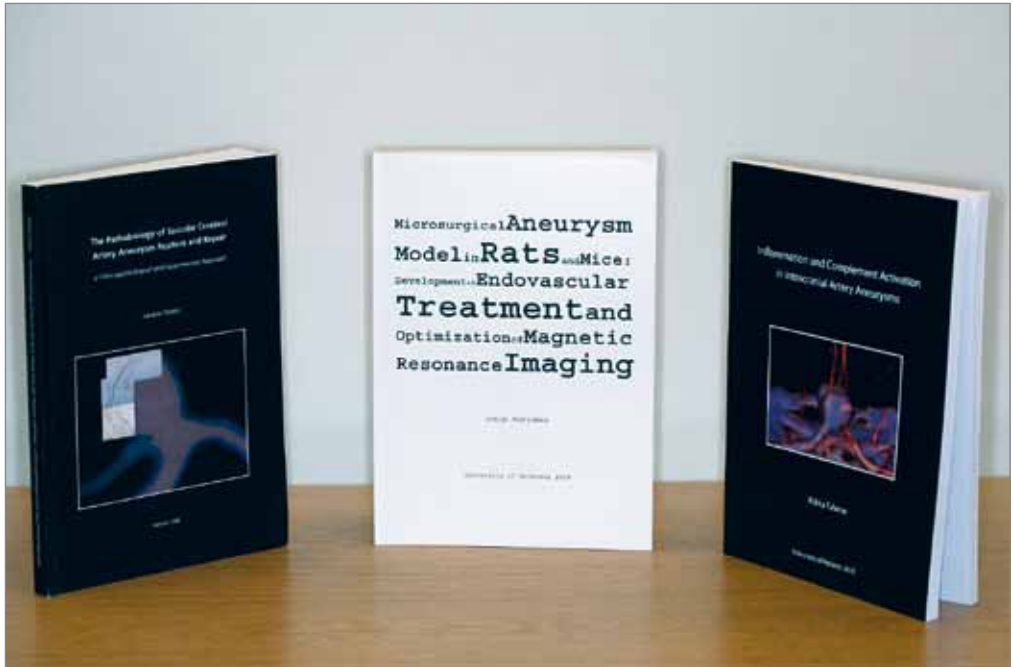


Figure 7-8. Doctoral theses from the Biomedicum aneurysm research group from 2006-2010.

## 7.8. RESEARCH GROUPS AT HELSINKI NEUROSURGERY

### 7.8.1. Biomedicum group for research on cerebral aneurysm wall

The Department of Neurosurgery at Helsinki University Central Hospital is one of the largest neurovascular centers in the world treating about 500 patients a year with cerebral aneurysms, AVMs, cavernomas and dural AV fistulas. The department has published several classic papers in aneurysm and SAH literature concerning e.g. risk factors of SAH and timing of aneurysm surgery, as well as imaging of cerebral aneurysms. With a busy clinic with a lot of clinical research behind us, we now have a great opportunity to try to find answers to some clinical problems, utilizing basic research conducted in Biomedicum. Our research group in Biomedicum was established in 2001 and has grown over the years having now four senior scientists, four research fellows and eight PhD students. The group has studied the snap-frozen fundi of cerebral aneurysms resected after microsurgical clipping. We have shown that before rupture, the wall of a saccular cerebral artery aneurysm undergoes morphological changes associated with remodeling of the aneurysm wall. Some of these changes, like smooth muscle cell proliferation and macrophage infiltration, likely reflect ongoing repair attempts that could be enhanced with pharmacological therapy. Our group investigates the role of inflammation as possible causes of cerebral aneurysms. We collaborate with Yale Genetics & Neurosurgery to identify the aneurysm gene among familial aneurysm patients treated in Helsinki and Kuopio, Finland, and The Netherlands, Japan and Germany (see [www.fiacr.fi](http://www.fiacr.fi)). We also have an experimental aneurysm model to study occlusion of aneurysms by endovascular means with the possibility to use 4.7T MRA to compare the findings with histology. The ultimate goal is to develop more efficient ways to occlude the neck of an aneurysm completely by endovascular means.

So far, three PhD thesis have been completed from the lab group:

- Juhana Frösen, MD PhD: "The pathobiology of saccular cerebral artery aneurysm rupture and repair - a clinicopathological and experimental approach" in 2006, discussed with Prof. Robert Friedlander, Harvard Medical School.
- Johan Marjamaa, MD PhD: "Microsurgical aneurysms model in rats and mice: development of endovascular treatment and optimization of magnetic resonance imaging" in 2009, discussed with Prof. Fady Charbel, University of Illinois at Chicago.
- Riikka Tulamo, MD PhD: "Inflammation and complement activation in intracranial artery aneurysms" in 2010, discussed with Prof. Peter Vajkoczy, University of Berlin.

### 7.8.2. Translational functional neurosurgery group

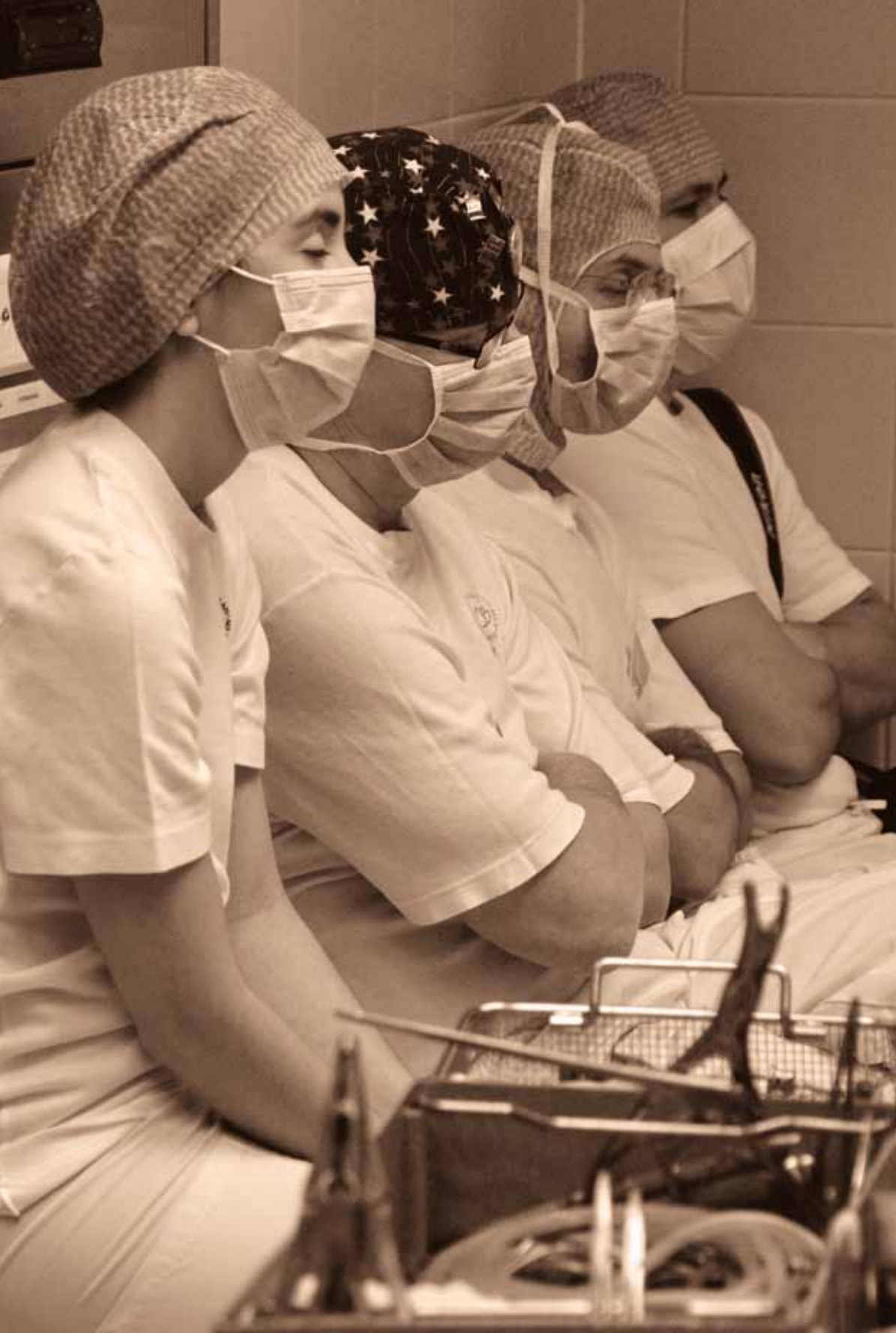A significant number of people are suffering from medically intractable pain or neurological and neuropsychiatric disorders resistant to conventional treatments. Functional neurosurgery offers clinical methods of relieving severe forms of some of these disorders. The most common current methods used are epidural medullary stimulation, deep brain stimulation, cortical stimulation, and vagus nerve stimulation. Even though these methods are shown to be clinically effective and their use is increasingly widespread, the mechanisms of action are not well understood and the choice of targets is not uniform. Our group focuses on studying neuromodulation of clinically significant disease models and targets in preclinical models. The aim is to increase understanding of the mechanisms of neuromodulation and to provide hypotheses for clinical studies. The main interests are experimental models of movement disorders, obsessive-compulsive disorder and depression and the neural targets used in the neuromodulatory treatment of these disorders.

### 7.8.3. Helsinki Cerebral Aneurysm Research (HeCARE) group

This group studying clinical aspects on cerebral aneurysms was established in 2010 with five senior scientists and six students. The group is focused on subarachnoid hemorrhage, cerebral aneurysms and their treatment. This includes comprehensive pro- and retrospective analysis of all aneurysm patients treated at the Department of Neurosurgery. The data is collected from the Helsinki Aneurysm Database that currently includes 9000 patients, treated since 1932 at the department. Our database includes information from all patient files and radiological imaging studies.



Figure 7-9. Helsinki Aneurysm Database in the making. (a) Drs. Riku Kivisaari and Hanna Lehto analyzing old angiographies from past decades. (b) The reality of performing clinical research.






## 8. VISITING HELSINKI NEUROSURGERY

In this chapter we present memories of some of the visitors and fellows who have spent longer or shorter periods of time in Helsinki. These texts are meant to provide useful information and practical details for those neurosurgeons planning to visit Helsinki in the future.

### 8.1. TWO YEAR FELLOWSHIP – JOUKE S. VAN POPTA (ZARAGOZA, SPAIN)

#### 8.1.1. Why to do a fellowship?

Why to do a fellowship in neurosurgery? I guess there may be several different reasons and it may well be that it is different for everyone, but of course I can only speak for myself. Fellowship means a period of medical training after a residency. I received adequate and practical neurosurgical training in The Netherlands and when I came to work in Spain I was eager and very motivated to put all that I had learned into practice. After an organizational change in my department I got more surgical responsibilities and that is why I decided to apply for a fellowship. Further improving my surgical skills and learning new surgical techniques would not only benefit myself but also my department and of course, most important of all, the patients.



*Dr. Jouke S. van Popta*

### 8.1.2. In search of a fellowship

I have a genuine interest in neurovascular surgery, and there is still need and future for "open" cerebrovascular surgery, also in the community where I work. After having decided to apply for a fellowship, I asked myself where would I go? I wanted a department known for its neurovascular surgery, where I could see a high number of operative cases, and where I would feel myself, if possible, also comfortable. There were several options on my list and I decided to check them all out and to take a look before making a definite decision and commitment. One of the options was the neurosurgical department of Professor Juha Hernesniemi at the Helsinki University Central Hospital.

### 8.1.3. Checking it out

I knew the name "Hernesniemi" from the book by Drake et al., *"Surgery of Vertebrobasilar Aneurysms"* that I saw when I was a resident. I met him for the first time during a congress and I went to listen to all his lectures and presentations. I was not only very impressed by what I heard and saw, but I also had a good feeling about the man himself. I checked Helsinki Neurosurgery out by going to the 2008 Live Course. At the end of the first day I already felt that "this was the place" for me to be and after a few weeks I made the definite decision. My acceptance was confirmed in a letter stating I was "cordially invited for a cerebrovascular fellowship for a 6 months period" starting in January 2008. Since that moment I have never looked back! And needless to say that the other options on my list were of no importance anymore!

### 8.1.4. Arrival in Helsinki

The last weeks before my fellowship were quite hectic doing my daily work and meanwhile preparing and organizing everything for my stay in Finland. An apartment nearby the hospital was available but up to only a few days before my arrival I still did not know where it was or how I could get in. I began to worry. I pictured myself arriving late at night with a delayed flight in Helsinki, standing with my luggage in the freezing cold, temperatures low beyond imagination, heavy snow storm raging, no public transport, walking over icy roads and through dark deserted streets, with no apartment to go to and all the hotels closed. But a last minute emergency e-mail and great secretarial help brought an end to all of these worries and a couple of days later I arrived safely and on time in the early afternoon at Vantaa airport and within an hour or so I was sitting comfortably in a warm apartment. It felt good!

### 8.1.5. The very first day

On the first day Juha Hernesniemi took me for a round through the OR complex, the ICU's and the patient bed wards. After a (very early) lunch we sat in the lobby of the OR and he asked me about my neurosurgical background, and my professional and personal interests. He explained to me the structure and the content of the fellowship, and he stressed the importance of observation "which is severely underestimated in neurosurgery", (the importance of) the books of Yaşargil and Sugita, the knowledge of neuroanatomy from the practical neurosurgical point of view, to be able to visualize the whole operation first "in your own mind", to practice (and practice and practice), to watch and edit videos of operations, the power of repeating and of course the absolute necessity to operate everything (everything) with the microscope. In all the weeks and months I came to spend with him in the OR, slowly and bit-by-bit, I started

to understand and could clearly see and experience for myself in all of his surgeries how true this all was and is. Often I think back on that moment and every time I realize that basically he told me everything that there was to tell on that very first day!

#### 8.1.6. A day in the life (of a fellow)

I arrive just before 8 o'clock in the morning in the hospital. I change into my surgical clothing and then I go to OR 1. I check the operation program. Next I will select the images of the patient from the radiological workstation and put the patient data into the memory of the microscope. I check the microscope, the video recording equipment, the video screens and monitors, OR lamps and the lamp camera. After intubation we start with the positioning of the patient. Assisting here is needed, obligatory and extremely important! The sterile surgical field is prepared and I will take a last quick look at the screens and lights. Then we scrub, take our positions and off we go!

The number of surgeries varies but on average Hernesniemi will operate three cases a day and when he is on call it will probably be even more. Between surgeries I make notes of the operations and write them down in my notebooks. At the end of the day we will look at the surgical cases of the next day, discuss the images and the surgical techniques involved. At home I will study and read. I made a study program for myself although sometimes it has been difficult to stick to it because these days in the life of a fellow are long and winding, but at the end always good!

#### 8.1.7. Assisting in surgery

Assisting in surgery is not easy, although it may seem so. Juha Hernesniemi is the fastest surgeon I have ever seen and that is why assisting him is even more demanding. So you better become quick and swift yourself! But is also the best and fastest way to learn because it keeps you on your "surgical toes" so to speak! During the operation I concentrate on the real



Figure 8-2.

live neurosurgical anatomy which is unfolding before my eyes, on his surgical technique and I try to predict his next surgical move. When not looking through the side tube of the microscope I prefer to stand to his right side in a somewhat postero-lateral position so I can simultaneously see him, the scrub nurse (and not be in her way!) and the video screens. His surgeries are of the highest level and that is why he needs all the support and should be as comfortable as possible.

### 8.1.8. Nurses

These surgeries could not be performed and their high level not maintained without the assistance of the OR nurses of the neurosurgical department. I have been to and seen neurosurgical departments around the world but I have never seen better OR nurses than here in the Helsinki department. Professor H. may not

be the easiest person in surgery (he will be the first to acknowledge that), but even in the most difficult cases their professionalism and support stands out for everyone to see. This also holds true for the nurses of the anesthesiological department: their work seems less visible from our surgical point of view but that does not mean that it is less important!

### 8.1.9. Anesthesiologists

When I was a medical student I did a project in anesthesiology so at an "early medical age" I came to see the whole operation theatre from the anesthesiological side of the stage. Anesthesiologists and surgeons should form a team, because they cannot work without each other. High-level neurosurgery of course demands and requires high-level neuroanesthesiology. Without a doubt, this is given and cared for, in the OR and in the ICU's, by the anesthesi-

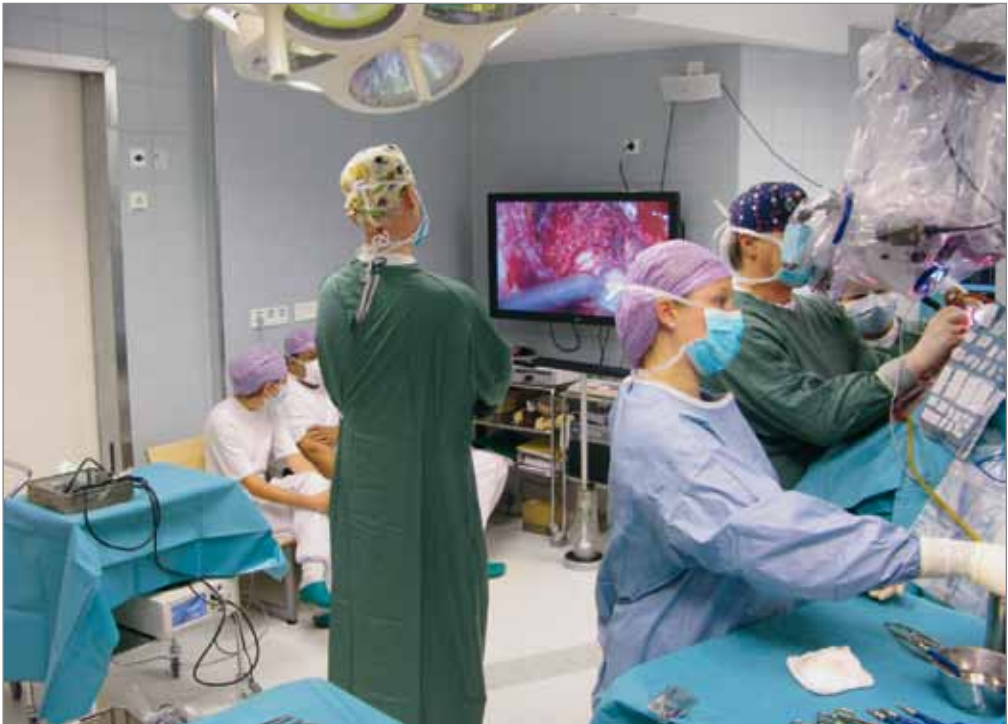

Figure 8-3.

ologists here in the neurosurgical department of HUCH. About their techniques and tricks is written elsewhere in this book, so read it and invite your own (neuro)anesthesiologists to come and visit!

#### 8.1.10. Music in the OR

Hernesniemi operates with the radio on. He prefers a certain channel with the music on a certain volume. I very much love music and that is why in the beginning I was pretty much disturbed by this radio although I tried hard not to pay attention to it. But there is a reason for the radio. It provides some kind of background music or "muzak" and this, I admit, works rather well. Without it the OR would be far too silent and serious music would make the ambience indeed too serious, which of course does not mean that we are not serious during surgery! These radio channels tend to repeat the play-

lists of their songs so after more than one year I believe that I have heard them all, and some of them have even become favourites by now!

#### 8.1.11. Rounds

Every week Hernesniemi will do the rounds with his fellows and visitors. Sometimes we skip one week (or two), but that is because of heavy operating schedule. He will take us first to the ICU's and the patient wards where we will see the patients who were operated upon and we discuss their clinical evolution. If there are new visitors, we extend the round to visit the neuroradiological angio suite, and we will make a stop to see the plaque in honor and memory of Mannerheim, who founded the hospital, and the portraits of Snellman and af Björkesten, the first pioneering neurosurgeons in Finland. I like these rounds very much and it reminds me that doctors care for patients and that we



Figure 8-4. The monument of Jean Sibelius near Töölö Hospital.



Figure 8-5.

work for them. Hernesniemi will also tell about the history of the hospital and the neurosurgical department, which in a way is also his own history. There are many good stories being told, so lend him your ear and take a listen!

#### 8.1.12. Visitors

Juha Hernesniemi believes in an open-door policy. That means that everyone is (cordially) welcome in his department to come and take a look and that there are no secrets in relation to the surgeries and the surgical techniques. The excellence of his surgeries is known throughout the world and that is why visitors from all around the globe come to visit his department. All of them are different regarding their background, culture, experience, etc., and they form a colourful group from humble and shy medical students to well known neurosurgeons in the field. There is much to tell about these visitors, but the majority of them are polite, interested, and respectful. There are also exceptions of course, but that is a different story!

#### 8.1.13. Pins and their stories

That the visitors indeed come from all around the world is something you can see for yourself when you take a look at the big world map near the lobby of the OR complex. Every visitor is kindly asked to place a coloured pin in the map that corresponds with the city where she or he is working. Europe, the United States of America and also Japan are very well represented. Sometimes I look at the map and I wonder what their stories are, because in a way every pin has a life and a story of that life attached to it. Some pins stand out for being the only pin in a certain country and I call these the "lonely pins". They almost always represent a colleague

from a far away country who took the effort (and sometimes had to make the necessary financial sacrifice) to come all the way to visit the neurosurgical department in Helsinki. Visitors are also asked to write something about their stay in the guestbook, and there you will find many interesting commentaries, also from many famous neurosurgeons!

#### 8.1.14. LINNC and Live Course

The LINNC and the Helsinki Live Course are very special and important events in the year for the department. They also mean a big logistical, organizational and surgical stress for all involved, so we have to be at our best! During the LINNC Hernesniemi performs live neurovascular operations which are linked by satellite to an important endovascular congress elsewhere. During the Live Course 40 to 60 neurosurgeons from all around the world come to Helsinki to see and watch during one week Hernesniemi perform a high number of neurovascular operations and operations of skull base and cerebral tumors. Also invited are well known neurosurgeons from abroad who will also perform, at the same time in different OR's, special operations for which they have become known. All these operations are projected onto video screens inside and outside the OR's and recorded. All the surgical interventions are pre- and postoperatively discussed and explained by all the participating surgeons, so you can learn a lot! This amazing course had me glued to my chair every day when I came to see it for the first time. The Live Course is also a good opportunity to meet and contact other colleagues; there is a very nice course dinner, and an intriguingly interesting party in the evening of the last day (there is no excuse for not attending!).

the many sunny days it seems as if almost all

### 8.1.15. Weather and the four seasons

When one thinks of the weather in Finland maybe the first associations which come to mind would be snow and ice, very low temperatures, long and dark winters, and short summers. The winter seems certainly long and dark, and although the average temperatures may be lower than you might have wished for, you get used to it. Finns say that there is no bad weather, only wrong clothes. The snow makes for a beautiful sight in the streets and parks, and Helsinki life is not in the least disturbed by it. The sea is frozen and you can walk on it, which seems so strange that it may be difficult to believe or imagine. Spring is amazing, when nature starts to open up and blossom in just over two weeks time. Summer is relatively short but very nice. The temperatures are very agreeable (not too cold, not too warm) and on

in Helsinki are in the streets and on the terraces enjoying the sunny weather. Another good reason to take a look! Autumn is very beautiful, especially because of the changing of the colour of the leaves. A curious experience is the delusion of time sense, which occurs in the winter and the summer. During the darkest months December and January it feels like late in the evening when it is only still early in the afternoon, and in June and July, when the days are long and the nights are short, you tend to wake up automatically very early in the morning.



Figure 8-6.



### 8.1.16. Apartments

My apartment is small, but nice and clean, and most important, it is quiet, and so it is good for studying, reading and resting. It has become my home for the time being. I spend almost all of my time in the hospital or in my apartment and maybe that seems abnormal but I decided for myself to dedicate as much time as possible to my fellowship. I know myself well enough to realize that I also need to disconnect from the work and that is why I prefer to take some time off during the weekend and do something different not related to neurosurgery. I have another apartment, my real home, and I kept it on purpose. It is important once in a while to go back home and be in your own environment again and reconnect with your friends and family.

### 8.1.17. Helsinki

I like Helsinki very much! The city is surrounded by the sea, which makes it very special. It is clean and quiet, there are many green spaces like parks and trees, and the people are really nice. If you consult a good travel guide you will see that the city has a lot to offer and you will surely find many things of interest and to your liking.

Helsinki, because of its size, it is also an ideal place for walking, for example around the Töölönlahti, downtown along the Esplanadi to Kauppatori, or through the Kaivopuisto park and along the seaside. Take a walk and see for yourself!

### 8.1.18. Finnish food

As I spend a lot of time in the hospital I also take my meals in the hospital restaurant. The food is excellent with a great variety of soups, salads, meat, fish, vegetables, pastas, rice, desserts and bread. I cannot read the Finnish menu but I have never been disappointed! And when I have some difficulties with certain combinations I take a look at someone's plate and that usually tells me what to do. Especially recommended is the blueberry pie! Take a bite!

### 8.1.19. Languages

Finnish is considered to be a very difficult language and that, even for those with a gift for languages, it takes two or more years to be able to speak and understand it fluently. In the hospital everyone speaks English so learning Finnish is not a requisite to do a fellowship in this department. I nevertheless made a list of names of the surgical instruments (that was kindly translated for me), so in the OR I am



Figure 8-7.

able to communicate also in Finnish during the go too fast". He also stresses the importance

operations. Finland is bilingual (Swedish being the other official language) and with a combination of German and English it is not impossible, within a given context, to understand the Swedish words. In Finland you will not be lost in translation!

#### 8.1.20. Famous words

They say that Finnish people are not so talkative, but what does this mean? Not so talkative, compared to whom or what? Compared to your own culture, to your own people, or to yourself?

Is there some standard that dictates how many words you should say or speak in a given time period, or use in a sentence or during a conversation? Maybe someone who is not so talkative only *seems* to be so, or has really nothing to say *at that moment*, or knows that it is just *not the right moment* to say something or to speak, or communicates in a *different way* that you maybe don't know or understand. Here are some famous words and expressions *spoken* by an equally famous Finn: "*no niin*", "*which side?*", "*where is the aneurysm?*", "*which kind of tumor?*", "*pää nousee*", "*pää laskee*", "*pöytä nousee*", "*pöytä laskee*", "*light is not good*", "*tight! tight!, it is not tight!*", "*good trick!*", "*oh, my goodness!*", "*you're left handed?!*", "*terrible!*", "*which year?*", "*good case!*", "*this is important!*", "*we could manage!*".

#### 8.1.21. Practice, practice, practice

Hernesniemi told me that during microneurosurgical operations it is very important "to concentrate", "to isolate yourself", "to go step-by-step" (like reading the story in a comic book image-by-image), and "not to try to want to

of practicing because microneurosurgical skills have to be learned and trained. In the rear of the OR complex is a microscope for practicing which also has a mouthpiece attached to it. I started with suturing gloves, every time with finer sutures and under a higher magnification, and gradually for longer periods of time. There is also a model that is used for practicing bypass surgery and in the supermarket I bought some chicken parts, took the vessels and started suturing and "bypassing". Professional musicians practice their instruments, and there is probably no end to practicing. Maybe (neuro) surgeons should do the same?

#### 8.1.22. Video editing

All of Hernesniemi's operations are recorded on the microscope and on high-definition videotapes. You can watch these tapes as many times as you like (there are no surgical secrets, remember?), download and/or edit them for your own use (on condition of anonymity of the patient data, of course). Video editing forms a part my study program and I make my own personal archive of his operations that I can consult in the future for my own work.

#### 8.1.23. The surgery of Juha Hernesniemi

This book is about the surgery and the surgical techniques of Juha Hernesniemi. In a way his surgeries speak for themselves, but of course there is so much more to tell and write about it, and that is done elsewhere in this book, far more eloquently and better than I could ever do. To watch him operate is a truly unforgettable experience and the excellence of his surgeries is unparalleled. This was acknowledged *publicly*, for everyone to hear and read, by a world famous leading neurosurgeon who came

to visit the department. To me it is not only his

surgical technique, but also his great experience, his positive attitude, his unbreakable forward fighting spirit, and the *human* that makes him unique. And that is why I consider him to be the best!

#### 8.1.24. The choice of a fellowship

The success of a fellowship depends for a large part on ones own attitude, but of course the department where you actually will realize your fellowship is even so important, especially if you plan to stay for a longer period of time. My decision to come to the neurosurgical department of HUCH was not only a "cerebral" decision, but also a decision of the heart. The high number of neurovascular and tumor operations, the excellence of the surgeries, the open-door policy, the genuine feeling that you are welcome and the willingness of everyone (yes, everyone) to listen and explain, makes this department the perfect place to come to learn and an obvious choice for a fellowship. So come and take a look!

*Table 8-1. Key elements of the Helsinki fellowship*

- Observation of surgeries
- Assisting
- Closing (under the microscope)
- Discussions (pre- and postoperatively)
- Rounds (ICU and bed wards)
- Reading (library in the OR lobby, with textbooks and journals)
- Preparation of scientific papers and presentations
- Video editing
- Practicing of microsurgical skills under microscope

## 8.2. ADAPTING TO FINNISH CULTURE AND SOCIETY – ROSSANA ROMANI (ROME, ITALY)

*"Consider your origin: you were not born to live like brutes, but to follow virtue and knowledge"*  
(Dante: *The Divine Comedy, Inferno, Canto XXVI, lines 118-120*)

One of my esteemed Italian colleagues, who was working in Florence, advised me to go to see Prof. Hernesniemi because, he said: "He is the best". I visited Professor Hernesniemi for the first time for a period of two weeks, in August 2006. I was very impressed by him, as well as by his staff and I decided to interrupt my work in Italy and to come to Finland in June 2007 to learn microneurosurgery.

### 8.2.1. The difference between "to talk the talk" and "to walk the walk"

When I arrived, I spent almost two months training under the microscope and in the beginning it was difficult. I was very slow and awkward but after a few months I became better and faster. I also studied the basic neurosurgical books recommended by Professor Hernesniemi. Also, knowledge of the Finnish language made it easier for me, from the beginning, to understand in a faster way several of the microsurgical steps and the use of the surgical instruments. However, to understand Hernesniemi's surgical style one needs time and knowledge, and only after assisting in many cases you realize what he is doing, and how well-thought his microneurosurgical techniques are. We record all operative videos and we edit most of them.



Dr. Rossana Romani

Professor Hernesniemi has been very nice to me and supported me - but at the same time very demanding. If I was not a hard worker with good results I would not have been able to remain so long time. During my stay I have assisted him in 1182 cases (677 vascular cases, 426 tumors and 79 others) and learned the anatomy. I have made a personal file of my whole experience here, and this is an experience I can always refer to and take a look in the future. I have edited numerous videos for our publications, and by doing that, learnt a lot. To watch and edit operative videos is the modern way to learn microneurosurgical techniques, better than any neurosurgical book. When you are young, you have to "steal and store" your experience. I had also the chance to operate one patient with two aneurysms.

Being close to Finns all the time I learned to listen. It is difficult to know, which of the few words said by Professor Hernesniemi are teaching, and which are not. Many times he says: "I'm teaching you". Finnish attitude is very educative and teaches how to work in an efficient way without losing time in useless small talk. Many times I heard Prof. Hernesniemi to say: "It is different to talk the talk than to walk the walk". In Italy we say: "Between saying and doing there is a sea".

Finnish neurosurgeons are efficient. They do not lose time talking about what they have to do because they know very well what to do and they just do it. They can do the rounds, have a meeting, perform surgeries and research, all of that between 7 AM and 3 PM, and after that they relax with their families or hobbies. Everything is perfectly organized and it works.

In the OR nurses are doing their job in an excellent way. Only the essential instruments are displayed and for all intracranial lesions (vascular or neoplastic) the instrument set is almost the same. The most impressive is to see how all staff work together and even in difficult operations nobody loses control.

Besides the microneurosurgical activity and the microscope training there is another important work: the paperwork! Professor Hernesniemi is speaking of his own experience: "If you don't publish you perish!" You can be the best neurosurgeon in the world but without publications and scientific papers nobody will know you, and you will not have the power needed to make changes and improvements in your local neurosurgical community. Scientific paperwork is demanding and it requires a lot of time besides the surgical activity, but on the other hand it increases your knowledge. "Behind all aneurysms lies the truth", Professor Da Pian, a former chairman of the neurosurgical department in Verona, once said, and I would

paraphrase his words as follows: "Behind every scientific paper lies the truth". When you study a topic of which you know everything, the weak as well as the strong points, you begin to realize that your contribution can improve the knowledge available to the scientific community. When I arrived, Professor asked me to rewrite some papers and after that I started to review all the meningioma cases. Professor is one the best not only in cerebrovascular surgery but also in tumor surgery, especially in meningiomas. Contrary to vascular cases, which, in many neurosurgical departments, especially in Italy, are an exclusive area of the chairman of the department, meningioma surgeries are performed by a large number of neurosurgeons, and this was the reason why I became interested in them.

I learned how to do a scientific paper, from the collection of the data to the discussion, and I have prepared many successful publications (more than 20) and book chapters (more than 6), not only on meningiomas but also on vascular surgery. I'm having a great opportunity to work here and to learn from Professor Hernesniemi.

In Italy I was not happy about what I was learning, especially in terms of microneurosurgical techniques. Many young Italian scientists, researchers and doctors go abroad to work and many never come back.

The initial plan was to stay one year doing a cerebrovascular fellowship, but during my stay I worked so hard and I got good results that I was offered the opportunity to prepare the PhD thesis. I'm now actually involved in the process of writing it and day by day I'm getting a different "forma mentis", a different state of mind, "the Finnish attitude to work".



Figure 8-9. Tower of the Helsinki Olympic Stadium

### 8.2.2. Difficult to learn but good for life: The Finnish language

When you grow up in a country where you study Latin at school and where you study only languages originating from Latin you think that all European languages are based on Latin - but this was small Italian thinking. Finnish is just Finnish coming from... Finnish.

Many neurosurgeons visiting Helsinki Neurosurgery, and coming from all over the world, were very impressed by my knowledge of Finnish. Almost all of them asked me: "Why did you study Finnish? Do you want to live here all your life? Do you have a Finnish boyfriend?" In their questions they were looking for a reasonable explanation why someone would undertake the study of such a difficult language.

I didn't study Finnish because of the handsome Finnish male; at least not in the beginning when I didn't know that the most beautiful neurosurgeon in the world was Finnish. I studied Finnish because I was interested, since the beginning, in Finnish culture and Finnish people. And to know people, to bond with them and their culture you have to speak their own language.

When you see written Finnish for the first time, you think that somebody, seated at the computer keyboard, wrote a random mixture of characters. The most difficult is to understand where one word ends and the next one begins. Before studying Finnish I thought that German with four cases and a logical construction of grammar and syntax was the most difficult European language, but compared to Finnish, it was an easy language to learn. Finnish language has 15 cases and no prepositions or articles, making the construction of sentences a challenge.

I asked my Finnish friend whom I met in Florence before coming to Finland, how to translate "buonanotte" and she answered, smiling: "It is very difficult to pronounce", and continued: "Finnish is very difficult, almost impossible to learn". That was incredibly true and to say "hyvää yötä" - that means "buonanotte" - was extremely difficult because you have to speak and breathe at the same time. Italian language is spoken in the lips, Finnish in the throat.

But the problem of the Finnish language is that after going to the language school at Helsinki University, after many courses and sacrifices, I realized that the language you need in your daily work is altogether another language. The spoken language is different from the official one studied at school, and this completely destroys you.

To study Finnish is like to run a marathon or to climb a mountain ...you should not give up. Finnish is a rich and beautiful language and it is not impossible to learn. If I did, everybody can.

Studying Finnish completely changed my life in Helsinki, in Finland and in the OR. This is because when you speak to Finns, especially in the beginning, in their own language they feel happy and they like you despite your poor English or your whimsical Latin temperament. I will never forget my first Pikkujoulu (a Christmas party where there is much alcohol and happiness), when one of the OR nurses told me: "We like you very much". In vino veritas and I was very happy because that was true.

Many times I changed the rules. If I would be in my neurosurgical department in Italy and

a foreign neurosurgeon would be visiting the department, I would be very happy to hear my own language especially if it had been very difficult to learn for him or her. When you learn a language you discover a new world, because you can live close to the people and share a life with them, and this is something that no books or pictures can give you.

### 8.2.3. When in Finland do as the Finns

My first week in Finland was terrible because I was alone in a new culture and a new country. I lived my first month in Helsinki with a Finnish family, and after a while, I became their fourth daughter. Thanks to them and their support I learned all Finnish habits very fast. Everything was different from my Italian culture, but "different" does not mean worse. You cannot compare a Mozart symphony or a Raffaello painting with a beautiful flower or with a summer sunset. Beauty has different faces. A Roman proverb says: "When in Rome do as the Romans" (Sant Ambrose, 387 A.D.), and this was what I did in Finland.

I discovered Finland as a beautiful country. Living with my Finnish family allowed me, since the beginning, to go to a summer cottage where you live in the middle of nature. I had a sauna close to the lake and I thought to myself, how lucky Finnish people are to be delighted by such beautiful scenery. I took a bath in the sauna and I went for a swim in the lake. I celebrated Juhannus, the astronomical midsummer, the shortest night of year, with my Finnish family and friends in their cottage. I realized that in Finland there is a great respect for nature and animals. In the countryside, immersed in nature, I could understand the Finnish attitude much better.

If you come from a country with several million inhabitants and you are used to talk everywhere with everybody, you will note a completely different world in Finland. The Finnish concept of

politeness is different compared to most other countries. Especially in Italy, it is considered polite to communicate. In Finland it is polite to leave people alone. This explains why they are so quiet and silent everywhere. This aspect of Finnish culture impressed me very much. I had never before been in a silent crowded tram and never studied in the same room with ten nurses talking to each other. This is impossible to experience in Italy where there is noise everywhere. In Finland even in the football stadium during a match the atmosphere is quiet, safe and silent compared to the confusion and sometimes dangerous atmosphere of the Olympic stadium where I used to go in Rome.

Finnish people are quiet, but to be quiet doesn't mean that they are weak. Finns are strong people and in sport you can see their attitude. Finland has many important athletes, not only in Formula One but also in high-speed downhill skiing, cross-country skiing, long-distance running, rowing and the most important Finnish sport: ice hockey. This is like football for Italians. People go crazy for this sport. Recently Finland won the Olympic bronze medal, coming after Canada and USA. This victory was very important, especially since neither Russia nor the loved-hated Sweden got a medal. Finland is the best European country in ice hockey. Everybody does sports. Even at -15 °C, with ice on the street, or on a windy or rainy day, you can see someone who is walking or running or cycling. I used to do sports and here in Finland I started to practice cross-country skiing and also skating on ice. It is an incredible experience to walk or skate on the frozen sea. It is fascinating, and also emotional at the same time, especially for me coming from Southern Europe.

What I liked and I learned in Finland is honesty. When you come from a country where dishonesty is more common than honesty, you note immediately that in Finland it is exactly the opposite. A Chinese fellow once forgot an expensive camera in the OR pants, and after two



months his camera came back from the laundry. In Italy it would be rare to get back something that was lost. The Finnish attitude to be honest is in their blood. They are honest in their work and everybody works hard during working time. The honesty is in the respect for nature, animals and all common things. Everything is clean and everything is respected. I learned and I'm still learning a lot working with Finns.

#### 8.2.4. Never good weather

I learned very fast that Finns love their country and love to hate it. More than anything else they complain about weather. Climate is a hard task and Finns complain about it almost every second. I was waiting terrified for my first Finnish winter since June 2007, when I arrived in Finland. I was very disappointed when I realized that the winter, at least in Helsinki, is not as terrible as Finns say. I remember my Italian winters when I went to the hospital in Rome in

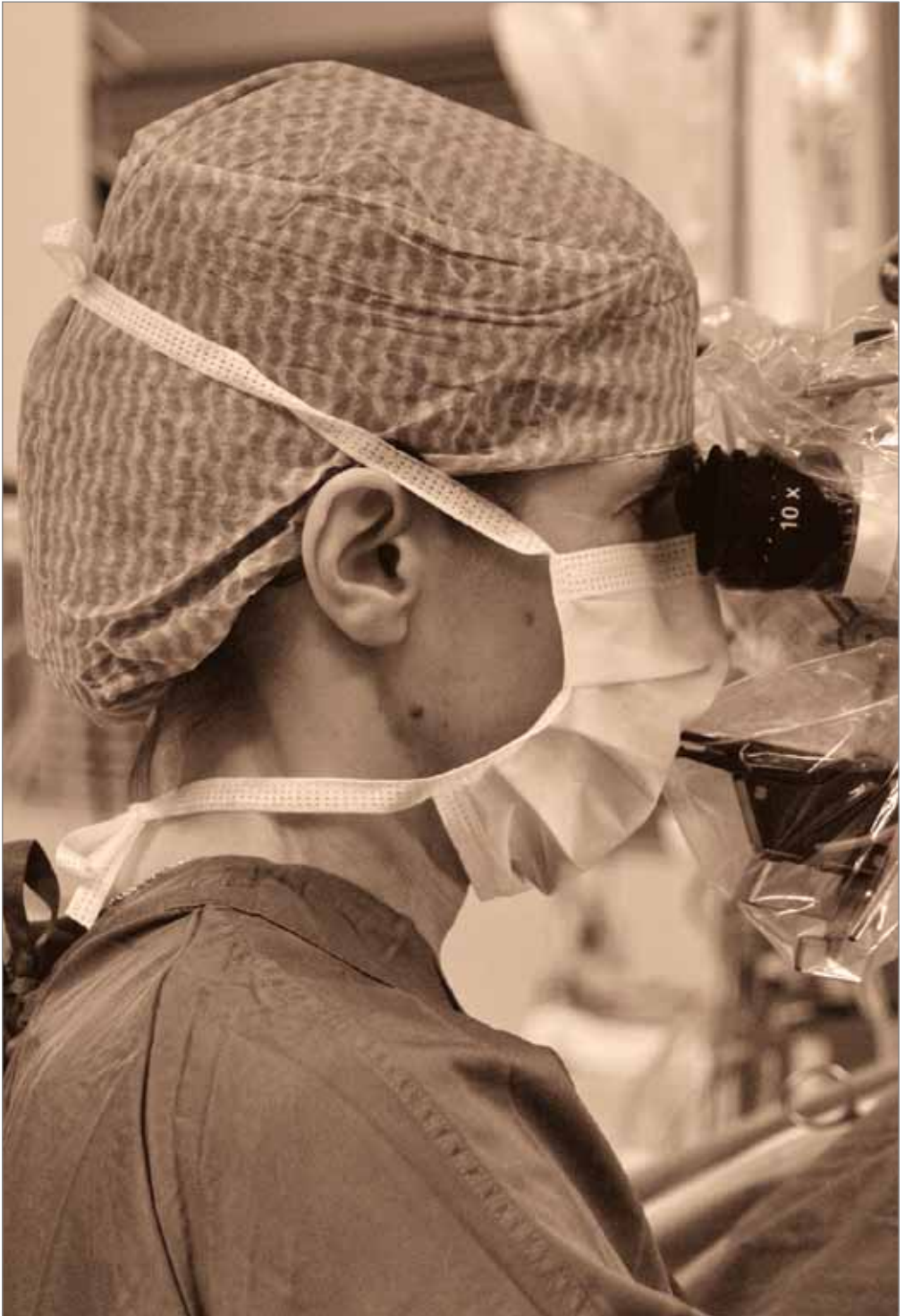the darkness of the morning and got out in the darkness of the evening. The difference in the amount of light is not as big as Finns say, and I didn't suffer for the lack of light. In the winter you can ski or skate on the sea and you can enjoy the beautiful white landscape. The atmosphere is magical and makes everything like a fairy tale. I really liked the Finnish winter.

What is different in Finland, and Finns are proud of that, is the summer. The light of the summertime shocked me, because there was too much of it. In summer the darkness disappears and if you wake up at three o'clock in the night the sun is already high in the sky. The stars disappear for a few months. This strong contrast between winter and summer makes the winter seem to be dark, but in truth it is not.

The weather is something that every Finn complains about. If in the winter there is no snow, they complain for the lack of snow. If there is snow and everything is light they complain



Figure 8-10.



*Dr. Leena Kivipelto*

about the snow and finally when the summer comes they complain about summer too: too cold or too warm! Finnish people are never happy about the weather. The first words that a foreign neurosurgeon learns in the OR is: "voi voi, voi, voi...", which is just a way to complain, often without a true reason. I can understand that weather was a problem for Nordic countries in the past, but nowadays it is not anymore and winter is not so terrible compared to Southern Europe.

### 8.2.5. Finnish attitude: "Sisu"

Working with Prof. Hernesniemi, I understood very well what makes Finns so special. It is something called "sisu". It is difficult to translate, but to see Prof. Hernesniemi performing four or five difficult operations in one day, you understand what sisu is. How Finns could manage during the Second World War is because of sisu. Sisu is a kind of force inside the Finnish gene, like a strong attitude that gives the ability to perform beyond the human capabilities. I can understand very well how Finnish people could manage against the huge Soviet Union and how they retained their independence, thanks to their "sisu".

### 8.2.6. He and she = hän

In the Finnish language there are no separate words for "she" or "he", there is only "hän". Finland is a matriarchal society and to me this explains why it is an advanced country. Here women got the right to vote in 1906, compared to Italy, where women obtained it 40 years later. The current president is a woman. Finland is a democratic country and there is equality between women and men. Even priests in Finland can be women.

In the neurosurgical department I was very impressed by the microsurgical operations of the female senior neurosurgeon Leena Kivipelto.

She performs cerebrovascular operations, bypass surgery and many other neurosurgical procedures. Watching her explains more than words can express to describe the equality between women and men in Finland.

I understood, since the beginning, that leaders in the OR are not the neurosurgeons with Professor Hernesniemi but all the nurses. Nurses have the true power. Professor Hernesniemi many times says that "nobody is operating alone" and without nurses and anesthesiologists, no surgeon can operate. Nurses in the OR have supported me very much. Without them I couldn't have managed, especially in the beginning. I'm grateful to Saara for her daily support and encouragement. I will never forget my first aneurysm surgery and the support of Sari, the instrument nurse. All nurses are so professional and all visitors in the OR have noted that. They are an example of how females are leaders in Finland and how the society supports them. Professor Hernesniemi says: "When you fail in such a good working environment you can blame only yourself".

### 8.2.7. Conclusions

When I left Italy I also left a lot of problems and negative aspects and some of them came with me because they form a part of me and my genes. Thanks to Finland I'm improving. Finland and the Finnish people have had a healthy effect on me. They taught me to do my job with method, they taught me to listen and to speak less. They widened my horizons, they taught me to see things from a different angle and finally they made me understand that the centre of the world can be anywhere and not only in Rome.

After almost three years I can say that I love Finland and Finnish people and I will make this beautiful country and people known in Italy or wherever I will decide to live. I will be forever grateful to them for what I learned.

### 8.3. IMPRESSIONS OF HELSINKI: ACCOUNT OF A VISIT – FELIX SCHOLTES (LIÈGE, BELGIUM)

"Please, no neurosurgery", he said, "just a personal account." That is what he asked for, the Professor, as we respectfully call him. To most of the local co-workers he is simply Juha. That is also how he signs his emails before he has even met you. This immediate friendly familiarity does not come as a surprise if you have had the chance to see him in his department. One immediately senses the serene atmosphere in this microcosm lead by Professor Juha Her-nesniemi.

Those who work here do exactly that: work, with competence, attention and pride in a job well done. No grumpy face, no raised voices, no inconsideration. Everything happens with great collegiality that expresses respect: respect for each other, as well as for the challenging work and its subjects, the patients. After a few weeks in Finland, to me, this attitude seems representative of a people that shines with humility, calm, and helpful friendliness.

The Finns are well aware of life's essentials and national history. Finland, which spans across the polar circle, had been occupied for a long time. The country became independent less than a century ago, freed from Russian regime by Lenin who had benefited from Finnish hospitality until the coming of Red October. Initially, civil war broke out between the socialist "Reds" and the nationalist and capitalist "Whites". The latter were lead by charismatic C.G.E. Mannerheim and supported by Germany, and aimed to establish a monarchy at the time. After the defeat of the Reds, but also the fall of the monarchy in Germany during the First World War, the young nation was finally built on a republican model. It was suc-

cessfully defended in a hard and bloody Winter

War against Russia in 1939/1940, lead again by Mannerheim. Through a long, delicate act of balance between the East and the West during the Cold War, Finland has risen to become one of the world's most respected democracies. It was the setting for the 1975 Conference on Security and Co-operation in Europe which led to the Helsinki Agreement and thus to a partial de-escalation of the Cold War. Now, it finds itself consistently among the top countries in rankings of political stability, quality of life, and wealth. Education is exceptional, with Finland on the top of the three PISA rankings of OECD countries.

Do not expect to understand a word of Finnish. Due to its Finno-Ugric roots, it is as different as Hungarian from the Germanic and Romanic Languages most of us Europeans are used to. Only sometimes one detects a certain etymological familiarity of one word or the other, like soap (saippua, German: Seife), or trousers (housut, German: Hose)... But, as soon as you speak to the Finns, you will receive answers in impeccable English, and so naturally that I rapidly stopped apologising for my deficient Finnish... The only person I met during the two months who did not speak English was an elderly lady selling plums and apples in the stands of Hakaniemen Kauppahalli marketplace. By the way, this is where you can find delicious fresh vegetables and Finnish and other Scandinavian fish, the dill to go with it, even Limousin beef, and cooking advice – in perfect English!

Nevertheless, my Portuguese colleague and roommate Pedro and I both attempted to use at least a few Finnish words. We never got much further than *kiitos* (thank you) and *hy-*



*Figure 8-12. Marshall C.G. Mannerheim, the founder of the Töölö Hospital.*



Figure 8-13. The Olympic Stadium

*vää huomenta* (good morning), but even these rather pitiable attempts brought us considerable sympathy from the waiter in the hospital cafeteria. With diligence and patience, she guided us through the Finnish specialities that were being served and instructed us on how to combine them.

One eats well in Finland. The dark whole grain bread is similar to what I know from my childhood in Germany. There is also the Swedish knäckebröd. Sweden, during its time as a great European power, had had its grip on the Finnish territory. There is still a Swedish speaking minority of about 5.5%, and Swedish acknowledged as the official second language.

I was given the opportunity to come here for a period of almost two months, as part of a year abroad, after nine months in Montréal, Québec, Canada, and a month in Phoenix, Arizona, USA. As requested, I will refrain from using neurosurgical jargon, enumerating challenging cases, and reiterating in detail what attracts so many visitors and fellows to the University of Helsinki Department of Neurosurgery. Nevertheless, there are a few outstanding impressions that I would like to share. First, there is the humility of the experienced and lucid neurosurgeon that Professor Hernesniemi is. He does not hesitate even a second to share his critical appraisal of his own operations and performance. And, sometimes, the post-operative discussion is longer than the clipping of a middle cerebral artery bifurcation aneurysm. Professor Hernesniemi clearly appreciates the presence of the visitors, fellows and colleagues, and willingly shares technical nuances, personal surgical experience, approaches to decision making, scientific facts, and the epidemiological peculiarities of Finland, but also amusing anecdotes and his critical views of the world.

No one speaks during operations except for messages concerning the operation and the patient. There is only Iskelmä Helsinki, a local radio station. *Iskelmä* is an equivalent to the German Schlager, or, as the Professor would phrase it himself, "lousy music." When he operates, the OR is filled with Finnish iskelmä music or Finnish versions of international hit songs from the past. "Lousy music allows good surgery. It does not divert attention and gives an appropriate background noise, that means less stress for the co-workers than to ask for complete silence." (J.H.)

Helsinki is a wonderful place to be. I arrived in the beginning of September, at the end of the summer, the days still warm and long. Here the northern climate is moderate, thanks to the Gulf Stream's influence on Northern Europe. Thus, one does not realise that Helsinki, the second most northern capital of the world, lies at almost the same latitude as the southern tip of Greenland and Anchorage in Alaska.

When taking strolls through the city, one is taken by the spotless cleanliness and the spaciousness of Helsinki, the abundance of parks and green spaces, the impressive bedrock visible even between the city's buildings, with even a church constructed within it! Some of these small inner-city "hills" provide refreshing perspectives and views on architectural sights like the Olympic stadium, the recently built Opera House that overlooks the pretty bay of Töölönlahti and its park, and Alvar Aalto's Finlandia convention centre. These urban patches of nature provide space to breathe, to rest among the trees or on a big stone, surrounded by green grass, like right in front of my apartment, situated at two minutes by foot from the hospital and at walking distance from the city center.

Besides parks and rock, water is omnipresent in this city on the Southern Finnish coastline: canals, bridges, bays, basins, and small ports full of boats. On the western seashore of the Töölö district, close to the Sibelius monument, the Helsinki inhabitants jog, walk the dog, and take a cinnamon roll with a nice hot *kahvi* outside, next to the sea, at charming Regatta Café. In 2002, the people of Finland, together with its Norwegian neighbour, were the heaviest kahvi consumers of the world, with approximately 10 kg per person, more than three times that of the average Italian!

Lately, the weather is starting to change, and nowadays it has been a bit colder but still sunny. Mornings are becoming darker, days shorter. Still, even now, as I am writing this in the middle of October, I tell myself what a perfect time it is to be here. The warm yellow late afternoon sun shines low on the beautiful-colored autumn leaves, and on Töölönlahti with its typical old Scandinavian wooden houses, and on the Rinkeli ferris wheel towering high in the distance. The crepuscular purple light announces the coming of dusk, and cyclists, joggers and walkers head home.

Despite this abundance of nature, Helsinki feels like a true capital, with a vibrant nightlife, shopping centers and department stores like the renowned Stockmann, museums, an impressive number of high quality ravintolat (restaurants), and obviously its architecture. The older buildings date mainly from Russian times. After their victory over Sweden, the new occupants made Helsinki the capital of the semi-autonomous grand duchy, taking the role away from Turku at the west coast in order to bring the governing senate closer to Russia. Helsinki had been of strategic importance before, as witnessed by the presence of the Unesco World Heritage Sea Fortress Suomenlinna (or Sveaborg, as the Swedish builders called it) that every serious Helsinki-tourist should visit.

And admiring tourists we are, in addition to our various professional missions, the visitors and fellows at the Department of Neurosurgery. Hugo, the neurosurgical resident from Venezuela, with a competitive international tennis past; Paco, the heavy metal bass player from Spain; Youssouff, the neurosurgery professor from Senegal; Mei Sun, the experienced neurosurgeon from China; Ahmed, from Egypt and the friendliest neurosurgeon there is; Jouke, a Dutchman with a passion for music; Rossana, who we hope will finally share one of her Italian recipes with us...

Here, fertile grounds are laid for informal international exchange and the creation of bonds across borders, some of which may last for years and will have found their origin in a common visit to the Helsinki University Department of Neurosurgery.





#### 8.4. TWO YEARS OF FELLOWSHIP AT THE DEPARTMENT OF NEUROSURGERY IN HELSINKI – REZA DASHTI (ISTANBUL, TURKEY)

I should start from May 2005 when I met Professor Hernesniemi during national Turkish Neurosurgical congress in Antalya. I was really impressed after listening to his lectures on microneurosurgery of aneurysms and AVMs. At the first possible moment I introduced myself to professor and asked if I could apply for a cerebrovascular fellowship with him. After exchanging a couple of e-mails he suggested me to pay a short visit to his department in Helsinki before getting accepted.

This short visit happened in the second half of September 2005. We met at the hospital entrance in an early Monday morning and a long working day started. My first impression from the Department was a busy but very well organized neurosurgical center. I was warmly welcomed by every member of the staff. Beside the Finnish colleagues there were also a group of fellows and visitors from different parts of the world. During that day Professor Hernesniemi operated 6 cases in the same operating room. From the first moment I was impressed by his extraordinary surgical skill. I left the OR after midnight and went to my hotel. The second day was not different, however, operations finished earlier and we managed to go for a beer with other fellows. This was a good opportunity to get to know others and get some useful information about the department and the city. I left the place after a couple of hours and started to walk in the direction supposed to be towards my hotel in the city center. After walking for almost one hour I came to understand that I went in a wrong direction and ended up far from my destination. This was my



*Dr. Reza Dashti*

At the end of the week I was accepted for one year fellowship. The reference from Dr Ayşe Karataş (his former fellow from Turkey) was important in this decision. I was very excited and motivated as this was the unique opportunity to work with the one of the best cerebrovascular surgeons in the world. However I had to arrange and organize everything very well. I planned to move to Helsinki with my family as their support would make everything much easier for me. Being accepted in the society and school in a foreign country, however, could have been difficult both for my wife and my daughter (Nakisa was almost 8 at that time). I arranged all the necessary permissions from both universities, closed my apartment in Istanbul, sold my car and in the evening of November 8th, 2005 we were in Helsinki. We moved to a flat close to the hospital. With the great help of Professor Hernesniemi we managed to find a place in one of the oldest and best schools in the city (Ressu) for my daughter.

I started to work immediately the next day,

while my wife was taking care of all aspects of our life other than neurosurgery. In the contrary to our worries it took a very short time for all of us to feel at home in this new environment. This was because of great support we received from all the members of staff in the department.

Working with a mentor like Professor Hernesniemi was a unique experience. From the first moment it was possible to see how he is committed to his fellows and visitors. It was not only possible to observe the technical aspects of cerebrovascular surgery at the highest level of excellence but much more. Among his first teachings was the principle of being first a good human, then a good medical doctor, and finally a good neurosurgeon. The compassion and caring that he has for his patients is one of his most admirable qualities.

My fellowship period was later extended to two years. During this period I had the opportunity to assist professor during 807 microneurosurgical operations. Starting from the first operation it was possible to note how every step is clean, fast and going smoothly. To see how every member of the team was acting so professionally was very exciting. The operating room was clean and calm with no noise or unnecessary talking. Professor Hernesniemi was rarely asking for instruments as the scrub nurse was following every step from the monitor. This was true for the anesthesiologist and any other member of the team as well. As every procedure was done very fast and through small, tiny corridors in the surgical field, it was rather difficult to understand anatomic details in the first weeks. I can say it took me a month to understand where M1 is. To learn how it is possible to perform the whole operation with two classical instruments (suction and bipolar forceps) and may be two additional ones, to use no retractors except for cottonoids, effective use of sharp dissection, expansion of subarachnoid spaces with irrigation (water dissection technique) and many other details was really

impressive. Apart from daily rounds we spent a good deal of time to discuss every single case before, during and after surgery. Analyzing operative videos was another important part of my training. This was a unique experience to be able to watch many hundred videos as many times as needed and then to discuss them with Professor and other fellows. The aim was to catch surgical tricks and to learn to "operate on each case in your mind". X-ray meetings every morning and cerebrovascular meetings every week were a good opportunity to go through all the cases once more. Starting from the first day I had enormous support from all the members of the nursing staff and anesthesiology team in the OR. This was not different in other parts of the department. Soon I started to feel at home by all means.

A fellowship is a unique opportunity to share similar interests, ideals, or experiences. It is always interesting to meet people from different cultures and backgrounds. This gives you the chance to improve yourself both intellectually and personally. Meeting a high number of visitors and fellows from all over the world and exchanging experiences has been another part of my training. Similarly, I have learned a lot from each member of the Neurosurgery Department at Töölö hospital.

During my stay I had the opportunity to get to know many outstanding persons in the field of neurosurgery. I remember that in the first month of my stay Professor Konovalov and a group of experienced neurosurgeons from Moscow visited the department. I found myself in the front line, taking care of these important visitors. After watching a couple of cases operated by Juha, Professor Konovalov asked me to show him some operative videos. I went to the videotape archive and selected some videos. Then we proceeded to watch the videos on the big screen in the lobby of the OR. The videos showed some difficult cases that you maybe would not like to show to such an important neurosurgeon as Professor Konovalov. I felt

that Juha was standing in the corner, watching us, and may be wondering what I was trying to do to his career. I stopped the videos. The result was a sudden change to a video from some television channel with images that one would not immediately associate with high-level neurosurgery but rather with some "late nite action" of a very different kind. "This is from Reza's private collection!!", Juha quipped, just before I fainted and fell flat to the floor.

The visit of Professor Ausman was a turning point in my fellowship. In the second day of his stay he suggested Juha to publish his surgical experience. I was lucky to be in the right place at the right moment. This was the start of the series of publications in Surgical Neurology on microneurosurgical management of intracranial aneurysms. This project - still running - became the most important part of my training as a cerebrovascular fellow. Apart from reading and studying all the papers on anatomy and surgical techniques for every aneurysm site, I watched nearly 500 videos and interviewed Professor Hernesniemi about his surgical techniques based on 30 years experience on aneurysms surgery. I am very thankful to Professor Juha Jääskeläinen who trained me how to prepare and write the papers. I had also enormous support from Professor Niemelä, Dr. Lehecka and Dr. Lehto, both as friends and co-workers. Mr. Kärpijoki was my teacher in the technical and audio-visual part of the work. The Helsinki AVM database was another important project which I took part. I worked closely with Dr. Laakso and Dr. Väärt on this project. I had the opportunity to check the images of more than 400 cerebral AVMs which was a great training. The result is a "never to be repeated" AVM database. Until now I have been involved in 38 published articles from the Department of Neurosurgery in Helsinki. Although I am still collaborating with the projects this extraordinary number of papers has been and will be very important in my career.

My involvement in The Helsinki Live Surgery

Courses was an exceptional achievement. With the concept of open-door surgery I have had the opportunity to see the surgical techniques and experience of many world known neurosurgeons. Another important activity was the LINNC course. This happened during the visit of Professor Jaques Moret. All of a sudden we found ourselves involved in a live transmission of surgery from Helsinki to Paris for an audience of close to 1000 people. This has been a unique experience for me. I was responsible for commenting on the surgeries with my ear set connected to the control center in Paris and satellite people and broadcasting staff in Helsinki and many others. During transmission of the first case I was extremely excited (as usual) and also very nervous about my ugly voice. After knowing that my voice is tolerable and not killing people I was happy.

Working with a hard working person such as professor Hernesniemi was not easy, as he is not the most flexible man in the world. Tasks should be done fast and perfect like his surgery. Days were always long and the weeks were usually starting at Sunday afternoon. The load of projects and operations plus many other tasks was heavy but not intolerable. During this period we had some difficult moments every now and then, but always managed to overcome.

After spending a splendid two years in Helsinki I returned back to my department in Istanbul. At the beginning adaptation to my old environment was not so easy. I started to miss all my good friends in Helsinki from the first moment. I realized that Finland became my third home country. Leaving Finland was much more difficult for my family than me. They were happy and comfortable in Helsinki. After going back we had to establish everything from the beginning. Especially my daughter had to get adapted back to her old school. This took some time but we could manage. I started to change my surgical habits according to what I have learned in Helsinki. At the beginning it was not

so easy but the final result is good. I got enormous support from Professor Kaynar and I am now involved actively in vascular cases in my department. Now, I feel more skilled and confident in providing care for my patients.

My experience with professor Hernesniemi had great impact on my professional and personal life. This has been a turning point in my life. For me, Juha has been a teacher, a hero, a close friend and someone very special. I am proud of being a member of the Helsinki Neurosurgery team.

## 8.5. MY MEMORIAL OF „GO GO SURGERY“ IN HELSINKI - KEISUKE ISHII (OITA, JAPAN)

I was fortunate to be selected for a course of continuing professional education at the Department of Neurosurgery at the University of Helsinki. Here, I report my memories of the training period in Helsinki from March 2003 to June 2004, and describe how the training has made differences in my current attitude to my practice as a neurosurgeon.

I started my residency in neurosurgery in 1993 and became board certified by the Japan Neurosurgical Society in 2001. It had been my sincere hope since then to have an opportunity to study in an institution abroad to see a wide variety of surgical cases. My dream became true when Professor Hidenori Kobayashi, the Chairman of the Department of Neurosurgery at the University of Oita, introduced me to Professor Juha Hernesniemi. The both professors were trained under Professors Drake and Peerless, and have been long-lasting close friends.

### 8.5.1. The first impression of Finns

Men in Finland seem rather quiet, whereas women are cheerful and speak a lot, as if Finnish ladies actually have acquired special skills to keep talking even when inhaling. Because of their talkativeness, I felt that women seemed to take the initiative on many aspects. Overall standards in culture, education and economy are superb in Finland. Finland is one of the highest-ranked welfare states in the world, and public security and order is highly maintained throughout the country. Finns are hard workers and very industrious. I was surprised to find out how many resemblances there are between Finns and Japanese regarding the behavior and daily habits. As a few stereotypical examples,

the Finns and the Japanese are both rather shy and get easily blushed (which is actually more obvious in Finns due to their pale skin tone);

a salute with slight nods is a common gesture for both Finns and Japanese; and we both take our shoes off inside our homes. On the other hand, everyone calls each other by their first name as if they were close friends - even the professor - which was one of my biggest surprises.

### 8.5.2. The Helsinki University Central Hospital

The organization of the hospital utilizes one of the most advanced information technology and people's responsibilities were highly specialized, allowing each worker to use their time at work very effectively. Effective use of time at work also meant more time personal free time and longer vacations, which was extremely impressive for me. This is an example of a difference in national characteristics and social structure that struck me during my stay in Finland.

### 8.5.3. Professor Hernesniemi and his surgical techniques

Highly effective, but comfortable OR was embodied in front of me. Beautiful team work among neurosurgeons, neuroanesthesiologists and nurses support excellent patient care also during pre- and postoperative periods. Dr. Hernesniemi was appointed as a Professor at the University of Helsinki in 1997, and has since been in charge of the most surgically-challenging cases of cerebrovascular disorders and skull base tumors. Prof. Hernesniemi performs also the positioning and craniotomy himself, as he believes that these are one of the most critical steps of neurosurgery and work

as a good warm-up for the microsurgical part of the operation. One can only admire Prof. Hernesniemi operating more than 500 major cases a year, day and night. His performance in the OR put me in an "operation shock" and totally changed my understanding of microsurgery, which to me before I saw him operating was just fingertip movements under the microscope in sheer tranquility. In a room with radio music on, Prof. Hernesniemi freely positioned himself around the microscope with a mouth switch. Every procedure was undertaken in a standing position with very little time without movement. It was like space walk. I, viewing his performance through assistant's eyepieces, was also put under the highest pressure I have ever experienced, and was oftentimes forced to take an almost impossible posture, all of which exhausted me mentally and physically. He also performs his surgery in extremely short time. I remember him joking that short operation time is always welcomed and appreciated by the staff but not necessarily by patients and their family members. Of course, fast and professional teamwork by neuroanesthesiologists and nurses greatly contributes to Prof. Hernesniemi's operational performance. The team also quickly accustomed to me, who was in a totally unfamiliar situation and not performing very well initially. Within three months, an unspoken sense of mutual understanding was established between me and the staff, and the scrub nurses never since missed to pass me the instrument I needed during the operation without naming it. My main responsibility was to perform the closure of the wound, which I did completely under the microscope, partly for training purposes.

Prof. Hernesniemi's consistency in the attitude and eagerness to incorporate any tips that might be beneficial to improve his operational performance was really impressive to me. It is not easy to keep up with his spirit in learning from discussion with visitors from around the world and to reflect the assessment to one's own operational techniques. He is constantly

interested in advancing any aspects of the surgical techniques as well as the institutional performance in the neurosurgical arena.

I recall my days of fellowship, when he oftentimes questioned himself would the time he focused on improving his operational skills, but occasionally missed being with his family, be worthy; or how should his life be as a neurosurgeon, or even as himself? These questions taught me dedication and spirit of never giving up, which is supported by the passion to go after a certain thing, neurosurgery. Prof. Hernesniemi, and his team who undertake many difficult cases days and nights, showed me that the important thing is an aim, not means.

#### 8.5.4. My current days in Japan

Since my return to Japan, I have been practicing as a neurosurgeon, with a memorial photo with Prof. Hernesniemi on my desk, to keep up with the best spirit I was given during my training in Helsinki. Of particular note, I have extended my medical commitment to extra-hospital activities as part of the life-saving team. I believe that this is one way to further project my experiences in Finland to our daily practice. Together with paramedics in doctor's car and helicopter, outreaching to patients in jeopardy and accomplishing early intervention indeed have helped successful rescue and subsequent treatment.

#### 8.5.5. To conclude

During my stay in Finland, many people supported me. I thank all of them, not only Prof. Hernesniemi, but also faculty physicians, nurses, paramedics and other staff, in my second country, Finland. I, the "Last Samurai" as my dear friend Finns called me there, will maintain my effort to develop my skills and sprits as a neurosurgeon. I would also like to send my best wishes to members of the Department of

Neurosurgery at the University of Helsinki for further medical and scientific advances.

#### 8.6. AFTER A ONE-YEAR FELLOWSHIP – ONDREJ NAVRATIL (BRNO, CZECH REPUBLIC)

Comprehensive descriptions of details regarding the cerebrovascular fellowship with Professor Juha Hernesniemi have been provided by other fellows. But how the fellowship influences surgical habits of a neurosurgeon? Learning from someone else's experience, successes and failures, substantially facilitates the professional growth of a neurosurgeon. That is why we all came to Helsinki. I was highly motivated to come to Finland because I wanted to have some advantage over other colleagues at my department. I felt that working at another department in a different country might help me to meet this expectation and enrich me a lot. When deciding to come to Helsinki, I completed the sixth year of my residency programme and started to learn the principles of more complex operations. This should probably be the earliest time for a neurosurgeon to come to Helsinki. To have some practical knowledge in cerebrovascular neurosurgery might be even better because you can continue to build on your personal experience. The upper age limit is not important because the improvement of neurosurgeons' skills is a lifelong task. However, the older one gets, the more complicated the situation becomes to leave home for a longer period. Due to my one-year stay in Australia during medical studies, my English knowledge was good enough for the fellowship. Although the Australian stay was not related to neurosurgery and medicine, I knew that it has opened another dimension of perceiving the world and I expected similar things from Finland in relation mainly to neurosurgery. And how the expectations were fulfilled?

At the end of the fellowship, many worries and doubts came to me, combined with tiredness

that naturally appears when one pushes himself to his best performance. After one year away from my home country and gaining so much inspiring insight into the highest level

of neurosurgery, one begins to worry. Will I be able to use some of Juha Hernesniemis' tricks? And if yes, will I be able to perform them in such an excellent way? How should I behave to my environment to make them accept my different requirements in the OR? Is it possible to apply different attitude to operative techniques elsewhere? Will I be able to change the habits at my home department? Gradually when time passes, I will have answers to these questions. Similar worries will probably come to every fellow before they return home. However, the conditions and positions of the fellows in their home countries differ, thus resulting in different possibilities to put into use what one has learned. Furthermore, after the big change of the entire environment, after having got used to the way things are, another change, even bigger this time, comes again – the return back home.

After coming to my home country, the Czech Republic, I took three weeks of holiday. I considered it very important to get to full strength, clear my mind and to settle down at home. During these weeks I was thinking over and over of coming back to my neurosurgical department and visited my family and friends after a long delay caused by the fellowship. I believe that strong support from family and friends in neurosurgery has a paramount importance and helps one to be strong at work.

Considering the neurosurgery itself, my attitude has already substantially changed in Helsinki but only in my mind. After spending all the time in operating rooms, watching and assisting at 424 high-level operations performed by Juha Hernesniemi from 2007 to 2008, one learns to recognise superb microsurgery and



teamwork. It is not a gift or natural ability, but an extremely hard work and dedication every day, what makes one real professional and giant. The spirit and power of Helsinki Neurosurgery has already motivated hundreds of neurosurgeons all over the world.

Currently I work at Department of Neurosurgery in Brno, Czech Republic, which is a medium-sized department. Given our catchment area, we do not get as many cases as Helsinki Neurosurgery. One can have only few operations in a week. Therefore "Juha Hernesniemi's rule" – you can learn something new from every case – is even truer, and similar cases follow each other much more infrequently than in Helsinki. After the fellowship, I immediately incorporated some of the things learned into my routine, and I feel that my technique has improved a lot. For an interested reader, some examples of the things I use from Helsinki are given below.

Like in Helsinki, before the operation I try to find my own way of operating the case, beginning with a thorough studying of the images. When unsure of how to operate, watching operative videos and the imagination of Prof. Hernesniemi in the same situation the night before usually helps to find an optimal way. Now I believe much stronger that my mind is somehow getting ready for the stress of operation and the performance is much better when coming to the OR with the mental image of the intended operative course. Trying to "operate in one's own mind" is one of the key points leading to success in surgery. When you operate in your mind, it is like you would have done the operation already. From the former fellows' and observers' point of view, I can confirm that this works also in practise. When I was in Helsinki, taking the pictures and downloading the videos belonged to my everyday tasks. Later on, archiving the videos paid back. Apart from studying the anatomy and literature, watching unedited videos keeps the operations – technique, principles and strategy, seen in Helsinki,

alive. This practically prepares me to be able to operate and have impact on the course and the duration of an operation. It is time-consuming, but very effective in the end. Precise positioning and simultaneous imagination of intracranial structures has proven even to me to be extremely important as every small detail plays its role in the end. One or two millimetres may not be significant elsewhere, but they are extremely important in neurosurgery and may play a significant role in succeeding or failing during surgery. Polite and calm behaviour is a must. When you get along well with people at work, they help you when fighting in a difficult situation at work. In my opinion, the principles of thoughtful work are applicable not only in medicine but in every profession. Until now, this tactics and behaviour has already paid back many times. I will never forget my first case of ACoA aneurysm with frontal hematoma. Naturally I was worried, but despite late night and tiredness, angry swollen brain and intraoperative aneurysm rupture I managed the operation with the help of a scrub nurse. In conclusion, without the Helsinki fellowship, definitely, I would have not performed in such a way.

However, nurses and colleagues were not co-operating fully when I was implementing changes in technique and operative tools. I have faced many times unpleasant questions and behaviour. These facts are based on natural rivalry and behaviour. Therefore we have to get used to fight against them and manage them in a daily routine. For example: bipolar forceps switched on and off by a scrub nurse, the use of syringe and needle for water dissection, operating trauma cases and closing the wound under the magnification of microscope, are some of the things I introduced based on Helsinki experience. The first few weeks were very difficult because everybody was watching me and I could feel that they were thinking I was crazy. Nowadays, after full concentration and not failing during one and half year after the fellowship, it is much easier and the staff around knows what they can expect from me

in the OR and that I never behave to them inadequately. The appropriate appreciation of their work is humble and motivating support for their further work.

Not only innovative surgical techniques make Helsinki Neurosurgery so famous. During my stay in Helsinki I understood the importance and context of working on publications. High publication and studying activity, producing high-level articles in the field are excellent. Furthermore they help to spread local experience all over the world to neurosurgeons that cannot come to Helsinki for various reasons. The papers dealing with microsurgical techniques and from experimental neurosurgery are of superb quality and worth of reading and remembering. The cooperation with neurosurgeons and fellows in Helsinki – Martin Lehečka, Mika Niemelä, Reza Dashti, Riku Kivisaari, Aki Laakso, Hanna Lehto and others was smooth and inspiring. I have learned a lot from them and this also helps me at home when preparing papers and presentations. Their permanent ambition to develop their neurosurgical and scientific skills remains a strong motivation for me. Working on projects at Helsinki Neurosurgery helps one to feel as being home, you feel involved and you can participate depending on your ability, will and desire to publish. Then you can benefit from being an author or co-author and this helps when building your position back home. Based on Finnish experience, we have also launched our own aneurysm database in Brno.

Retrospectively seen and despite all difficult times, the enormous effort to manage one year, the time spent in Helsinki was very fruitful, efficient and beneficial to be done by somebody who wants to learn neurosurgery to be performed at its best. One year in Helsinki Neurosurgery influences your life positively and helps your further development enormously. Based on my expectations, I can say that Helsinki stay has fulfilled a discovery of another dimension

of neurosurgery in my mind, but also another dimension of honest but demanding human cooperation on the highest level. Personally for me, it has opened my way to the majority of vascular cases at my department. This privilege is a great step for my further improvement in the field.

When coming back to his or her home country, the fellow should definitely concentrate to his or her work. To be able to use what he or she has learned during the fellowship, every effort should be used to change the conditions for this purpose. First year after coming back is the most difficult, because changing the habits takes a lot of time and energy. The fellow should always continue the same way as during the fellowship, use "the Helsinki fast pace" at work (i.e. very high assignment) and be able to further develop his or her skills based on the experience gained.

I will always look forward to coming back to Helsinki to see another, not only cerebrovascular case. Maybe I can notice some details that I may not have noticed before, or a new technical trick. The spirit of Helsinki will always remain huge and strong in my soul and I hope that it will continue to guide my neurosurgical career in the future.



emphasized to me seriously several times. Fortunately, Prof. Hernesniemi found a perfect solution to keep me and other fellows (Ondra and Rossana) away from depression. We really

### 8.7. ONE-YEAR FELLOWSHIP AT THE DEPARTMENT OF NEUROSURGERY IN HELSINKI – ÖZGÜR ÇELİK (ANKARA, TURKEY)

2007 was the last year of my residency in neurosurgery at Hacettepe University Hospital in Ankara. At that period I was being encouraged to apply for a fellowship, especially by my father and mother who are also medical doctors. After deciding to apply for a fellowship, it was time to find the right institution. Professor Hernesniemi and Helsinki Neurosurgery were at the top of my list since I had been interested mainly in neurovascular surgery during my residency. As a young and inexperienced neurosurgeon, it was a dream for me to be accepted to such a famous center as a clinical fellow. One of those days Professor Uğur Türe phoned and told me to send my CV and an e-mail to Professor Hernesniemi to apply for a fellowship. I sent the e-mail and received the reply in 10 minutes. I was invited to Helsinki for one week to discuss the situation. I immediately completed arrangements and went to Helsinki. I was warmly welcomed by every member of the staff and also a group of visitors from different parts of the world. During this one-week visit I had the opportunity to observe his extraordinary surgical skills and performance. I was really impressed by him, as well as his team and at the end of this short visit, I was accepted to be a part of that team as a clinical fellow for one year. The reference from Prof. Türe was important in this acceptance. My fellowship in this legendary center began immediately after my graduation from neurosurgical residency. I worked there as a clinical fellow for one year from November 2007 to November 2008. The most important concern for me before going to Helsinki was long, dark and cold winter, since unusual weather conditions in winter had been

could not find time to face this problem due to intensive program. Prof. Hernesniemi was the most hardworking person I have ever seen. Although it was fun, keeping up with him was taking all our time and sucking our energy. I assisted Prof. Hernesniemi during 452 microneurosurgical operations. However, the number of his operations watched by me was even more than a thousand since he has an open library of operation videos for visitors and fellows. The fellows were also responsible for taking care of these records and video editing to make them ready for presentations and scientific projects. Watching these videos and discussing about them with Prof. Hernesniemi was one of the most beneficial part of my training. Another important task for fellows was taking care of visitors from different parts of the world. During my stay, due to high flow of visitors, I met a high number of neurosurgeons from different countries. This provided me a good chance to share experience and learn from each other. This was also a good opportunity to have many friends and connections in the international neurosurgical society. Besides these activities, fellows were also working on different projects. I have been involved in 10 published articles from the Department of Neurosurgery in Helsinki so far. Certainly, our lasting and future collaboration on other projects as well as published articles will be very important for my career.

When I started my fellowship and began to assist him during the operations, I had the feeling that these operations cannot be done better. After a couple of weeks I realized my mistake, because these operations were being done bet-

ter everytime by him. Despite his incredible surgical skills and established main surgical principles, I noticed his struggle to push himself to do better and better. He was always trying to improve himself as well as people around him. I think it is a kind of challenge and a way to enjoy life and neurosurgery for him. My other initial wrong observation was about his surgical speed. In the beginning of my fellowship, my (like other people's) strongest impression about his operations was how fast he completed the surgical procedures. In the subsequent period, I realized that Professor Hernesniemi is not a fast neurosurgeon. Although, generally, patients spend no longer than one hour in his OR for treatment of their neurosurgical disorders, the actual time of surgery for Professor Hernesniemi is not that short. He starts to operate on a case immediately after he is consulted for neurosurgical pathology. He sits down in front of the radiological workstation to study the images and starts to operate in his mind. He simulates every small detail with his inner vision (patient position, surgical strategy, incision, location, expected surgical difficulties). He prepares himself for surgery and avoids everything that interrupts his concentration or influences his surgery negatively. He always performs the surgery a couple of times in his mind before going into the OR. The final, short but impressive step which takes place in the OR is the result of this rather long and heavy mental work. Finally, I want to come to the most important point I learnt from Hernesniemi School. Management of neurosurgical patients? Decision making? Surgical technique? Surgical tricks? Fundamentals of microneurosurgery? Certainly I learnt many things about the issues mentioned above. However, the most important things I learnt from him are beyond advanced surgical knowledge (although they are unique).

I think Professor Hernesniemi is a teacher of not only neurosurgery but also life. How should a neurosurgeon work? How should the one train? How should one learn and teach? How should one behave? How should one present himself to patients, to colleagues and to friends? Briefly, how should one be a good human being and a good neurosurgeon? I believe that these are the things that cannot be learnt elsewhere. I really feel very honored and privileged to have a master, a mentor and a friend like Professor Juha Hernesniemi.

The advent of coiling for aneurysms seemed to be the beginning of the end for the vast majority of vascular microneurosurgery in my home country. We are assured that this will evolve

## 8.8. SIX MONTH FELLOWSHIP – MANSOOR FOROUGHI (CARDIFF, UNITED KINGDOM)

### 8.8.1 How it began

As a member of the Rainbow team, it has been a privilege to be in the Neurosurgery OR's of Helsinki in Finland between January 2009 and July 2009. We were welcomed here with the characteristic open arms from the chairman of the department, Professor Juha Hernesniemi. We truly experienced the hallmark concept of the Rainbow team, which is inviting and embracing men and women from all races, nationalities, cultures and creeds, thus exemplifying unity in diversity. The senior members of the surgical staff including the Associate Professor Mika Niemelä, vascular fellow Martin Lehecka, the wonderful team of anesthesiologists, nursing staff and residents deserve a special mention.

It was during the European Association of Neurological Surgeons meeting in Thessaloniki 2004 that I was introduced to the Hernesniemi concept of microneurosurgery through his talks and thought provoking presentations. Many were stunned regarding the alleged quality and quantity of vascular neurosurgery cases. There were many audible sighs of disbelief, amazement, approval and disapproval, with mixed feelings all too often found in neurosurgery gatherings. Could this be true? MCA aneurysm clipping regularly done in less than 30 minutes, basilar aneurysm clipping in 1 hour! We were asked to see for ourselves this safe, fast, and simple surgery. It was stressed that fast did not mean "hurry", rather smooth, rehearsed and efficient. Those few senior surgeons that had visited and seen Juha were more quiet, attentive and respectful.

with further technologies including pipeline stents, maybe some form of nanotechnology, then maybe simple pills. Hopefully some day simple prevention rather than treatment will be the main focus. However, it was clear that for the foreseeable future there are going to be more instances where even more skilled and advanced exosurgery was required to deal with what others could not do and on balance needs to be done! Some have to keep it alive and at the highest and greatest standards. Could these claims be true? In a non-private government funded health system? Simple, fast and safe excellent microneurosurgery?

If justice is to be served then there was only one thing to do, and a principle of justice rang in my head *"see with thine own eyes and not through the eyes of others, and shalt know of thine own knowledge and not through the knowledge of thy neighbor."* So I paid the fee for the next Live Course and went to see for myself.

There was another major influencing factor and that was the character of Juha. His kind mannerism and humility was so clear and evident and attractive. It is said that *"A kindly tongue is the lodestone of human heart!"* Many trainees from a variety of nationalities and backgrounds with wide ranging levels of experience use to show off Juha's personal card presented to them by him. All questions and communications addressed to him were answered by him personally, promptly with warmth and kindness. This was wonderful and could only fuel my curiosity.

It was then that following the effort of traveling and witnessing during the earlier experience of the Live Course that many of us became aware of the exemplary standards of microneurosurgery in Helsinki. The safe, fast, efficient, simple, consistent and effective techniques we witnessed changed our way of thinking and instilled great confidence in exosurgery for specific simple or complex problems. Fast did not in any way suggest hurry, but instead meant efficient use of time, avoiding unnecessary hold ups and delays, utilizing knowledge of anatomy and painfully practiced and rehearsed microsurgical skills. These were presented with beautiful fluency of movement and obvious experience.

The exemplary organization of dedicated staff, uncompromising use of best equipment, availability of tools increasing the surgical armamentarium, combined with consistency made sure operations and treatments happened effectively, swiftly and minimizing neurological distress and risks. Such distress maybe in the form of decreased cerebral blood flow during temporary clipping minimized by fast and flowing surgery, and risks such as infection mitigated by meticulous technique and short operating times. The more astonishing thing was to witness such great setup of neurosurgery in a relatively small country governed by socialism, ensuring no private or financial incentive, limited population base and far less than ideal geography catered for by 4 other neurosurgical centres.

### 8.8.2. The place and the people

Even though the leadership and microsurgical standards evident in Helsinki are decisive factors for such great reputation, the people and general culture of Finland are key elements and deserve a special mention. Being in Finland is a wonderful and an unforgettable experience. If you like contrast between winter and sum-

mer then you are in for a treat. In the land of the thousand lakes the cold winter nights are dark and long and the pleasant summer days are long and bright. You can walk on the sea in the winter, enjoy tranquil and peaceful walks or treks, and celebrate and welcome the arrival of long summer days in style. A short inexpensive boat ride around 1.5 hours or helicopter trip little over 15 minutes takes you to Tallin, the capital of Estonia, where you can enjoy this beautiful city with its medieval passages and picturesque cathedrals and castle. A short trip by plane or via a comfortable train ride can take you north through the beautiful country side to Lapland, the home of the original Father Christmas, and in the cold months to see the northern lights.

On my arrival I was amazed to see such clean, organized, efficient and technologically advanced system of transport and infrastructure. A talkative and philosophical bus driver from Helsinki airport told me on my first day here, that the Finnish have traditionally worked hard in the summer to survive the winter. There is no leaving till tomorrow what you can do today. This is combined with a great sense of solidarity, equality and basic right. Helsinki is probably the calmest, cleanest and the safest capital city in the world. The city of Helsinki and surrounding districts has a population of just over 1 million inhabitants. A visitor, during short and pleasant walks in one or two days, can explore its distinctive landmarks, such as the harbour, cathedral, parliament buildings, museum of modern arts, opera house, Mannerheimintie street and Stockmann department store, and a personal favourite, the underground Tempeliaukio church and its brilliant acoustics. In Helsinki the standard of commerce, education and technology is high and the city contains eight universities and six technology parks.

In the hospital many fellows and visitors have become used to leaving their belongings including laptops and etc. in the visitors room or conference room while watching operations,

going to eat or out of the department. We have never even heard of any crime in the vicinity of the hospital. The courtesy, polite behaviour and good citizenship is probably best evident when observing parents and their children in public places, whether in shops, parks, clinics or public transport. There is extremely seldom any shouting or otherwise raising of voices. Despite many outings locally I have never witnessed any form of violence, graffiti, or very rude behaviour. This public seems to be bereft of anger, malice or envy.

With the high price of goods and services the only danger for visitors seems to be boredom but only for those who enjoy things licentious, generally illegal or very harmful. The only price you pay for being here is the relatively high price of everything. This reflects the general wealth, taxation and hard work of a largely socialist society. It insists on the provision of the highest level of education, excellent transport systems and social welfare. The high level of education has resulted in one of the most productive societies in the world. The noticeable characteristic of the people is their level of education and awareness of the rest of the world. The pleasant Finnish courtesy, calm and quite mannerism and lack of impulsive behaviour and commotion are so very obvious and pleasant. This is especially so for any Latino or warm blooded visitor. The lack of the warm verbal and even occasional tactile expressions is only a perception to any visitor and far from reality. This becomes clear if you smile first, engage and start a friendly conversation.

### 8.8.3. The Rainbow team and its Chairman

Just like the many colours of the rainbow, there are many colours, races, creeds, languages and cultures that have been and are working with, learning from and spreading the concept of microneurosurgery and standards of Helsinki neurosurgery and Prof. Hernesniemi. To understand this you only have to see the map of the

world in the OR lobby, and the number of pins placed by the respective visitors in the various territories and countries that they have journeyed from. It is understandable to see why many want to come back and stay to learn more, contribute to and be a part of the team. Like different coloured flowers in a garden each brings its attributes. Being part of the rainbow team we realise that *"The Earth is but one country and mankind it's citizens!"*

It is not easy to perform more than 11,000 microsurgical cases, over 500 AVM operations and more than 4000 aneurysm surgeries. These figures are unparalleled, especially when you consider that the cases are not prepared for Juha, so that he will arrive and do the last touch dissections or place the aneurysm clip. It is from the positioning until the job is done! This is why so many visitors continue to come here to see the whole performance. Neurosurgery for the chairman and team in Helsinki was clearly never just a job, but a passion. Nurturing talent, courage to change, tact and wisdom to engage and influence, vision to lead, patience and perseverance to see hard work come to fruition, and great love and humanity for all is what we aspire to and what we have seen in Helsinki. Leading the development and transformation of a unit acting in the interest of the people is hard! *"To be a king and wear a crown is a thing more glorious to them that see it than it is pleasant to them that bear it."* (The Golden Speech – Queen Elizabeth I).

Under the current leadership the department performs more than 3200 operations per year, including 500 vascular cases, 700 tumors, 1000 spine operations, 600 moderate and severe brain injury patients and 300 shunt and ventriculostomy operations. Also they receive well in excess of 100 visitors a year, including many illustrious and leading figures of neurosurgery, such as Professor Gazi Yaşargil who demonstrated his skills and microsurgical techniques in Helsinki during 2001–2003, Prof. Vinko Dolenc, Prof. Ossama Al-Mefty, Prof. Ali Krisht,



Prof. Uğur Türe, Prof. Duke Samson, and Prof. Alexander Konovalov.

It was an honour and pleasure to be a witness and participant of the ceremony of the award of the PhD thesis for Dr. Martin Lehecka on February 6th 2009. In keeping with local tradition the ceremony and meaningful pageantry began with a defense of his thesis witnessed by a great audience. His opponent for the day was perhaps the world's most famous neurosurgeon, and certainly one of the most published, quoted, accomplished and skillful surgeons of all time Prof. Robert Spetzler. In keeping with the Helsinki neurosurgery trademark, Prof. Juha Hernesniemi performed a surgical clipping of a complex pericallosal artery aneurysm in honour of Prof. Spetzler who was the star member of the audience. The typically successful operation carried out in just over 24 minutes was marked by great mutual respect they had for each other. Prof. Spetzler marked the occasion by his testimony in the visitor's book and in his speech during the ceremony. He stated in the ceremony that following his travels to many neurosurgical units and observing many operations and surgeons, after seeing neurosurgery by Professor Hernesniemi that "he had never seen better surgery!" Such comments are often made by many visiting surgeons, or during the annual LINNC meeting or Live Course in Helsinki. However, most noticeable was the respect, sincerity and magnanimity towards each other, maybe mutually recognising the passion and drive felt as evident by the sufferings endured, and their achievements.

I heard and noted on precious occasions Professor Hernesniemi counsel some visiting young and aspiring neurosurgeons. He would advise them that "when planning your career, find a senior neurosurgeon to tutor and mentor you. They may be in your own institute, or far away in other parts of the world. While you need the help of many different people, try to find one that you can talk to about your failures, fears,

plans and hopes. He or she may be the chairman of the institute, but he or she can also be the one who has a great soul and understanding of life - and neurosurgery." He would say that "Without the help of a tutor it is extremely difficult to become a skilled neurosurgeon, and impossible to make an academic career. The life work of Professor Yaşargil with his books and operations has been my main teacher, followed by Profs. Drake and Peerless. Many useful operative techniques and tricks have been achieved and copied by sitting in the cold corners of various operating rooms in Europe and Northern America."

There were many wonderful late evenings in the conference room during on-call days when we were treated to happy and sad tales from the past and pearls of wisdom. During these sessions other names and institutions we heard him mention about his influences included colleagues in Bucharest (Arseni, Oprescu), Zürich (Yonekawa), Budapest (Pasztor, Toth,Vajda), London (Symon, Crockard), Montreal (Bertrand), Mainz (Perneczky), Little Rock (Al-Mefty, Krisht), and Utrecht (Tulleken). In his native country there have been many strong influences on his present practice in many different ways. They include Drs. O. Heiskanen, L. Laitinen, I. Oksala (cardiac surgeon), S. Nystrom, S. Pakarinen, H. Troupp and M. Vapalahti. It was always clear to me that, no matter what, he loved and respected his mentors, particularly Yaşargil, Drake and Peerless.

For the members of The Rainbow Team lets hope that we all one day appreciate that our mentors and teachers have always loved us, no matter how well or badly it was expressed. It was the best we received at the time, and it is for us to do better. Often we as fellows saw the gratitude expressed towards Juha by patients and their relatives because of yet another life saved or changed for the better. They came from France, Norway, Russia and other lands where the word had spread. It was also well known for Juha to travel to other countries to

perform major operations. This was without any private or financial reimbursement. That meant no money what so ever being paid to him or other staff for such cases whether operated at home or abroad. And there have been countless such cases!

Months after my arrival in Helsinki following very limited socialising outside of work, I met a young lady in a social gathering. Her name was Anisa and her father was a patient cared for by Professor Juha Hernesniemi more than a decade ago. It was inspiring and joyful to hear the gratitude and love felt towards Juha and the team by this lady. Sadly her father did not survive following his subarachnoid hemorrhage despite all efforts, which had included bypass surgery. She expressed her great and lasting gratitude, and had only praise and admiration for the care and support they received from Juha Hernesniemi and his team.

It is with the hope of giving the best care possible for our patients and their families that we suffer, learn, question, and better ourselves. We provide this book as a brief revision and insight for those visitors coming to Helsinki and seeing Professor Hernesniemi's methods.



surgical team.

Much of the overall operative efficiency came from the optimization of many small steps

### 8.9. TWO MONTH FELLOWSHIP – ROD SAMUELSON (RICHMOND, VIRGINIA)

Many people visit the Helsinki University Central Hospital Neurosurgery Department each year for a relatively short period of time – ranging 1 week to 3 months. In the following pages, I share my experience from a two-month visit in January and February 2010.

My visit to Helsinki came immediately after my graduation from Neurological Surgery Residency. I came to work with Dr. Hernesniemi to get additional experience in complex intracranial procedures before an open cerebrovascular fellowship. My expectations before I arrived were to see perhaps one or two aneurysm cases per week. A few other cerebrovascular cases, such as AVM resection, would have been a big bonus. However, these expectations were quite modest when compared to the 27 aneurysms, 7 AVMs, and 3 EC-IC bypasses from 86 total operations during the seven weeks of my visit. Without a doubt, the highlight of my visit was the opportunity to scrub in for a basilar apex aneurysm clipping.

The protocol in the OR allowed for two people to scrub in with Dr. Hernesniemi at one time. While this usually meant the fellows, the visitors were allowed to scrub in when there were no two fellows available. They could also scrub in with the other attending surgeons if there was not a resident assisting with the case.

My first and strongest impression of Dr. Hernesniemi's operations was how quickly he completed the operations. However, he was never "hurried," and the speed of the operation was not – in itself – the goal. Rather, it was a reflection of the organization and efficiency of his operations, and the expertise of his entire

throughout the operation. Of these, the more concrete refinements are described in detail elsewhere in this book. However, the many "intangible" aspects of these operations are difficult to describe adequately. They have resulted from Dr. Hernesniemi's thirty years of high-volume surgical experience. For example, his manipulations of tissue almost always achieved the desired effect on the first attempt. His choice of instruments or aneurysm clips was almost always correct, and each instrument was used in a variety of ways before it was changed for the next one. The summation of all of these little refinements was rapid, nearly flawless surgery. The "common" operations were so highly polished that even the sequence of instruments that Dr. Hernesniemi used was predictable, and the scrub nurses often had the next instrument ready without a word being spoken.

Observing and discussing these high level operations was the focus of my visit. Although I was welcome to join the team on rounds, it was not expected. The majority of patient care was done in the Finnish language, but Dr. Hernesniemi occasionally took the visitors on afternoon teaching rounds, in English. The department also met each morning at 8:30 for the radiology rounds. This was also in Finnish. Therefore, during my two months in Helsinki, I only attended this morning meeting during the first week. I found plenty of opportunity during the day to review the imaging for the important cases.

In addition to the operations, there were a number of other ways that I learned more about microneurosurgery during my visit. Dr. Hernesniemi credits his microsurgery train-



Figure 8-15. The OR library.



Figure 8-16. The OR meeting room.

ing primarily to Dr. Yaşargil and Dr. Drake, and their classic textbooks, or his experiences with them, was mentioned nearly every day. I spent many hours with him listening to his insights from the recent surgical cases or his past experience. He also gave thoughtful responses to every question that I had.

I spent many evenings and weekends reading through the neurosurgery textbooks in the main gathering room of the OR suite. Five or six books, in particular, have received considerable attention from the residents and visitors, and reading them in the context of Dr. Hernesniemi's teaching seemed to give them a higher level of meaning. These books included the volumes of Yaşargil's book series, the book on vertebrobasilar aneurysms that Dr. Hernesniemi co-wrote with Dr. Drake and Dr. Peerless, as well as Dr. Sugita's and Dr. Meyer's micro-neurosurgery atlases.

There were also a number of surgical videos and presentations that have been prepared by the department. Visitors are free to download this material. There was also opportunity to prepare the videos and imaging from the cases that I observed during my time in Helsinki. The OR staff provided additional information that I needed. For example, I received a copy of the instruments in Dr. Hernesniemi's micro-instrument tray, and one of the scrub nurses helped me translate it from Finnish into English.

In conclusion, visiting Dr. Hernesniemi and the Helsinki Central Hospital Department of Neurosurgery was a one-of-a-kind opportunity to observe microneurosurgery at its best. I recommend it for anyone with an interest in optimizing their own cerebrovascular neurosurgery skills.



## 8.10. MEMORIES OF HELSINKI – AYSE KARATAS (ANKARA, TURKEY)

In 2003, when I was in Amsterdam as a trainee on the EANS course, I had a chance to meet Prof. Juha Hernesniemi. I was very impressed by the aneurysm and AVM operation videos he presented. He was using quick and clean surgical technique on very complicated cases. He was able to perform a high number of micro-neurosurgical operations. After the lecture, all trainees, including me, wanted to talk with him. He ran out of his business cards completely due to a high demand, but was so kind to get one for me. Not only his professional abilities, but also his humble personality affected me very much. I thought to myself: "I should learn cerebrovascular neurosurgery from him".

I went to Helsinki in November 2003 for the first time. I arrived at Helsinki airport at midnight. First, I had to go to Töölö Hospital to pick up the key and the map of the apartment where I would stay. However, I did not know exactly where the hospital was. I was lucky, and when I got on the Finnair city bus, Prof. Hernesniemi also got on the same bus coming from a domestic flight. I felt very relaxed after seeing and talking to him. We went to the hospital together. He called me a taxi and gave me a bus card for the next day. I stayed just for one week. I can remember very well my first day in Helsinki. He operated five cases (one basilar aneurysm, two middle cerebral artery aneurysms, a craniopharyngioma and a colloid cyst). He was on call that day, and even operated a lumbar disc herniation with cauda equina syndrome on the same night. During that week, I was fortunate to assist him in 13 operations (one of them was an ELANA bypass and another one a trigonal AVM). During that period, Dr. Keisuke Ishii from Japan was also there as a fellow. Later on, I started as a

clinical and research fellow on the 1st of August in 2004, with the support of CIMO scholarship for international post-master's level studies and research at Finnish universities. I stayed in Hel-

sinki for a year. During this period, I assisted him in 357 microsurgical operations. I edited and analyzed a high number of operative videos during the weekends. We were watching these videos during the breaks between the operations and discussed them with him. I was also involved in many research projects, especially on cerebral aneurysms. I appreciate Dr. Mika Niemelä, Dr. Juhana Frösen and Dr. Anna Piippo for their collaboration in these research studies.

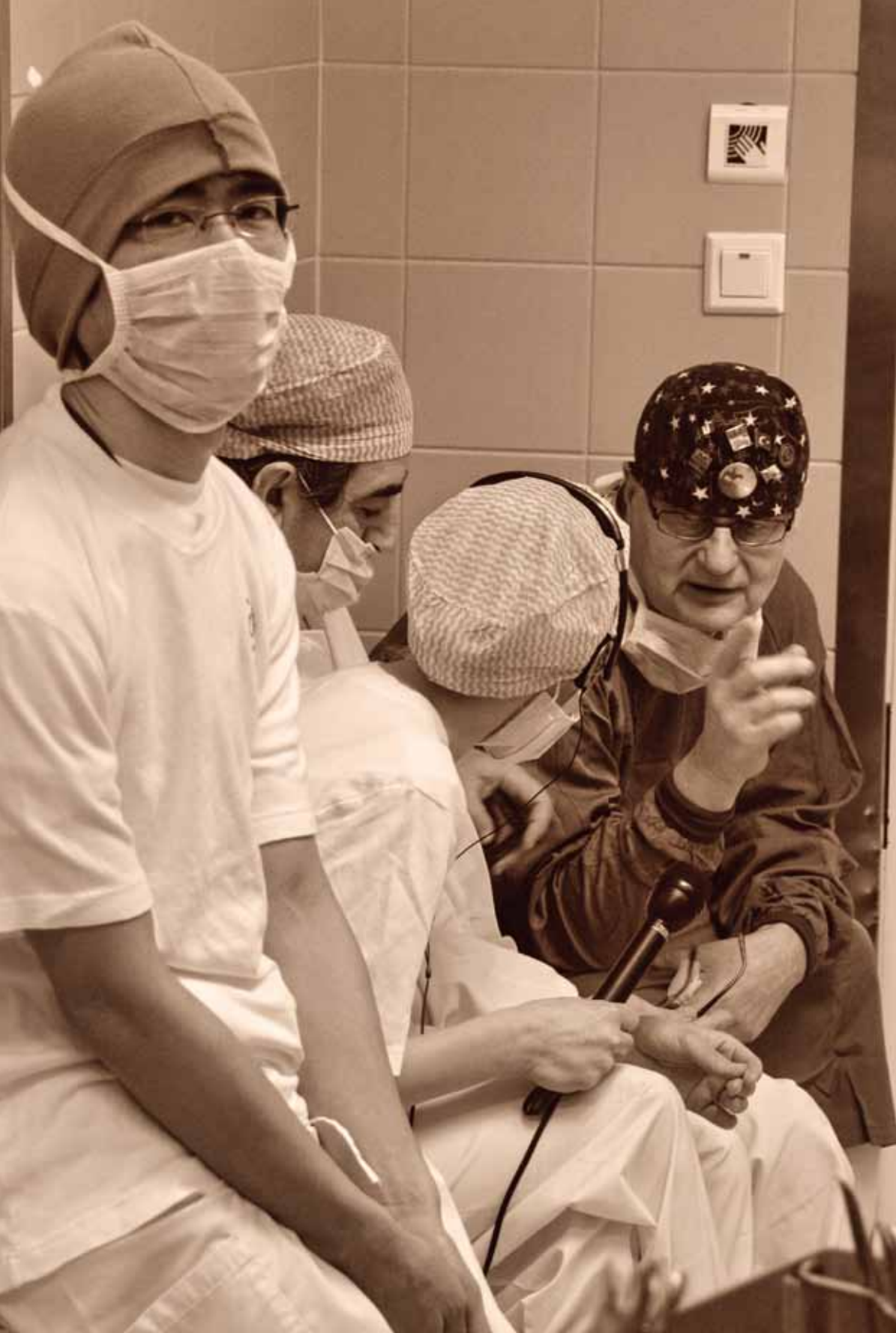The Department of Neurosurgery in Töölö Hospital of Helsinki Universal Central Hospital is a referral center for complicated cerebrovascular cases in Finland and also other countries in Europe. In Töölö Hospital, most of the aneurysms are clipped. They also have a very experienced neuroradiology team. I respect Dr. Matti Porras, and cannot forget him standing and observing for many hours during AVM surgeries in the operating room. All anesthesiologists and nurses have also dedicated themselves to neurosurgery.

Prof. Juha Hernesniemi is a very hardworking surgeon. Although I have graduated from Ankara University Department of Neurosurgery in Turkey, which is famous for its intense curriculum, it was really difficult to keep up with his busy schedule. He was sending emails to me about his daily work. I noticed that the first email was sent at 5.00 AM in the morning. I went to the hospital at 7.00 AM. We visited the ICU, and then attended the radiology meeting. Operations started at 8.30 AM. We were operating 3-5 cases a day. He was doing fast but safe surgery. He is a very good role model for a young neurosurgeon. I learned from him many important tricks during every step of the sur-



gery. We were using "four-hand-microneurosurgery" as he called it. He was very helpful and empathetic for the visitors, since he had stayed abroad for many years himself. He became not only my mentor, but also a good friend for me during my stay. I remember my last day in Töölö. I walked with Prof. Hernesniemi to the exit door of the hospital while he was going home. On that day, the hospital flag was at half-mast because one of the nurses had died. It was already a sorrowful day for us, so we could not talk to each other. He could only tell me that he had sent me an email. I will forever save that email which is really important for me.

I am honored to have met and worked with Prof. Hernesniemi. I would like to thank him for his support that he gave me.



## 9. SOME CAREER ADVICE TO YOUNG NEUROSURGEONS

by Juha Hernesniemi

It is difficult to select trainees to become future neurosurgeons. We should pick young people with so much dedication, determination and full of energy that one day they will become far better than what we are. In my department, this selection is mainly based on my foresight that, one day, this particular young person will amaze me with both creativity and skillful performances. I hope, that with time some of these youngsters will become the best neurosurgeons in the world.

They must be young because the learning period is long, a whole lifetime! They must be intelligent, flexible, they must get well along with very different people. At the same time they must have a somewhat stubborn and tenacious character to fulfill their goals, often against the wishes of other people, sometimes even the chairman. They must be able to travel, and they must be fluent in the main languages of the international neurosurgical community, so as to be able to visit departments all over the world to learn new ideas and techniques. They have to be hard working and have good hands, irrespective of their glove size. It is extremely helpful to be in good physical and mental condition, by doing some sports or other hobbies which help to quickly recover from the many failures and complications encountered in everyday work.

A good healthy sense of humor helps, and it is important to have the support of the family or good friends in all the daily joys and sorrows. Cynicism and black humor alone, will probably not be able to carry someone through the years of hard work, rather he or she will experience

burn out sooner or later. The new trainees must realize from the early beginning that reaching a high professional level comes at the expense of long working hours and one is never truly

free from the work. If possible, they should transform their work also into their hobby as that helps in maintaining the interest in the field for long periods of time.

I would like to share some of my thoughts and reflect on some of my experience about the issues a young neurosurgeon should be aware of and maybe give little advice on how to overcome some of the difficulties.

Many of the movements we perform with our hands under the large magnification of the microscope should become automatic, without the need to concentrate on them, like e.g.

### 9.1. READ AND LEARN ANATOMY

To become a better microneurosurgeon, one should constantly study microanatomy of the brain as better knowledge of microsurgical anatomy leads to better surgery. With beautiful CT, MRI and angiography images of today, learning central nervous system anatomy is far easier than in the times of PEG, ventriculography and surgery without microscope. Reading the many textbooks available gives us the opportunity to share the accumulated experience of several generations of neurosurgeons. Preparing yourself for some new or infrequent operation by reading, means that during the actual surgery your hands will be guided by those who had previously accumulated much more experience on this particular procedure. By reading frequently you may save, first and foremost, your patient, but secondly also your time and your nerves. It is not enough to learn the anatomy once, rather, one is forced to revisit the same topics over and over again before acquiring appropriate expertise in the matter. Reading is hard work – and learning anatomy is even harder. It is a lifetime job, or more!

### 9.2. TRAIN YOUR SKILLS

Neurosurgery is no different from any sports or arts; only hard practice gives good results. Go to the microsurgical laboratory to dissect animals and cadavers if possible. Knowing anatomy and the different tissue properties results in better surgery. Train your hands in the laboratory setting in increasingly demanding tasks. Operating under the microscope should be started in a safe laboratory environment with enough time to familiarize oneself with all the instruments, devices and techniques, not to mention to develop the necessary hand-eye co-ordination.

placing microsutures. Practice special tricks in handling difficult situations, atraumatic manipulation of different kinds of tissues including the tiniest arteries and veins, dissection of important vascular and neuronal structures, and understanding the 3D relationship of different structures. It is possible to train most of the steps for any operation whether for vascular, tumor or spinal surgery in the laboratory setting. Not necessarily as a single procedure but as a collection of different techniques.

### 9.3. SELECT YOUR OWN HEROES

When beginning your career, select your own heroes. They may be in your own institute, or far away, in other parts of the world. While I was visiting the maestros and sitting as an observer in the corners of various cold operating rooms around the Europe and North America for altogether more than two years during my early career, I always dreamt of the day that I would be doing the same kind of high level microsurgery. During one of my numerous visits to Professor M.G. Yaşargil nearly 30 years ago, a young Mexican neurosurgeon told me "One day we might do even better!" At that time I found it hard to believe him, but now, with retrospect I know that he was right. The same happens in sports, arts, and technical developments, the younger generations do better as they can stand on the shoulders of older ones. Or not stand – they should begin their quest from a new starting point, the point where these earlier giants finished.

When planning your career, find a senior neurosurgeon to mentor you. While you will need the help of many different people, try to find

one to whom you can tell about your failures, fears, plans and hopes. He or she does not have to be the chairman of the institute, but he or she should be the one who has a great soul and understanding of life - and neurosurgery. Without the help of a good tutor it is extremely difficult to become a skilled microneurosurgeon, and almost impossible to make a real academic career.

#### 9.4. KEEP FIT

Keep your body fit with regular exercise. Doing several hundred operations a year is both physically and mentally demanding, so try to find hobbies outside of the operating room to balance it out. This is easily said, but at least I have had big difficulties to follow these rules.

You should do everything you can to avoid fatigue, burn-out and cynicism towards your work. Remain a fighter, never give up; if you were thrown against a smooth wall, you should hold to it with fingers and nails like a cat. Keep up with mental training all the way throughout your career. Even close to or after your retirement you can still be useful, as you can continue to share your experience with younger neurosurgeons. With age you will slow down; you should respect this and behave accordingly. But neurosurgical skill and experience remain, something which is difficult if not impossible to achieve in a short time. Experienced neurosurgeons, unlike experts in e.g. the information technology field, are not pushed aside as easily by the next generation. *Ars longa, vita brevis, occasio praeceps, experientia fallax, iudicium difficile.*



*Figure 9-1. On the footsteps of a giant. Prof. Hernesniemi watching closely Prof. Yaşargil operating.*



Figure 9-1. "One day we might do even better!" At Weisser Wind in Zurich in 1982 (photo from Prof. Hernesniemi's personal archive).

#### 9.5. BE A MEDICAL DOCTOR, TAKE RESPONSIBILITY!

Be a medical doctor when treating your patients! Don't hide behind the back of other neurosurgeons to save your own face. You have the responsibility for the patient, not for your untarnished surgical series. Within a busy institute one can easily build up a reputation of excellent surgical results by avoiding the high-risk patients and passing them on to others. With extreme selection of suitable cases, many patients will be excluded and die without ever being given a chance to survive - and this only to save the good outcome figures for one's surgical series. Superficial analysis of results from some institution may give you the wrong picture regarding the skills of a particular neuro-

surgeon, the one with the worst results may actually be the best, as he or she may be tackling the most difficult cases, thus facing the most difficult complications.

#### 9.6. LEARN YOUR BEST WAY OF DOING YOUR SURGERY

Find your own best way to work, select your (few) favorite instruments (like e.g. the "little thing", i.e. a small dissector used by Dr. Drake to push aside the aneurysm dome) and trust them. Be open to new techniques and instruments. Try them out and if you find them good, adopt them. As Dr. Drake said, "much of the merit of an approach is a matter of surgical experience". He advised to make operations simpler and faster and to preserve normal anatomy by avoiding resection of the cranial base, the brain or by sacrificing the arteries and veins. All this results in better outcome for the patients, the only thing that really matters. You should try new treatment methods if you suspect that

they might beat the old ones. But while reading various reports on new techniques with excellent results, be critical and believe your own figures; after all it is you providing the treatment, not the author of the publication. Furthermore, don't change your methods if you are performing well!

A clear evaluation of your own skills could be stated in the following way: "Would you feel safe to be operated on by yourself?" If not, develop your skills further, study and learn from those who are better! In my opinion, with a more active approach towards microsurgery, intensive care, imaging, rehabilitation and changes in mental attitude, we have made significant progress as compared to the 1970's, the time when I started my career. The annual number of operations per neurosurgeon has clearly increased. We have become more efficient, and the work, which is done well at a brisk pace, with greater experience, usually results in better outcome. In a way, I must agree with Jehovah's witnesses, clean surgery without blood loss is the fastest and safest way for the patient, and also for the staff.

### 9.7. OPEN DOOR MICROSURGERY

Go to congresses, give lectures and participate in discussions. But in addition you should also visit different departments, both home and abroad. Lectures in congresses give only a simplified picture of the actual level of neurosurgery at a particular institution. Unfortunately, the true results are often worse than those presented. Accept visitors. When doing so you get a great chance to learn and to be criticized by intelligent people who may have quite a different experience and different ways of thinking. With the constant presence of these observers you will be forced to perform on a much higher level than if you were operating just by yourself. Since 1997, I have been privileged to have a large number of excellent international fellows and visitors, who have taught me often

more than what I felt I could teach them. Question, argue and discuss your daily routines. Tolerate different people and innovative thinking, but also stick to your old habits if proven good. When you go to visit neurosurgeons with excellent or new skills, you may learn much more in a few days than from traveling to tens of congresses and listening to hundreds of presentations. When traveling, try to adopt all the good things, even the small details. Of course this is not always possible due to economical, religious, or other factors that, perhaps, may be even related to your own surgical skills. You should travel throughout your career, as a resident, as a young neurosurgeon, and even later on as an already experienced specialist - you are never too old. Try to remain enthusiastic about learning new things, but remember that hard work and suffering is also a part of the learning process.

### 9.8. RESEARCH AND KEEP RECORDS

Remain critical towards your own results; that is the only way how to improve. Analyze your own cases immediately after the surgery; "why did it go so badly, why was it so smooth?" Write it down in your operative notes, track sheets or database, but make sure to record your findings. Our memory is short, only few months or even less if the number of cases is high. You should not be desperate if you don't have the top facilities, because it is the actual work that counts the most. The paper track sheets of Drs. Drake and Peerless, primitive from the present perspective, could still serve as a testimony of surgical experience and techniques for the upcoming generations.

Make videos and photographs, analyze them, draw if you can, and discuss the cases with other neurosurgeons, residents and students. When recording your operations, you will find that you end up doing better and cleaner microsurgery. Analyze your cases also in your mind in the evenings or even during the sleep-

less nights. Perform mental exercises in how to improve your surgery, which moves to omit or to add. Share your experience with others, especially with younger people, and speak openly

about your complications. Being open means honest surgery, and the truth helps always also the patient. Do not brag in advance about how simple a particular case will be ("...even my mother could do it...") as in this very same case you may end up having the most surprising and horrifying complications!

Dr. Drake stated in his book on vertebrobasilar artery aneurysms: "If only we could have back again many of those who were lost or badly hurt, for a second chance in the operative room with what we have learned." With an individual patient we cannot have a second chance, but this chance is given to the next patient if we keep all of our experience in our memory and databases, analyze it and use it well.

### 9.9. FOLLOW UP YOUR PATIENTS

You should keep track of your own results. Follow up your patients with postoperative check-ups on a regular basis, with outpatient visits, letters, telephone calls, and hospital records and add this follow-up data to your database. You should have your own personal small databases to keep track of your own surgical skills; it is only fair to your future patients if you know what the risks are of you performing a particular operation. If there is somebody close by who can do it better, let him or her operate on the patient, and meanwhile enhance your skills by observing, reading and practicing in a laboratory. You should not settle for mediocre results, always aim for the best standards of treatment! Mistakes happen, but don't make the same mistake twice. Discuss and analyze your cases with others, ask for advice to avoid future complications or disasters.

### 9.10. WRITE AND PUBLISH

Publish your results but don't publish everything! We should remember Francis Bacon's (1561-1626) words, cited on the first page of Dr. Drake's book "Every man owes it as a debt to his profession to put on record whatever he has done that might be of use to others". "One or two good papers a year in good journals are enough" was Dr. Drake's advice. In the present explosion of knowledge we should be very critical about what is published; only high quality data with good analysis and proper message. When publishing, we should look for relevant literature and not neglect the original works of the pioneers or the most important works on the subjects. Writing and publishing is hard work, it has to be practiced in the same way as surgical skills. The true skill comes only with time and numerous publications. Excuses like "I'm too busy with my clinical work to write..." are out of place. In neurosurgery, everybody is generally busy with his or her clinical work, which is the reason why writing is so hard. But despite the difficulties, writing is time well spent. Before putting any ideas on the paper, one is forced to analyze the problem to the smallest detail so that it can be communicated to others in a simplified and condensed way, often resulting in new ideas. The other advantage that comes from writing is that one becomes also a much better and more critical reader, who is able to distinguish a good publication from a poor one at a glance. Finding the proper balance between writing and actual clinical work is one of the most difficult tasks in academic neurosurgery.



### 9.11. KNOW YOUR PEOPLE

We are not alone when doing surgery. Treat all your staff members, such as anesthesiologists, neuroradiologists and nurses, well. Know their names, be familiar with their strengths and weaknesses, and adjust your surgery to the team you have available at that very moment. If the team is less experienced, as is often the case during the night, you must weigh the risks and benefits of doing a particular procedure at that time as opposed to doing it some other day with a better-qualified team. Many things affect your work: patients, their relatives, nurses in the OR, intensive care and bed wards, other neurosurgeons, anesthesiologists, other surgical specialists, referring doctors, administrative people, politicians, the society, and even your international colleagues. You will establish your reputation based on many factors, not only the success in surgery. Good reputation is hard to build, it takes years and years of work, but it can be swept away in a short instant if you drop your standards. On the other hand, with good reputation one can withstand many difficult situations and complications as long as the level of work is kept at the highest possible level. You must continuously monitor your own work: postoperative angiograms, CTs, and MRIs should be ordered and analyzed by yourself and your staff, otherwise someone else will order them. It is technically much easier to e.g. replace an aneurysm clip soon after a failed clipping or to remove a small tumor remnant observed on a postoperative image, compared to the abhorring thoughts of all the dangers and psychical stress to the patient if it has to be done after a longer period by someone else. In order to avoid malpractice charges one of the key points is to be open and honest, and to carry out postoperative controls.

### 9.12. ATMOSPHERE

The atmosphere in the department should be open and supportive of good work, and the employees should be proud of their clinic. Internal education of young doctors and nurses is a must; they will better understand the whole workflow of the department and they will become more open to helping their colleagues in need. Be honest! The staff has the right to know what happened to patients who experienced complications; otherwise rumors will destroy the atmosphere.

We should know our people, be kind but demanding. Do it in your own personal way, not in the ways some consultants or books on administration tell you to. Express your appreciation of your hardworking colleagues; pay them well if you can. It is a pity that in the socialized system of Scandinavian medicine this is seldom possible. Many neurosurgeons are passionate workers by nature, but being paid enough is also important. But above all, try to be a role model of a hard working professional who takes justified pride in his or her own work and who is continuously trying to improve his or her work.



## 10. LIFE IN NEUROSURGERY: HOW I BECAME ME – JUHA HERNESNIEMI

*“You are not famous”, said Professor Yaşargil to me when visiting Helsinki 10 years ago. I thought “Maybe not famous but good...”, to contain my self-confidence – I do know all aspects of the difficulties related with working in a small country – but also its benefits...*

I was born in 1947 in a very small village of Niemonen, a part of Kannus in Ostrobothnia, Western part of Middle Finland. My father spent 5 years of his youth as a soldier in the Second World War, when Finland was attacked by the former Soviet Union. Later, he became a teacher and our family settled down in Ruovesi, a small beautiful country village 250 kilometers north of Helsinki where I went to school.

I decided to become a medical doctor back in Ruovesi due to the influence of Dr. Einar Filip Palmén, a general practitioner (1886-1971), who treated alone all the 10,000 people living in this area for 50 years. We became friends through hobbies, like collecting stamps, coins and butterflies. I was doing also gymnastics, and my heroes were Boris Shaklin from Soviet Union and Yukio Endo from Japan. Later as a schoolboy, I went to work in a factory in a small German city called Lünen, and I noted that I have very quick and skillful hands. During this stay, I also hitchhiked to Austria and Switzerland, and visited Zürich for the first time. At that time I had no idea how much influence this town would eventually have on me.

After I graduated from high school in 1966, I applied to the Medical Faculty in the University of Helsinki but failed. Looking back, this turned out to be the best thing that could have

happened to me at that time. I had to go to study elsewhere, so I applied to study medicine in Zürich, Switzerland. In Zürich I became a real European, even an international person. I learned to work hard in a Swiss and international way, and I saw the value of detailed knowledge of anatomy. I still regularly study the book of Topographical Anatomy by Professor Gian Töndury, even though it is more than 40 years since I opened this book for the first time. During my studies, I worked for more than two years at the Brain Research Institute lead by the hard-working Professor Kondrad Akert, focusing on experimental neuroanatomy. Not only did I see the high level of basic research, but even more importantly, I learned how to use an operating microscope, OPMI1. Furthermore, I also learned some ‘broken’ English in this very international team.

Eventually, I realized that basic research was not for me, and so, after attending the lectures of Professor Hugo Krayenbühl and Professor M. Gazi Yaşargil, I decided to become a neurosurgeon. I asked Professor M. Gazi Yaşargil if I could join his team in Zürich. He accepted my request. But at that time, after having spent seven years in a foreign country, I became very much homesick, so that I had to forget my plans about joining Professor Yaşargil, and moved back to Helsinki instead. This was providential, as two of my Scandinavian friends could not manage the demanding training in Zürich clinics. Why did I end up in neurosurgery? My second interest, cardiac surgery, necessitated first training in general surgery, and this seemed way too long for me before entering cardiac surgery itself. But one thing I adopted from cardiac surgery, a one-hand knot I learned from the great cardiac surgeon Professor Åke Senning in Zürich. I still use this knot when operating under the microscope. Psychiatry, a third



*Figure 10-1. Juha Hernesniemi with parents (Oiva and Senja) and younger brother Antti in 1950.*

interest of mine made me to attend the famous Manfred Bleuler's lectures but practice in psychiatry in Finland and elsewhere proved ultimately to be not very attractive to me. So eventually, I started my neurosurgical training in Helsinki in 1973 under Professor Henry Troupp. In 1966-73 even we, the very beginners at the Zürich University, were aware that something very special was happening in neurosurgery, the rapid development of microsurgery by Professor M. Gazi Yaşargil. As many neurosurgeons in the world, I have been a student of his for more than two thirds of my life, even if I was living very far away for most of the time, but at the same time, living so very close, as I was learning from him and his work. Already as a medical student I was aware of my geographically even more distant heroes in Canada, Profs. Charles G. Drake and Sydney J. Peerless, but it took a long time before I had the opportunity to visit and work with them. Some

other international neurosurgeons who have influenced me in many ways are C.F. Tulleken, Y. Yonekawa, H. Sano and R. Spetzler. Besides these giants I have found also younger heroes, and I try very hard to learn and develop all the time with them. A special credit I give Mrs. Rosemarie Frick, who runs an experimental laboratory for practicing microsurgical techniques in Zürich. Domestic colleagues who have been most influential on my present practice in many different ways have been (in alphabetical order) Drs. Olli Heiskanen, Lauri V. Laitinen, Stig Nyström, Seppo Pakarinen, Henry Troupp and Matti Vapalahti. Outside of neurosurgery, Drs. Erik Anttinen (psychiatry and neurology), Viljo Halonen (neuroradiology), Eero Juusela (GI-surgeon), Aarno Kari (ICU), Markku Kaste (neurology), Ulla Kaski (pediatrics), Ilkka Oksala (cardiac surgeon), Teuvo Pessi (general surgeon, ICU), Matti Porri (GP), and Jukka Takala (ICU) have had a great influence on me.



Figure 10-3. Juha Hernesniemi with Finnish friends in Lünen, Germany, in 1964.



*Figure 10-2. Dr. Einar Filip Palmén (1886-1971), a general practitioner in Ruovesi.*

Neurosurgery is not different from sports or arts, where only hard practice gives good results. The worst handicap in my early training was the lack of a real microsurgical laboratory practice, and the second was the lack of proper anatomical studies in cadavers. I have several times tried to correct this afterwards, but not very successfully between my heavy flow of surgeries. One definitely should devote time to these studies already when training in neurosurgery.

I was trained in neurosurgery in Helsinki during 1973–79, and made my Ph.D. in 1979 on head injuries. Thereafter, I worked for some months in Uppsala, Sweden, and then joined Professor Matti Vapalahti in Kuopio, Finland. I had the opportunity to operate on a large number of patients with aneurysms, AVMs, tumors and spinal problems, as the number of neurosurgeons was initially very few. In fact, we pioneered early aneurysm surgery in the Nordic Countries. Our active and growing team in Kuopio went to visit several important international centers, and my own neurosurgical techniques developed and improved further. In the late 80's I noticed the lack of my own pub-

lications due to hard clinical work. I was then allowed to establish the aneurysm database in Eastern Finland, on which many publications and our clinical experience were based.

I was not a visiting professor, but a research and teaching fellow in Miami in 1992–93, studying the vertebrobasilar aneurysms and posterior fossa AVM series of Drs. Drake and Peerless. This turned out to be a very important factor for my later appointment as a full professor and chairman in Helsinki in 1997, even though this period was looked at with scepticism by one of the leading British neurosurgeons ("At the age of 45 he seems to be happy to study surgeries of others"). Seventeen years earlier in 1980, I had left Helsinki for Kuopio because I was not allowed to do enough surgeries. At that time my teacher and chairman Professor Henry Troupp asked me, "...if I would ever come back...". I answered promptly: "in 17 years". I fulfilled my promise.

In 1996, there were only 1632 neurosurgical operations in Helsinki, and the annual budget of the department was 51 534 000 Finnish marks (FIM) (about 10 million euros). The department had traditionally to put up with minimal resources, and saving money was a virtue

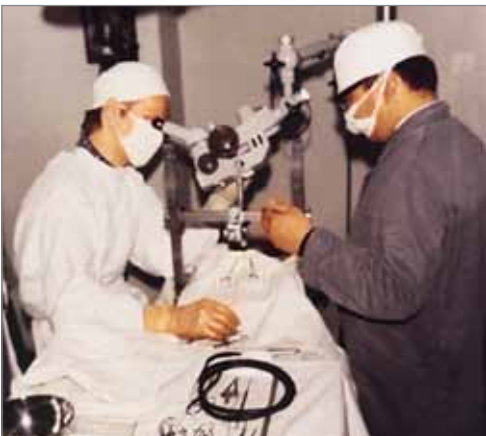

Figure 10-4. Juha Hernesniemi (left) training microsurgery in Zurich in 1969 with Dr. Etsuro Kawana from Tokyo, Japan.



Figure 10-5. OPM11 surgical microscope. Photo courtesy of Carl Zeiss AG.

exceeding everything else. However, in three years, after I became the chairman, the number of operations and the budget had doubled (in 2000: 3037 operations, the annual budget 103 065 000 FIM). People in the hospital administration, and even in the department found it hard to believe. The justification of the quantity and even the quality of treatment were questioned, and an attempt to fire me was initiated. Consequently, I had to collect figures on the activity at other neurosurgical departments in Finland and the neighboring countries, especially Sweden and Estonia. An internal investigation by the administration continued for more than a year, but finally disclosed that the patient selection was appropriate and the treatment results were of high quality. Nowadays, we are well supported by our hospital administration and surrounding society as they clearly see the value of our high quality work.

We are continuously evaluating our daily work and the fate of our patients. Our main goal is to serve our society in the best possible way. The whole Helsinki Neurosurgery staff (doctors, nurses, technicians and others) now consists of more than 200 people, the annual budget is 26 million Euros, and the number of annual operations is 3200.

Since 1997, the number of publications has increased steadily. Both our own staff but also an increasing number of fellows and visitors have been involved in clinical papers. Finland, with a small population of 5.3 million but with a very well developed infrastructure, is one of the few countries suited for reliable epidemiological studies. The long-term follow-up studies of Troupp and others since the Second World War have thereafter been continued with several great contributions to show the natural history



Figure 10-7. Juha Hernesniemi with Prof. Charles G. Drake in Miami in 1993.





*Figure 10-6. Juha Hernesniemi working in hospital in 1972.*

of AVMs, tumors and aneurysms. The Helsinki Aneurysm Database is going to be finalized at the end of this year, with more than 9000 patients with cerebral aneurysms treated. This

will increase certainly the number of the clinical studies, and there are already several large projects going on.

I had no special administrative training to be a chairman. I have looked carefully in my surroundings, and I have learnt a lot from my father Oiva Hernesniemi, and from my former chairmen Professors Konrad Akert, Henry Troupp and Matti Vapalahti. I have followed Finnish General Adolf Ehrnrooth's advice to be in front and middle of the staff (and always present), to behave like Koskela in "Unknown soldier" of Väinö Linna, or Memed in "My hawk Memed (Ince Memed) of Yashar Kemal. More international heroes have been Cassius Clay (Mohammed Ali) and Aleksandr Solzhenitsyn. It is difficult to be as courageous as they, consequently also Professor Drake's advice to do in your own way has been extremely helpful in building up new Helsinki Neurosurgery.

What next?

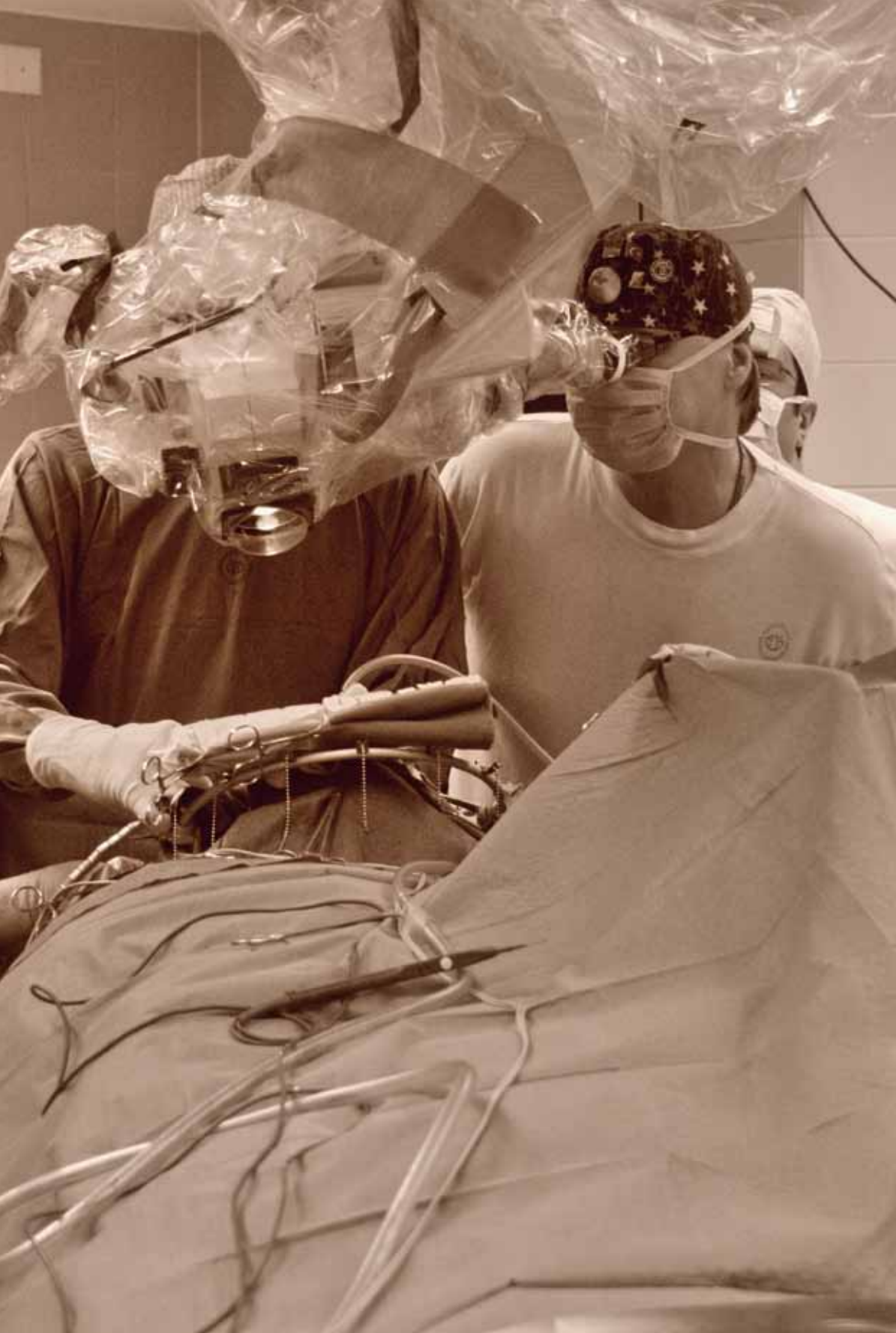Looking back, I say, as every busy neurosurgeon, that I surely should have spent more time with my family. Without their support I could not have managed and become successful. On the other hand I also would have liked to read more books, learn more languages, traveled more, and do more sports. The message is "*carpe diem*", life is short, "*occasio praeceps*". I hope that the good genes for health from my parents continue to allow me to work, and I can spend some 10 years more to develop microsurgical skills further, to develop simpler bypass and most important of all, to support the younger generation to become better than we are. We continue to have open doors in Helsinki, to do open-door microsurgery and we welcome everyone to see and to learn. We learn from each other when we share our cases. In the international melting pot of Helsinki, hopefully better and better surgery will be cooked in the future.




Figure 10-8. Drawing of Juha Hernesniemi in 2010 by Dr. Roberto Crosa from Montevideo, Uruguay.



Figure 10-9. Riitta, Ida, Heta and Jussi Hernesniemi in Kuopio in 1984.



## 11. FUTURE OF NEUROSURGERY

by Juha Hernesniemi

In 1973 when I began my training in Helsinki, our department was taking care of nearly entire Finland, with a catchment area of around 4 million people. There were around 600 operations a year. Ten cervical spine, 50 aneurysm and 100 tumor operations were performed each year, and one chronic subdural hematoma was drained every second week. Patients aged more than 60 years were considered "old" (!), and were operated on only rarely. Over three decades later, in 2007, we operated on 400 cervical spines, more than 300 aneurysms and 600 brain tumors; 256 chronic subdural hematomas were drained. The number of traumatic head injuries operated on in our unit is four times higher than in 1973. The number of all operations in Helsinki is nowadays five-fold compared to the early 70's, and in the whole country (there are nowadays four other neurosurgical units) it is ten-fold. The average hospital stay for a neurosurgical patient is less than five days, and almost 40% of the operations are performed in patients aged 60 or more.

The better results obtainable by microsurgery have been increasingly subjected to critical scrutiny by improved imaging, with the introduction of CT in the late 70's and MRI in the 80's. Control images started to demonstrate that many times the so-called "total removal" was only a partial one, and some part of the tumor or hematoma remained. They also made visible terrible contusions or infarctions caused by surgery, so well hidden in previous times when only angiographic controls were performed. There still remains a lot of room for improvement in our microsurgical methods, and it is certain that imaging is all the time

ahead of our microsurgical technique. Before introduction of the surgical microscope and modern imaging the atmosphere and attitude were different, and neurosurgeon's own word

on total removal remained the only prove, in addition to clips and tantalum powder placed on the resection surface.

Intensive care and neuroanesthesia are now at a completely different level than in the 70's, when intraoperative herniation of the brain out of the craniotomy opening was common, and arterial blood pressure monitoring was a rarity. Nowadays monitoring of intracranial pressure, and even brain tissue blood flow and oxygenation can be routinely implemented.

The biggest challenge in the future is to figure out how to treat most patients using the best treatment modalities at the lowest cost. Health-conscious living habits, proper nutrition and physical exercise, together with the avoidance of smoking, alcohol abuse and drugs prolong life everywhere, at least in rich industrialized countries. Already now it is common to reach 80 years, and close to 100 years is reality in the near future, but only few will live to the biological maximum of 120. With the increasing life expectancy, brain tumors, vascular diseases and degenerative spine disease become more prevalent, and they are also treated at an ever higher age. Imaging with MRI, or some other new imaging modality, will become ever more widely available in patient treatment. Brain tumors will be found in early stages of their growth. Giant tumors growing silently for years will be rare because of early check-ups. Patients coming to the doctor's appointment will have their whole body scanned, and it will become difficult to evaluate and treat all different incidental findings emerging from these screenings. Every patient will have

some or many different findings, and teams of different specialists using databases will assess the clinical significance of these. The magnetic field strengths of MRI scanners will continue to increase, and the tiniest structures will be seen, even the effect and targets of pharmacological therapy will become visible.

Traffic accidents will become extremely rare. In 1973 there were more than 1000 traffic-related fatalities in this small country – nowadays less than 300. In the future, even one death in traffic will lead to big headlines. Different alarm systems, localizers and navigators enable faster transport to treatment facilities, and fewer succumb outside the hospital. Because of improved and widely available imaging very few will die of an undiagnosed slowly developing subdural hematoma; in the future none.

Prevention will be in the future the most common strategy in treating cerebrovascular diseases. Even the smallest vessels can be seen noninvasively, and also the wall thickness and structure. Aneurysms and stenosis/occlusion of the vessels will be treated by angioplasty and/or local biological means.

Neurosurgeons will have an important role in the endovascular treatment, and the knowledge of long-term postoperative care is important. If surgery is needed, it will be done through very small openings with the help of different intraoperative imaging and recordings. Simple bypasses done under local anesthesia are common procedures: arteries and even veins are connected to each other by simple artificial grafts for flow augmentation.

Operations will be practiced before the actual surgery using simulators; in this way surprises during surgery will become rare. Functional imaging shows accurately cortical functions, and

eloquent regions and tracts can be visualized even during surgery. Skull will be opened using short scalp incisions and small cranial flaps, intraoperative imaging will show the operative trajectory and target all the time. Instruments will be carried by micromanipulators and used more securely than what our hands are capable of, while removing the tumors or infarctions, or applying sutures, clips, or glue. Large openings of skull base surgery will disappear, and in general the importance of open surgery will diminish in the treatment of brain tumors. Histology of brain tumors will be confirmed by biopsy, but in most cases diagnosis will be made based on imaging without the need for biopsy. Main part of tumors will be treated by stereotaxic irradiation; removal of the tumor will become necessary only to create space for eventual swelling. Molecular treatments will destroy the tumor, or slow down its growth so that the disease will be under control for the whole life. Epileptic foci will be inactivated or destroyed by irradiation or medication, and similar principles will be applied for functional neurosurgery.

In the neurointensive care units neurologists, neurosurgeons, anesthesiologists and many other specialists together will take part in treating diseases of the brain. One individual's experience and knowledge will no longer be sufficient; only a team of professionals aided by databases will be able to provide the best possible care. The collected international treatment experience is already in databases and available, only money is needed. Hospitals are business-based and, consequently, the highest experience and skills may be expensive. Rehabilitation will be intensive and broadly utilized. Stem cells or others will be used for the repair of brain, spinal cord or nerve injuries. Genetic and molecular causes of spinal diseases will become better understood, and this will lead to better treatment pain, as will also multidisci-

plinary help in individual pain patients. Osteogenetic materials will reduce significantly the present heavy spinal instrumentation and lead to rather minimally invasive spinal surgeries.

Experience makes us more flexible, and luckily the future remains unrevealed to us. Thirty years from now, the present young generation will work completely differently compared to us; better and more efficiently. Our fine present microneurosurgical performances will be spoken of in future tales in the same tone, as the cavalry of our famous ancient army, or the heroic surgical days of Viipuri (Wyborg) County Hospital are spoken of nowadays.





## APPENDIX 1.

### SOME SELECTED ARTICLES ON MICRONEUROSURGICAL AND NEUROANESTHESIOLOGICAL TECHNIQUES FROM HELSINKI

- Celik O, Niemelä M, Romani R, Hernesniemi J. Inappropriate application of Yaşargil aneurysm clips: a new observation and technical remark. *Neurosurgery* 2010; 66 (3 Suppl Operative):84-7.
- Celik O, Piippo A, Romani R, Navratil O, Laakso A, Lehecka M, Dashti R, Niemelä M, Rinne J, Jääskeläinen JE, Hernesniemi J. Management of dural arteriovenous fistulas – Helsinki and Kuopio experience. *Acta Neurochir Suppl* 2010;107:77-82.
- Dashti R, Rinne J, Hernesniemi J, Niemelä M, Kivipelto L, Lehecka M, Karatas A, Avci E, Ishii K, Shen H, Peláez JG, Albayrak BS, Ronkainen A, Koivisto T, Jääskeläinen JE. Microneurosurgical management of proximal middle cerebral artery aneurysms. *Surg Neurol* 2007; 67:6-14.
- Dashti R, Hernesniemi J, Niemelä M, Rinne J, Porras M, Lehecka M, Shen H, Albayrak BS, Lehto H, Koroknay-Pál P, de Oliveira RS, Perra G, Ronkainen A, Koivisto T, Jääskeläinen JE. Microneurosurgical management of middle cerebral artery bifurcation aneurysms. *Surg Neurol* 2007; 67:441-56.
- Dashti R, Hernesniemi J, Niemelä M, Rinne J, Lehecka M, Shen H, Lehto H, Albayrak BS, Ronkainen A, Koivisto T, Jääskeläinen JE. Microneurosurgical management of distal middle cerebral artery aneurysms. *Surg Neurol* 2007; 67:553-63.
- Dashti R, Hernesniemi J, Lehto H, Niemelä M, Lehecka M, Rinne J, Porras M, Ronkainen A, Phornsuwannapha S, Koivisto T, Jääskeläinen JE. Microneurosurgical management of proximal anterior cerebral artery aneurysms. *Surg Neurol* 2007; 68:366-77.
- Dashti R, Laakso A, Niemelä M, Porras M, Hernesniemi J. Microscope-integrated near-infrared indocyanine green videoangiography during surgery of intracranial aneurysms: the Helsinki experience. *Surg Neurol* 2009; 71:543-50.
- Hernesniemi J. Mechanisms to improve treatment standards in neurosurgery, cerebral aneurysm surgery as example. *Acta Neurochir Suppl* 2001; 78:127-34.
- Hernesniemi J, Ishii K, Niemelä M, Smrcka M, Kivipelto L, Fujiki M, Shen H. Lateral supraorbital approach as an alternative to the classical pterional approach. *Acta Neurochir Suppl* 2005; 94:17-21.
- Hernesniemi J, Ishii K, Niemelä M, Kivipelto L, Fujiki M, Shen H. Subtemporal approach to basilar bifurcation aneurysms: advanced technique and clinical experience. *Acta Neurochir Suppl* 2005; 94:31-8.
- Hernesniemi J, Ishii K, Karatas A, Kivipelto L, Niemelä M, Nagy L, Shen H. Surgical technique to retract the tentorial edge during subtemporal approach: technical note. *Neu-*

## APPENDIX 1.

### SOME SELECTED ARTICLES ON MICRONEUROSURGICAL AND NEUROANESTHESIOLOGICAL TECHNIQUES FROM HELSINKI

- rosurgery 2005; 57(4 Suppl):E408. 83.
- Hernesniemi J, Niemelä M, Karatas A, Kivipelto L, Ishii K, Rinne J, Ronkainen A, Koivisto T, Kivisaari R, Shen H, Lehecka M, Frösen J, Piippo A, Jääskeläinen JE. Some collected principles of microneurosurgery: simple and fast, while preserving normal anatomy: a review. *Surg Neurol* 2005 Sep; 64:195-200.
  - Hernesniemi J, Niemelä M, Dashti R, Karatas A, Kivipelto L, Ishii K, Rinne J, Ronkainen A, Peláez JG, Koivisto T, Kivisaari R, Shen H, Lehecka M, Frösen J, Piippo A, Avci E, Jääskeläinen JE. Principles of microneurosurgery for safe and fast surgery. *Surg Technol Int* 2006; 15:305-10.
  - Hernesniemi J, Romani R, Dashti R, Albayrak BS, Savolainen S, Ramsey C 3rd, Karatas A, Lehto H, Navratil O, Niemelä M. Microsurgical treatment of third ventricular colloid cysts by interhemispheric far lateral transcallosal approach—experience of 134 patients. *Surg Neurol* 2008; 69:447-53.
  - Hernesniemi J, Dashti R, Lehecka M, Niemelä M, Rinne J, Lehto H, Ronkainen A, Koivisto T, Jääskeläinen JE. Microneurosurgical management of anterior communicating artery aneurysms. *Surg Neurol* 2008; 70:8-28.
  - Hernesniemi J, Romani R, Albayrak BS, Lehto H, Dashti R, Ramsey C 3rd, Karatas A, Cardia A, Navratil O, Piippo A, Fujiki M, Toninelli S, Niemelä M. Microsurgical management of pineal region lesions: personal experience with 119 patients. *Surg Neurol* 2008; 70:576-83.
  - Hernesniemi J, Romani R, Lehecka M, Isarakul P, Dashti R, Celik O, Navratil O, Niemelä M, Laakso A. Present state of microneurosurgery of cerebral arteriovenous malformations. *Acta Neurochir Suppl* 2010; 107:71-6.
  - Kivelev J, Niemelä M, Blomstedt G, Roivainen R, Lehecka M, Hernesniemi J. Microsurgical treatment of temporal lobe cavernomas. *Acta Neurochir* 2011; 153:261-70.
  - Korja M, Sen C, Langer D. Operative nuances of side-to-side in situ posterior inferior cerebellar artery bypass procedure. *Neurosurgery* 2010; 67(2 Suppl Operative):471-7.
  - Krayenbühl N, Hafez A, Hernesniemi JA, Krisht AF. Taming the cavernous sinus: technique of hemostasis using fibrin glue. *Neurosurgery* 2007; 61(3 Suppl):E52.
  - Langer DJ, Van Der Zwan A, Vajkoczy P, Kivipelto L, Van Doormaal TP, Tulleken CA. Excimer laser-assisted nonocclusive anastomosis. An emerging technology for use in the creation of intracranial-intracranial and extracranial-intracranial cerebral bypass. *Neurosurg Focus* 2008; 24:E6.
  - Lehecka M, Lehto H, Niemelä M, Juvela S, Dashti R, Koivisto T, Ronkainen A, Rinne J, Jääskeläinen JE, Hernesniemi JA. Distal anterior cerebral artery aneurysms: treatment and outcome analysis of 501 patients. *Neurosurgery* 2008; 62:590-601.

aneurysms. *World Neurosurgery* 2010; 73:486-99.

- Lehecka M, Dashti R, Hernesniemi J, Niemelä M, Koivisto T, Ronkainen A, Rinne J, Jääskeläinen J. Microneurosurgical management of aneurysms at A3 segment of anterior cerebral artery. *Surg Neurol* 2008; 70:135-51.
- Lehecka M, Dashti R, Hernesniemi J, Niemelä M, Koivisto T, Ronkainen A, Rinne J, Jääskeläinen J. Microneurosurgical management of aneurysms at the A2 segment of anterior cerebral artery (proximal pericallosal artery) and its frontobasal branches. *Surg Neurol* 2008; 70:232-46.
- Lehecka M, Dashti R, Hernesniemi J, Niemelä M, Koivisto T, Ronkainen A, Rinne J, Jääskeläinen J. Microneurosurgical management of aneurysms at A4 and A5 segments and distal cortical branches of anterior cerebral artery. *Surg Neurol* 2008; 70:352-67.
- Lehecka M, Dashti R, Romani R, Celik O, Navratil O, Kivipelto L, Kivisaari R, Shen H, Ishii K, Karatas A, Lehto H, Kokuzawa J, Niemelä M, Rinne J, Ronkainen A, Koivisto T, Jääskeläinen JE, Hernesniemi J. Microneurosurgical management of internal carotid artery bifurcation aneurysms. *Surg Neurol* 2009; 71:649-67.
- Lehecka M, Dashti R, Laakso A, van Popta JS, Romani R, Navratil O, Kivipelto L, Kivisaari R, Foroughi M, Kokuzawa J, Lehto H, Niemelä M, Rinne J, Ronkainen A, Koivisto T, Jääskeläinen JE, Hernesniemi J. Microneurosurgical management of anterior choroid artery aneurysms. *World Neurosurgery* 2010; 73:486-99.
- Lehecka M, Dashti R, Rinne J, Romani R, Kivisaari R, Niemelä M, Hernesniemi J. Surgical management of aneurysms of the middle cerebral artery. In Schmiedek and Sweet's (eds.) *Operative neurosurgical techniques*, 6th ed. Elsevier, in press.
- Lehecka M, Niemelä M, Hernesniemi J. Distal anterior cerebral artery aneurysms. In R, McCormick P, Black P (eds.) *Essential Techniques in Operative Neurosurgery*. Elsevier, in press.
- Lehto H, Dashti R, Karataş A, Niemelä M, Hernesniemi JA. Third ventriculostomy through the fenestrated lamina terminalis during microneurosurgical clipping of intracranial aneurysms: an alternative to conventional ventriculostomy. *Neurosurgery* 2009; 64:430-4.
- Lindroos AC, Niiya T, Randell T, Romani R, Hernesniemi J, Niemi T. Sitting position for removal of pineal region lesions: the Helsinki experience. *World Neurosurg*. 2010 Oct-Nov;74(4-5):505-13.
- Lindroos AC, Schramko A, Tanskanen P, Niemi T. Effect of the combination of mannitol and ringer acetate or hydroxyethyl starch on whole blood coagulation in vitro. *J Neurosurg Anesthesiol*. 2010 Jan;22(1):16-20.
- Luostarinen T, Dilmen OK, Niiya T, Niemi T. Effect of arterial blood pressure on the arterial to end-tidal carbon dioxide difference during anesthesia induction in patients

## APPENDIX 1.

### SOME SELECTED ARTICLES ON MICRONEUROSURGICAL AND NEUROANESTHESIOLOGICAL TECHNIQUES FROM HELSINKI

- scheduled for craniotomy. *J Neurosurg Anesthesiol.* 2010 Oct;22(4):303-8.
- Luostarinen T, Niiya T, Schramko A, Rosenberg P, Niemi T. Comparison of hypertonic saline and mannitol on whole blood coagulation in vitro assessed by thromboelastometry. *Neurocrit Care.* 2011 Apr;14(2):238-43.
  - Luostarinen T, Takala RS, Niemi TT, Katila AJ, Niemelä M, Hernesniemi J, Randell T. Adenosine-induced cardiac arrest during intraoperative cerebral aneurysm rupture. *World Neurosurgery* 2010; 73:79-83.
  - Nagy L, Ishii K, Karatas A, Shen H, Vajda J, Niemelä M, Jääskeläinen J, Hernesniemi J, Toth S. Water dissection technique of Toth for opening neurosurgical cleavage planes. *Surg Neurol* 2006; 65:38-41.
  - Navratil O, Lehecka M, Lehto H, Dashti R, Kivisaari R, Niemelä M, Hernesniemi JA. Vascular clamp-assisted clipping of thick-walled giant aneurysms. *Neurosurgery* 2009; 64 (3 Suppl):113-20.
  - Niemi T, Armstrong E. Thromboprophylactic management in the neurosurgical patient with high risk for both thrombosis and intracranial bleeding. *Curr Opin Anaesthesiol.* 2010 Oct;23(5):558-63. Review.
  - Niemi T, Silvasti-Lundell M, Armstrong E, Hernesniemi J. The Janus face of thromboprophylaxis in patients with high risk for both thrombosis and bleeding during intracranial surgery: report of five exemplary cases. *Acta Neurochir (Wien).* 2009 Oct;151(10):1289-94.
  - Randell T, Niemelä M, Kytä J, Tanskanen P, Määttä M, Karatas A, Ishii K, Dashti R, Shen H, Hernesniemi J. Principles of neuroanesthesia in aneurysmal subarachnoid hemorrhage: The Helsinki experience. *Surg Neurol* 2006; 66:382-8.
  - Romani R, Lehecka M, Gaal E, Toninelli S, Celik O, Niemelä M, Porras M, Jääskeläinen J, Hernesniemi J. Lateral supraorbital approach applied to olfactory groove meningiomas: experience with 66 consecutive patients. *Neurosurgery* 2009; 65:39-52.
  - Romani R, Kivisaari R, Celik O, Niemelä M, Perra G, Hernesniemi J. Repair of an alarming intraoperative intracavernous carotid artery tear with anastoclips: technical case report. *Neurosurgery* 2009; 65:E998-9.
  - Romani R, Laakso A, Niemelä M, Lehecka M, Dashti R, Isarakul P, Celik O, Navratil O, Lehto H, Kivisaari R, Hernesniemi J. Microsurgical principles for anterior circulation aneurysms. *Acta Neurochir Suppl* 2010; 107:3-7.
  - Romani R, Lehto H, Laakso A, Horcajadas A, Kivisaari R, von und zu Fraunberg M, Niemelä M, Rinne J, Hernesniemi J. Microsurgery for previously coiled aneurysms: Experience with 81 patients. *Neurosurgery* 2010; 68:140-54.
  - Romani R, Laakso A, Kangasniemi M, Lehecka M, Hernesniemi J. Lateral supraorbital



## APPENDIX 2.

### LIST OF ACCOMPANYING VIDEOS

approach applied to anterior clinoidal meningiomas: experience with 73 consecutive patients. Neurosurgery 2011 Feb 26 (Epub, in press).

The following 32 videos are included on the supplementary DVD "Helsinki Microneurosurgery: Basics and Tricks".

The videos were recorded during microneurosurgical operations by Professor Juha Hernesniemi from January 2009 to January 2011 at the Department of Neurosurgery, Helsinki University Central Hospital, Helsinki, Finland. Professor Hernesniemi has performed during this time a total of 810 operations (355 patients with cerebral aneurysms, 50 with cerebral AVMs, 28 other cerebrovascular surgeries, 270 with brain tumors, and 107 with other pathologies).

#### Approaches

- 1.1. Lateral supraorbital (LSO) approach (with audio)
- 1.2. Lateral supraorbital (LSO) approach (aneurysmal SAH)
- 1.3. Approach to the lamina terminalis (aneurysmal SAH)
2. Pterional approach
3. Interhemispheric approach
4. Subtemporal approach
5. Retrosigmoid approach
6. Lateral approach to foramen magnum
7. Presigmoid approach
8. Supracerebellar infratentorial approach - sitting position
9. Approach to the fourth ventricle and foramen magnum region - sitting position

- meningioma
- Skull base - Suprasellar meningioma

## Techniques and strategies for different pathologies

1. Aneurysms
  - 1.1. Anterior circulation
    - ACoA aneurysm
    - Distal ACA aneurysm
    - ICA-PCoA aneurysm
    - MCA bifurcation aneurysm
  - 1.2. Posterior circulation
    - BA bifurcation aneurysm
    - BA-SCA aneurysm
    - VA-PICA aneurysm

(All are unruptured small aneurysms, unless indicated otherwise)
2. AVM's
  - Frontal-parasagittal AVM
  - Parietal AVM
3. Cavernomas
  - Cerebellar cavernoma
4. Meningiomas
  - Anterior fossa - Olfactory groove meningioma
  - Convexity meningioma
  - Falx meningioma
  - Posterior fossa - Lateral petrosal
5. Gliomas
  - High-grade glioma
  - Low-grade glioma
6. Tumors of the third ventricle
  - Colloid cyst of the third ventricle
7. Pineal region lesions
  - Pineal cyst
8. Tumors of the fourth ventricle
  - Medulloblastoma of the fourth ventricle
9. Spinal intradural tumors
  - Neurinoma L1-2



## The Helsinki Live Demonstration Course in Operative Microneurosurgery

Every year the first week in June

### Horizons of Knowledge

Competence to master the future.



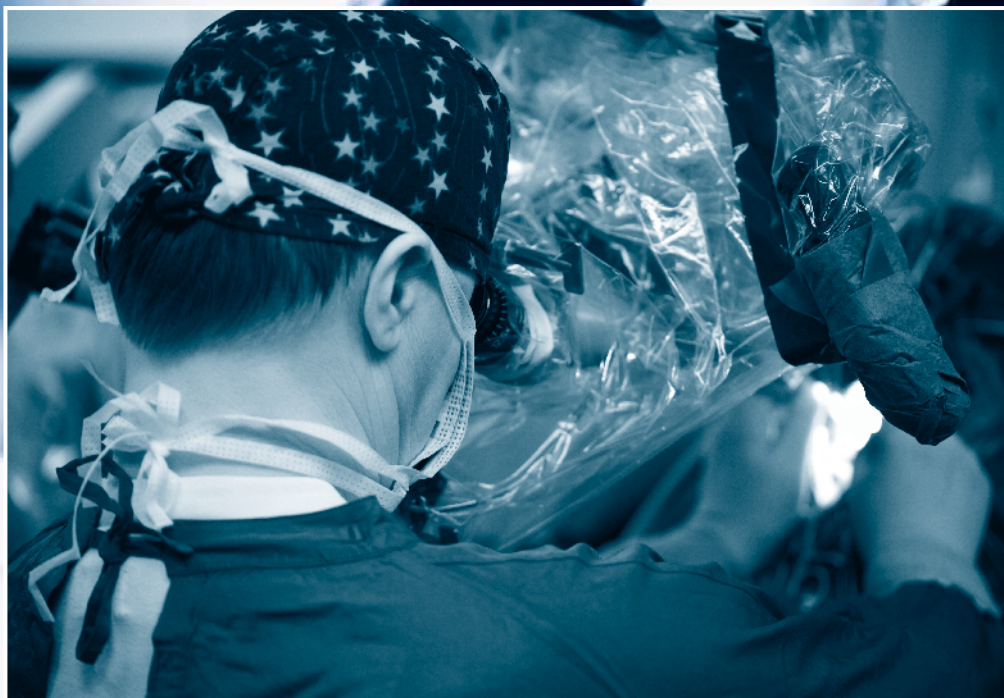The Aesculap Academy enjoys a world-wide reputation for medical training of physicians, senior nursing staff and staff in OR, anesthesia, ward and hospital management. The CME accredited courses consist of hands-on workshop, management seminars and international symposia. For that the Aesculap Academy was given the Frost & Sullivan award as 'Global Medical Professional Education Institution of the Year' three time in succession.

The Aesculap Academy courses are of premium quality and accredited by the respective medical societies and international medical associations.

[www.aesculap-academy.fi](http://www.aesculap-academy.fi)







Department of Neurosurgery at Helsinki University, Finland, led by its chairman Juha Hernesniemi, has become one of the most frequently visited neurosurgical units in the world. Every year hundreds of neurosurgeons come to Helsinki to observe and learn microneurosurgery from Professor Juha Hernesniemi and his team.

In this book we want to share the Helsinki experience on conceptual thinking behind what we consider modern microneurosurgery. We want to present an up-to-date manual of basic microneurosurgical principles and techniques in a cook book fashion. It is our experience that usually the small details determine whether a particular surgery is going to be successful or not. To operate in a simple, clean, and fast way while preserving normal anatomy has become our principle in Helsinki.